

A Genetic Study of
Primary Angle-Closure Glaucoma
and Nanophthalmos

Dr Mona S Awadalla, MBBS

This thesis is submitted for the degree of Doctor of Philosophy

Department of Ophthalmology

Faculty of Health Sciences, Flinders University

Adelaide, South Australia

January 2013

SUMMARY

Glaucoma is a term describing a group of ocular disorders with multi-factorial etiology united by a clinically characteristic intraocular pressure-associated optic neuropathy. Collectively, they are the leading cause of irreversible blindness worldwide. Primary angle-closure glaucoma (PACG) is a subtype of glaucoma characterised by irido-trabecular contact and elevated intraocular pressure (IOP). Almost half of individuals who reach legal blindness due to glaucoma have PACG. PACG may be clinically divided into acute and chronic forms, and the pathogenesis is multifactorial. Short axial length and a “crowded” anterior segment are established risk factors in the development of PACG. Similar but more extreme clinical findings are found in a rare developmental disorder known as nanophthalmos. Recent studies have highlighted the heritable component of both nanophthalmos and PACG. The aim of this thesis was to further explore genetic risk factors in the development of nanophthalmos and PACG.

This study identified a novel variant c.577G>C located in exon 8 of *Transmembrane protein 98 (TMEM98)* gene in a large family with autosomal dominant nanophthalmos, and reports variants of *Membrane frizzled-related protein* and *Protease serine 56* in two other families with nanophthalmos. These three genes were further analysed for association with PACG and borderline significance was identified, motivating further study on a larger cohort.

We then conducted a genome-wide association study (GWAS), which is an approach

that involves scanning the whole genomes of many people to find genetic variations associated with a particular disease, on patients with PACG from two different cohorts available at the time of the study (Australia and Nepal). We chose different cohorts to investigate the differences in the allele frequencies and the genetic risks between these two cohorts. Unfortunately no significant single nucleotide polymorphisms (SNPs) reaching genome-wide significance were detected from this GWA study, so we aimed to build up the PACG cohort for the next larger GWAS.

Meanwhile, analyses of previously published candidate gene studies for PACG were undertaken. This study shows that common variation within *Matrix metalloproteinase-9*, and *Endothelial nitric oxide synthase* genes were significantly associated with PACG in the Australian cohort, while the *Hepatocyte growth factor* gene was associated with the disease in the Nepalese cohort. Finally, replication of three novel loci rs11024102 in *PLEKHA7* (*Pleckstrin homology domain containing, family A member 7*), rs3753841 in *COL11A1* (*Collagen, type XI, alpha 1*), and rs1015213 located between *PCMTD1* (*Protein-L-isoaspartate (D-aspartate) O-methyltransferase domain containing 1*) and *ST18* (*Suppression of tumorigenicity 18*) from a recent GWAS indicates replicated association of these candidate loci with PACG.

Data from this thesis advance understanding of the genes involved in the pathogenesis of nanophthalmos and PACG. It may assist in refining of the genetic screening programs to identify individuals at particularly high risk, especially in families with nanophthalmos, as they develop blindness at a younger age.

Identification of *TMEM98* as a gene for autosomal dominant nanophthalmos is also a finding of significance, which requires further functional work to unveil the role of this gene in the human eye.

ACKNOWLEDGEMENTS

This thesis is dedicated to my amazing family. My father Prof Salaheldin Awadalla has been my inspiration since I was a little girl, I always dreamt to be like him. My appreciation goes to my beautiful mother for her endless encouragement and support. Together they taught me how to challenge life and to get the best out of it. Their emotional and financial support has enabled me to comfortably fulfil my passion for research. I thank my brothers Mohamed and Maged for being so supportive and for always being there for me in my ups and downs. They have provided utmost emotional encouragement and support for the last three years and also shared the joys of outcomes and successes of this project. To my fiancée Moataz, thank you for enlightening my life with your love, smile and kind heart.

Working on my PhD in the Department of Ophthalmology has been an overwhelming and rewarding experience. I have had the greatest honour to work under the supervision of Associate Professor Jamie Craig and Dr Kathryn Burdon. I strongly believe that anyone who has the chance to work with them is extremely lucky. To Jamie, you have been a steady influence throughout my PhD candidature with your support, care and encouragement in times of new ideas and difficulties. Thank you for being a person open to ideas, and for helping me to shape my research interests. To Kathryn, I cannot thank you enough for your tremendous support and always finding time for me. The outcome of the project in this timeframe would not be possible without you. Furthermore, I am grateful to my co-supervisors Professor Robert Casson and Professor David Mackey for their insightful comments in this thesis, and for their many motivating discussions.

Professor Douglas Coster is sincerely thanked for believing in my ambition when I first came to Flinders Eye Clinic as an ophthalmologist trainee in 2005, he encouraged me to always

aim for the top. I am really grateful for his incredible generosity and support and for being my honorary father in Australia.

I thank all participants who contributed in this project. I am grateful to the ophthalmologists who assisted with recruitment of participants; Prof Robert Casson, Dr Mark Walland, Dr Guy D'Mellow, Dr Richard Mills, Dr Stewart Lake, Dr Michael Coote, Dr Deepa Taranath, Dr John Landers, Dr Erica Mancel, and Dr Anna Galanopoulos. Assistance for the recruitment of participants by Dr Suman Thapa from the Nepal eye clinic and Dr Alex Hewitt for recruiting the Normal South Australian cohort is highly appreciated.

The Department of Ophthalmology Centre for Clinical Research Excellence of Flinders Medical Centre, the FMC Foundation, the National Health and Medical Research Council (NH&MRC), Flinders University and the Ophthalmic Research Institute of Australia are acknowledged for their funding support.

I would love to thank Ms Emmanuelle Souzeau for her effort as a genetic counsellor and together with Ms Bronwyn Ridge for their effort in assisting with the recruitment of patients and data collection. The assistance I have received from the Ophthalmology laboratory group is appreciated: Mr Abraham Kuot, Ms Sarah Martin, Ms Alpana Dave, Ms Greta David, Mrs Kathleen Dowell, Mr Rhys Fogarty, Ms Shari Javadiyan and Ms Kate Laurie. I also acknowledge Dr Stuart MacGregor at the Queensland Institute of Medical Research for conducting and analysing the genome-wide pooling data in chapter 3. As the thesis is the end result of team work, so the plural personal pronoun “we” was used instead of the singular form. One sure thing is the rewarding experience I have received working in the Department of Ophthalmology, Flinders Medical Centre from everyone, particularly Dr Georgia

Kaidonis, Dr Jude Fitzgerald, Dr David Dimasi, Dr Shiwani Sharma, Ms Deb Sullivan, Dr Miriam Keane, Mrs Lynda Saunders, Ms Anne Cazneaux, Ms Lyn Harding and Prof Keryn Williams.

INTRODUCTION

Glaucoma

The term glaucoma was first used by the ancient Greeks to describe a form of ocular pathology that may, in fact, have been a cataract. A clear difference between cataract and glaucoma was not described until 1705. At the beginning of the 19th century a French physician (Dr A. Demours) showed that an increase in intraocular pressure (IOP) can lead to glaucoma. In 1973, Drance was the first to describe glaucoma as an optic neuropathy influenced by several risk factors. (Mantzioros 2006)

In modern nomenclature, Glaucoma is a term describing a group of ocular disorders with multi-factorial aetiology united by a clinically characteristic intraocular pressure-associated optic neuropathy. (Casson, Chidlow et al. 2012) It is not a single entity and is sometimes referred to in the plural as “the glaucomas”. All forms are potentially progressive and can lead to blindness. The different subtypes of glaucoma each vary in their pathophysiology and clinical presentation; (Morrison and Pollack 2003; Knaski 2008) however, an elevated IOP is present at some stage of the disease process in all forms of glaucoma except so-called, normal tension glaucoma.

Loss of vision from glaucoma is preventable but irreversible. In Australia, the cost of managing glaucoma exceeds AUS\$50 million per year with the cost of glaucoma-related prescriptions alone increasing from \$19 million per year in 1994 to \$71 million per year in 2003. (Walland 2004)

Classification of Glaucomas

Glaucomas are classified by the anatomy and appearance of the irido-corneal angle, located at the junction between the iris and cornea in the anterior chamber, into two main groups: open-angle glaucoma, and angle-closure glaucoma.

Primary open-angle glaucoma (POAG) is the most common form of glaucoma worldwide. POAG shows normal structure of the anterior chamber of the eye with normal anterior chamber depth (ACD), and a wide open irido-corneal angle (**Figure 1.1.a**). (Yong, John et al. 2009) Primary angle-closure glaucoma is caused by anatomical narrowing of the anterior chamber angle, and is characterized by irido-trabecular contact, an elevated IOP and glaucomatous optic neuropathy (GON) (**Figure 1.1.b**).

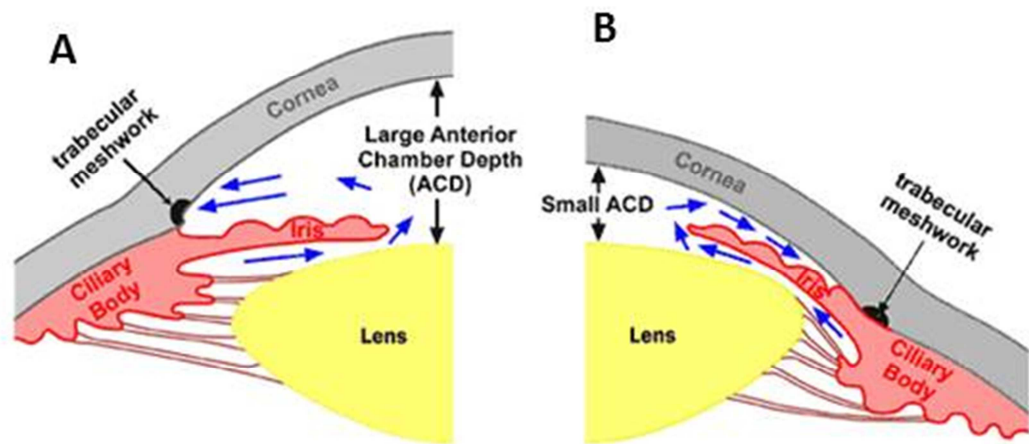


Figure 1.1. Structure of the anterior chamber of the eye. POAG (A) the drainage angle formed between the cornea and the iris is wide open $\sim 40^\circ$. The anterior chamber depth is large. PACG (B) the iris and trabecular meshwork in contact (irido-trabecular contact) blocking the flow of aqueous. Note the anterior chamber depth is shallow. (Adapted from <http://www.medrounds.org>)

Primary Angle-Closure Glaucoma

PACG has been classified into three categories following the International Society of Geographical and Epidemiological Ophthalmology (ISGEO) classification as described by Foster and colleagues; (Foster, Buhrmann et al. 2002)

- Primary angle-closure suspect (PACS) has an “occludable” angle on gonioscopy with IOP less than or equal to 21 mmHg and no glaucomatous damage.
- Primary angle-closure (PAC) is defined by the presence of peripheral anterior synechiae (adhesion of the iris to the cornea), or elevated IOP greater than 21 mmHg without evidence of optic disc damage.
- Primary angle-closure glaucoma (PACG) is the presence of glaucomatous optic neuropathy with irido-trabecular contact.

PACG is further subdivided into acute, subacute and chronic clinical forms. The acute type is characterized by a sudden severe elevation of IOP with corneal oedema and associated severe ocular pain. There may be an ischaemic component to the optic neuropathy and this subtype is visually devastating without emergency reduction of the IOP.

The subacute form is characterized by peripheral anterior synechiae and a history of periodic unilateral headache, blurred vision and coloured halos, and may resolve without treatment. (Sihota and Agarwal 1998)

Chronic PACG is usually asymptomatic and its diagnosis relies on gonioscopy,

which makes it more likely to go undetected. (Quigley, Congdon et al. 2001) It is characterized by a chronically elevated IOP with irido-trabecular contact and the presence of glaucoma optic neuropathy. (Foster, Buhrmann et al. 2002)

The pathogenesis of PACG is complicated and involves anatomical, physiological and/or environmental factors. Whether a particular anatomically predisposed eye will develop PACG is quite unpredictable. (Hung and Chou 1979) Wang et al, showed that only 10% of individuals with narrow-angles developed PACG. (Wang, Wu et al. 2002) Different studies have divided PACG into three categories according to the mechanism of action; (Ningli, Wenbin et al. 1997; Wang, Wu et al. 2002; Huang and Barocas 2004)

1. Pupillary block: The term pupillary block has been used to define any of the various mechanisms which interfere with the forward flow of aqueous humor through the pupil. (Shaffer 1973) It is the most frequent and clinically treatable type, is usually associated with increased lens curvature, short zonule-iris distance and formation of iris bombe. It is associated with acute and sub-acute attacks. Permanent resolution may be achieved by iridectomy or laser iridotomy.
2. Non-pupillary blocking: may be associated with a classic plateau iris configuration or may occur without characteristic plateau features. In plateau iris, the iris root is angulated forward and centrally by anterior located ciliary processes. The iris appears flat by gonioscopy, and the central anterior chamber is not shallow. Plateau iris is found in up to 30% of PACG patients who had laser iridotomy. (Kumar, Tantisevi et al. 2009)
3. Multi-mechanism: Several factors are involved such as pupillary block,

crowding of the anterior chamber, especially in the presence of an enlarging lens due to cataract, and an anatomically anteriorly positioned iris.

Incidence of primary angle-closure glaucoma

Glaucoma is the leading cause of irreversible blindness worldwide and it is estimated that 80 million people will be affected by 2020. (Quigley and Broman 2006) Blindness is reported to be 25% more likely in people with PACG than POAG worldwide. (Foster and Johnson 2001) PACG is reported to be the cause of blindness for about half of blind glaucoma patients, and it has high visual morbidity rates, particularly in Asian individuals. The number of patients with PACG is expected to rise by approximately 5 million people, from 16 million over the next decade. (Casson 2008)

PACG has been shown to be the most common cause of bilateral blindness in Singapore, China and India. (Quigley, Congdon et al. 2001) In contrast, Caucasian populations have an overall prevalence of approximately 0.4%. (Day, Baio et al. 2012) The prevalence of acute PACG in Caucasians living in Israel was noted to be higher than other Caucasian populations, indicating that environmental factors may be involved. (Ivanisevic, Erceg et al. 2002)

Risk factors

PACG has anatomical risk factors: short axial length, small corneal diameter, thick anteriorly positioned crystalline lens, and hyperopic refractive error. (Salmon 1999)

A shallow anterior chamber depth (ACD) is the most important risk factor, because it is consistently present, and is a heritable trait. (Alsbirk 1976; Alsbirk 1992; Aung, Nolan et al. 2005) It shows an association with older age, gender (more shallow in females) and race (more common in Eskimos and Asians). (Salmon 1999) The parents of affected individuals will often be deceased, whilst children will be too young to manifest disease.

Casson has suggested that the reason for the shallow anterior chamber found in certain people of Asian extraction is that this trait originated in *H. sapiens* in north-east Asia as an anatomical adaptation to resist corneal freezing and that their descendants possess the trait. (Casson 2008)

Aging plays a role in the disease development as the crystalline lens gets thicker and displaces the iris forward leading to apposition of the trabecular meshwork, relative pupil block and development of peripheral anterior synechiae as found in chronic angle-closure glaucoma. (Bonomi, Marchini et al. 2000)

Glaucoma in Nanophthalmos

Nanophthalmos (interchangeably referred to as simple microphthalmia) and posterior microphthalmia (PM) are two rare subtypes of microphthalmia. Microphthalmia is a developmental eye disorder of bilaterally small eyes, and is characterised by the axial length of the globe being more than 2 standard deviations smaller than the normal range (< 20 mm in adults). (Vingolo, Steindl et al. 1994) The cornea and lens are typically of normal size, (Sundin, Dharmaraj et al. 2008) causing high lens to eye volume ratio and severe hyperopia (farsightedness) of +7.00 dioptres

or more. (Othman, Sullivan et al. 1998) In patients with nanophthalmos, the decrease in the anterior chamber's dimensions cause the iridocorneal angle to be typically narrow, and abnormal thickening of the scleral connective tissue is often observed. (**Figure 1.2**) (Sundin, Leppert et al. 2005; Sundin, Dharmaraj et al. 2008) The abnormal structure of the anterior chamber observed in nanophthalmos differs from posterior microphthalmia where the anterior chamber is of normal dimensions (Spitznas, Gerke et al. 1983; Khairallah, Messaoud et al. 2002; Khan 2006) and patients with posterior microphthalmia do not tend to develop angle-closure glaucoma. (Khairallah, Messaoud et al. 2002) Recently, a study has revealed that eyes with posterior microphthalmia have corneal steepening proportional to the degree of the short axial length, suggesting that both nanophthalmos and posterior microphthalmia are not a distinct phenotype but they represent a spectrum of high hyperopia. (Nowilaty, Khan et al. 2013)

The worldwide prevalence of all microphthalmias is approximately 1-5 per 10,000 births. (Eurocat work group 2010; International Clearing House for Birth Defects Surveillance and Research 2010)

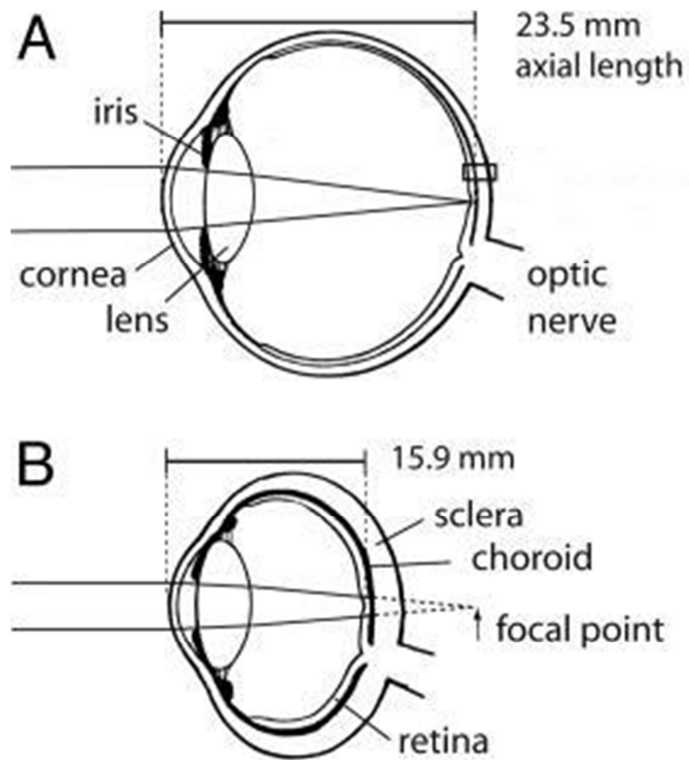


Figure 1.2. Morphological features of nanophthalmos. A diagram of the eye in sagittal section, showing the difference between (A) Normal eye, and (B) eye with Nanophthalmos. (Sundin, Leppert et al. 2005)

The aetiologies of different types of microphthalmia are varied and includes teratogens, foetal alcohol syndrome and intra-uterine infection (Kallen, Robert et al. 1996) but most cases are considered to be due to genetic defects. (Verma and Fitzpatrick 2007) Nanophthalmos is often reported in conjunction with other systemic abnormalities including cardiac defects and facial clefts. (Kallen, Robert et al. 1996)

Secondary complications from microphthalmia result from the small eye being required to accommodate a normal sized retina, causing loss of the foveal pit from slippage between the retina and retinal pigment epithelium (RPE) and the formation

of macular folds. (Sundin, Leppert et al. 2005) Retinal detachment can also occur due to the accumulation of fluid between the RPE and retina, driven by the thickened sclera, which reduces the flow through choroidal vessels. (Sundin, Leppert et al. 2005)

Development of angle-closure glaucoma in patients with nanophthalmos most commonly results from the forward displacement of the iris towards the cornea, with obstruction of the irido-corneal angle and formation of peripheral anterior synechiae (PAS). (Singh, Simmons et al. 1982)

Investigation of Angle-Closure Glaucoma

With more than 50% of patients with PACG undiagnosed, the rate of detecting early asymptomatic cases should be increased through encouraging family members of an affected individual to be screened and examined, as PACG tends to run in families. (Green, Kearns et al. 2007) Public health education, screening and early diagnosis are important ways to avoid permanent blindness. (Flanagan 1998) This will help to monitor the disease progression, to initiate timely treatment and postpone the complications.

First-degree relatives of PACG cases should be screened from the age of 40 years. If the initial assessment is normal, it has been recommended that 2-year interval reviews should be done until the age of 50 years then annual review thereafter. (Kanski 2007)

To diagnose a patient with angle-closure glaucoma, we should assess;

Visual field. Humphery perimetry is used for assessment of visual field. Early

changes of glaucomatous damage show asymmetrical defects between both eyes which develop to nasal scotoma, paracentral scotoma, arcuate scotoma, ring scotoma and finally by adherence of all scotomas leaving small islands of central and temporal vision. (Kanski 2007)

Comparing the visual fields between PACG and POAG, the damage is more diffuse in the angle closure type while there is no difference in the structural damage uniformity in both types when measured by OCT NFL thickness. (Boland, Zhang et al. 2008)

Anterior chamber angle.

- Gonioscopy is an important diagnostic tool to pick up early changes in the anterior chamber (AC) of PACG and should be considered as a routine part of the eye examination (Vijaya, George et al. 2008). It may be either diagnostic for any abnormalities in the angle and estimation of its width, or therapeutic by visualisation of the angle during laser trabeculoplasty or goniotomy procedure (Kanski 2007).
- Ultrasound BioMicroscopy (UBM) is a high frequency B scan to assess the configuration of the angle and analyse the mechanism of angle closure dynamically. (Pavlin, Easterbrook et al. 1993) It is helpful in extreme narrow angles, where it is so difficult to clarify the iris insertion position by gonioscopy even with indentation, also preferred in dark room provocative testing. (Elaine K. Woo, Pavlin et al. 1999)

Intraocular pressure. Intraocular pressure is measured using a Goldmann applanation tonometer. It measures the pressure by the amount of force applied to flatten the cornea. If the patient is bed ridden or anaesthetized we can use Perkin

applanation tonometer, a hand-held tonometer.

Optic disc changes. Disc changes are assessed by optical coherence tomography (OCT) showing multiple cross sections of the retina using high-resolution quality. (Kanski 2007)

Management of Primary Angle-Closure Glaucoma

The main goal for treatment is to prevent further damage to the optic nerve head thus saving vision. To date, the only method used to achieve this target is to maintain the IOP within the normal range. It is essential to monitor the progress of the disease by baseline evaluation, and the follow-up visits.

Laser Peripheral Iridotomy

Laser peripheral iridotomy is the cornerstone of managing PACG due to pupil block, and, if treatment is indicated, is generally recommended in all forms of angle-closure to eliminate any element of pupil block. Laser peripheral iridotomy allows aqueous to flow directly from the posterior to the anterior chamber circumventing the pupil block to aqueous flow, and allowing the peripheral iris to move away from the trabecular meshwork. However, this approach will not be effective in the presence of peripheral anterior synechiae, or non-pupil block mechanisms, or in the presence of a very large lens due to cataract.

Medication

Ocular hypotensive therapy is routinely used in concert with laser peripheral iridotomy to achieve reduction of IOP when it remains high despite laser peripheral iridotomy. Medications such as prostaglandin analogues, carbonic anhydrase inhibitors, α - agonists and β - antagonists, have been shown to prevent the progressive

damage of the optic disc and visual field loss in cases with chronic PACG by lowering the IOP. (Sharmini, Yin et al. 2009)

Laser Peripheral iridoplasty

Laser peripheral iridoplasty acts by pulling the iris root away from the angle through immediate focal iris stromal contraction leading to widening of the irido-corneal angle. It can be used alone, or combined with medical treatments in managing acute PACG. Both strategies have a similar result of lowering the IOP by greater than 75% within an hour after the iridoplasty in cases of acute PACG. (Lam, Lai et al. 1998; Tham, Lai et al. 1999)

Trabeculectomy

If the IOP cannot be controlled medically or following laser treatment then trabeculectomy is an effective method to control IOP in both acute and chronic PACG. Unfortunately the failure rate of the surgery in PACG is higher than that of POAG. (Aung, Tow et al. 2000) The eyes should be monitored frequently afterwards to ensure that the IOP remains within normal range. (Tarongoy, Ho et al. 2009)

Phacoemulsification

Removal of the lens, either as a clear lens extraction or cataract extraction will relieve appositional iridotrabecular contact and is a possible surgical option. The prevalence of PACG decreases with an increase in the rate of cataract surgery. The surgery widens the anterior chamber and irido-corneal angle as the artificial intraocular lens inserted is much narrower than the natural crystalline lens, thus reducing the incidence of acute attack of PACG. (Keenan, Salmon et al. 2009)

Genetics considerations in angle-closure glaucoma

At the beginning of this study, the genetic contribution to PACG was largely unknown. Pathogenesis of PACG has a multi-factorial inheritance (Lowe 1972) where there is interaction between multiple genes along with environmental factors, and not following Mendelian patterns except in the extreme case of nanophthalmos.

Family history and ethnicity highlight the genetic predisposition of the disease. PACG is more common in Asian and Eskimo populations than Caucasians, and first degree relatives of patients with PACG show higher probability of developing narrow angles. (Wang, Wu et al. 2002; Amerasinghe, Zhang et al. 2011) Most studies have looked for genetic associations with PACG by analysing a number of candidate genes in cohorts of unrelated cases. Genes were chosen for their previous association with other glaucoma subtypes or their association with one of the PACG risk factors such as hyperopia or short axial length.

Unlike PACG, primary open angle glaucoma has been much more extensively studied. Up to 20 different loci have been identified for this complex disease, but only a few have been replicated in further studies. (Fan, Wang et al. 2006) Of these loci, the relevant genes have been identified in only a few cases; *Myocilin*, at 1q24 (Fingert, Heon et al. 1999) *Optineurin* at 10p13 (Sarfarazi, Child et al. 1998; Alward, Kwon et al. 2003; Craig, Hewitt et al. 2006) *WD repeat-containing protein 36* at 5q22.1. (Monemi, Spaeth et al. 2005; Hewitt, Dimasi et al. 2006) More recently, genome-wide association studies have identified; *SIX homeobox 1/ SIX homeobox 6* (*SIX1/SIX6*) at 14q23.1 (Ramdas, van Koolwijk et al. 2010; Wiggs, Yaspan et al. 2012) *Caveolin 1/ Caveolin 2* at 7q31.1 (*CAV1/CAV2*) (Thorleifsson, Walters et al.

2010; Wiggs, Kang et al. 2011) *Transmembrane and coiled-coil domains 1 (TMCO1)* at 1q22-q25, and *CDKN2B antisense RNA 1 (CDKN2B-AS1)* at 9p21.3. (Burdon, Macgregor et al. 2011; Sharma, Burdon et al. 2012)

Because glaucoma consists of many subtypes of diseases with overlapping phenotypic similarities, researchers have studied forms of glaucoma grouped according to specific clinical features. For example age of onset (such as in juvenile and congenital forms of glaucoma), or clinical presentation (such as secondary glaucomas associated with pigment dispersion or exfoliation syndrome). Identifying *Myocilin* as a glaucoma-causing gene and its role accounting for up to 4% of POAG was the end result of multiple cumulative experimental approaches. The mutations within the *Myocilin* gene were discovered in a large autosomal dominant family pedigree affected with juvenile open-angle glaucoma. (Stone, Fingert et al. 1997) Then myocilin protein had been detected in the trabecular meshwork by cellular studies. (Polansky, Fauss et al. 1997) Subsequent studies have reported that approximately 3–5% of primary open-angle glaucoma cases worldwide are attributable to mutations in the *Myocilin* gene. (Wiggs, Allingham et al. 1998; Fingert, Heon et al. 1999) Recently a mouse model of *Myocilin* glaucoma has been developed to investigate the role of this gene in the development of POAG. (Shepard, Jacobson et al. 2007; Paper, Kroeber et al. 2008) By combining all these results, we have a better understanding of *Myocilin* function and its role in POAG pathogenesis.

The same strategy needs to be conducted for PACG, so the first target is to identify the causative gene(s) for PACG. Until mid-2012 there was no genome-wide association study (GWAS) published for PACG. The complex nature of the disease,

the late age of onset, and the lower prevalence of PACG in our population has made the search for causative genes difficult in comparison to POAG. Recently, the first genome wide association study for PACG was conducted in a large group of patients with PACG from Asian ethnic groups identifying three new susceptibility loci; rs11024102 in *PLEKHA7*; rs3753841 in *COL11A1*, and rs1015213 located between *PCMTD1* and *ST18*. (Wilkins, Gasteiger et al. 1999)

Unlike PACG, nanophthalmos has been linked to several specific genes and loci. For autosomal dominant nanophthalmos, studies have reported linkage to chromosome 11p (Othman, Sullivan et al. 1998) 2q11-q14 (Li, Wang et al. 2008) and 17p12-q12. (Hu, Yu et al. 2011) To date additional families showing linkage to these regions have not been reported and the causative genes in these families has not been identified. For autosomal recessive nanophthalmos, two major genes have been reported *Membrane frizzled-related protein (MFRP)* (Sundin, Leppert et al. 2005) and *Protease serine 56 (PRSS56)*. (Gal, Rau et al. 2011; Orr, Dube et al. 2011) Mutations in the *MFRP* gene have been shown to cause autosomal recessive nanophthalmos, both isolated (Sundin, Leppert et al. 2005) or in conjunction with retinitis pigmentosa and other retinal features. (Ayala-Ramirez, Graue-Wiechers et al. 2006; Zenteno, Buentello-Volante et al. 2009; Mukhopadhyay, Sergouniotis et al. 2010) *MFRP* is a frizzled related protein likely involved in the Wnt signalling pathway, important in ocular development. (Sundin, Leppert et al. 2005) The gene is expressed in retina during the later stages of embryonic development and patients homozygous for *MFRP* mutations do not appear to undergo the normal process of axial growth to correct refraction and obtain emmetropia. (Sundin, Dharmaraj et al. 2008) *PRSS56* is a serine peptidase of the chymotrypsin family, and has been

reported following linkage analysis and fine mapping in nanophthalmos families from Tunisia and the Faroe Islands. (Gal, Rau et al. 2011) *PRSS56* is highly expressed in retinal ganglion cells and may also be involved in the remodelling of the eye during early post-natal development to establish emmetropia. (Gal, Rau et al. 2011)

The importance of identifying the genetic cause behind these two eye conditions is to reduce blindness from this severe condition, and to improve our understanding about the development of the disease. This can offer better methods for improving the diagnosis and the treatment. Identifying the genetic risk can help us to screen the high risk individuals on a regular basis and provide early management of any complications that rise from this condition. We hypothesised that due to the high rate of angle-closure glaucoma in individuals with nanophthalmos, identified causative genes for this condition would also be attractive candidates for PACG.

In this thesis, I set out to achieve a better understanding of genetic contributions to ACG, with the following specific aims:

1. To identify the genetic risk factors in the development of PACG and attempting to replicate previously associated candidate genes in two different populations (Australian Caucasian and Nepalese cohorts) recruited as part of this PhD project.
2. To investigate genetic causation in families with nanophthalmos and, to seek association of nanophthalmos genes with PACG disease.