

**Optimizing the management  
of central retinal artery  
occlusion**

**Dr. Celia Chen**

**MBBS MPhC**

**Faculty of Health Science**

**Flinders University, South Australia**

A thesis submitted in fulfilment of the requirement for the  
degree of PhD by published work

May 2011



3.3	Methods .....	47
	3.3.1 Definition .....	47
3.4	Results.....	48
3.5	Discussion .....	50
3.6	Conclusion .....	53
3.7	Contribution Statement .....	54
<b>Chapter 4: Managing systemic implications of a CRAO .....</b>		<b>55</b>
4.1	Precis .....	56
4.2	Introduction .....	57
4.3	Methods .....	57
4.4	Results .....	58
	4.4.1 Vascular Risk Factors and Co-morbidities .....	58
	4.4.2 Previously Undiagnosed Vascular Risk Factors & Treatment.....	59
	4.4.3 Carotid Artery Disease and Cardiac diseases .....	60
	4.4.4 Systemic vascular events in the follow up period .....	61
4.5	Discussion .....	62
4.6	Conclusion .....	64
4.7	Contribution Statement .....	64
<b>Chapter 5: New treatment option for acute CRAO .....</b>		<b>65</b>
5.1	Precis .....	66
5.2	Introduction .....	67
5.3	Methods .....	68
	5.3.1 Outcome measures .....	71
	5.3.2 Statistical analysis .....	71
5.4	Results .....	72
	5.4.1 Demographics and vascular risk factors .....	72
	5.4.2 Visual outcomes .....	74
	5.4.3 Complications .....	77
5.5	Discussion .....	77
5.6	Conclusion .....	80
5.7	Contribution Statement .....	80
<b>Chapter 6: Feasibility and time window of administering thrombolysis in acute CRAO .....</b>		<b>82</b>
6.1	Precis.....	83
6.2	Introduction .....	84
6.3	Methods .....	85
6.4	Results .....	88
6.5	Discussion .....	88
6.6	Conclusion .....	91
6.7	Contribution Statement .....	91
<b>Chapter 7 : Design of a randomized controlled trial to assess the efficacy of intravenous thrombolysis in acute CRAO .....</b>		<b>93</b>
7.1	Precis .....	94
7.2	Introduction .....	95
7.3	Methods .....	97
	7.3.1 Design .....	97
	7.3.2 Patient selection - inclusion and exclusion criteria .....	97

7.3.3	Randomization .....	98
7.3.4	Treatment or intervention .....	99
7.3.5	Primary outcomes .....	100
7.3.6	Secondary outcomes .....	100
7.3.7	Data Safety and Monitoring Board .....	100
7.3.8	Sample size .....	101
7.3.9	Statistical analysis .....	101
7.4	Results .....	101
7.4.1	Study patients ... ..	101
7.4.2	Visual outcome .....	104
7.4.3	Safety and adverse events .....	105
7.5	Discussion .....	106
7.6	Conclusion .....	110
7.7	Contribution Statement .....	110
<b>Chapter 8: Discussion.....</b>		<b>112</b>
8.1	Introduction .....	113
8.2	Current management of acute CRAO .....	113
8.3	Optimal management of CRAO extends beyond the eye .....	114
8.3.1	Managing ocular complications of CRAO .....	114
8.3.2	Managing systemic complications of CRAO .....	115
8.3.3	Recommendations for optimal management of CRAO .....	115
8.4	Potential therapeutic options in acute CRAO .....	116
8.5	The need for a randomized controlled trial to assess the efficacy of thrombolysis in acute CRAO .....	118
8.5.1	Mode of administration .....	118
8.5.2	The time window .....	119
8.5.3	Referral pathways .....	120
8.5.4	Recruitment centres .....	121
8.5.4	Other inclusion criteria considerations .....	122
8.6	Results of the randomized controlled trial .....	123
8.7	Future directions .....	124
8.7.1	Time window for treatment .....	124
8.7.2	Thrombolytic agent and adjuvant therapy .....	125
<b>Bibliography .....</b>		<b>127</b>
<b>Appendix .....</b>		<b>145</b>
Appendix 1 : Publication “Chen CS, Lee AW. Management of acute central retinal artery occlusion. Nature Clinical Practice Neurology. 2008;4:376- 83.” .....		145
Appendix 2 : Publication “Rudkin AK, Lee AW, Aldrich E, Miller NR, Chen CS. Clinical characteristics and outcome of current standard management of central retinal artery occlusion. Clin Experiment Ophthalmol. 2010;38:496- 501” .....		153
Appendix 3 : Publication “Rudkin AK, Lee AW, Chen CS. Ocular neovascularization following central retinal artery occlusion: prevalence and timing of onset. Eur J Ophthalmol. 2010; 20(6):1042-6.”.....		159

Appendix 4 : Publication “Rudkin AK, Lee AW, Chen CS. Vascular risk factors for central retinal artery occlusion. Eye (Lond). 2010 ;24:678-81.”..... 164

Appendix 5 : Publication “Aldrich EM, Lee AW, Chen CS, Gottesman RF, Bahouth MN, Gailloud P, Murphy K, Wityk R, Miller NR. Local Intraarterial Fibrinolysis Administered in Aliquots for the Treatment of Central Retinal Artery Occlusion. The Johns Hopkins Hospital Experience. Stroke. 2008; 39:1746-50.”.....168

Appendix 6 : Publication “Rudkin AK, Lee AW, Chen CS. Central retinal artery occlusion: timing and mode of presentation. Eur J Neurol. 2009; 16:674-7.”.....173

Appendix 7 : Publication “Chen CS, Lee AW, Campbell B, Lee T, Paine M, Fraser C, Grigg J, Markus R, Williams KA, Coster DJ. Study of the efficacy of intravenous tissue plasminogen activator in central retinal artery occlusion. International Journal of Stroke. 2011;6:87-9. .... 177

## SUMMARY

The aim underpinning this thesis is to define the best management of acute central retinal artery occlusion (CRAO). Currently, there are no effective treatments for this condition and patients often suffer profound, permanent vision loss.

In this thesis, I review the literature on the current management of acute CRAO and evaluate subsequent visual outcomes. The management of CRAO involves three aspects: early reperfusion, treatment of secondary vascular risk factors and potential treatment of local ocular complications.

Early reperfusion strategies can be broadly divided as non-thrombolytic and thrombolytic. Non-thrombolytic treatments include measures such as ocular massage to dislodge the embolus and paracentesis to change the perfusion pressure across the optic nerve head. The management of acute management of CRAO is at the discretion of individual ophthalmologist and can vary significantly. I review the current practice in two teaching hospitals and show that despite differences in management of CRAO between two institutions in different countries, visual outcomes are similar. This suggests a lack of efficacy of current standard treatment in acute CRAO.

Thrombolytics have emerged as potential therapeutic options and I evaluated the feasibility of the novel treatment option of thrombolytic in the treatment of acute CRAO. This showed that thrombolysis is a biologically feasible treatment option in acute CRAO and patients receiving thrombolysis had a better visual outcome than those treated with standard therapy alone. A clinical trial protocol designed to

evaluate the effect of acute intravenous tissue plasminogen activator in CRAO was developed and I report on the outcomes of this randomized controlled trial.

In the management of secondary vascular risk factors, a high proportion of patients presenting with CRAO often have an undiagnosed vascular risk factor. In this study, 64% of patients had at least one undiagnosed vascular risk factor and a significant proportion required either the addition or escalation of existing macrovascular preventative medications and 18% required surgical intervention for carotid recanalization. As this population is at high risk of secondary ischaemic events, risk factor modification is prudent to prevent further ischemic events.

Neovascularisation is a local ocular complication following CRAO and in our study, the overall rate of neovascularisation was 18.2%. There was a clear empirical correlation between thromboembolic CRAO and neovascularisation. Given the association between neovascularisation and CRAO, prudent clinical practice would be to review all patients with acute CRAO at regular intervals as early as 2 weeks and up to 4 months post CRAO.

The results from this thesis showed that for now, the use of intravenous thrombolysis cannot be recommended in routine clinical practice in acute CRAO. Further studies are required to determine the optimal time window for treatment and the adjuvant therapies for thrombolysis. I discuss the optimal management to limit the ocular neovascular complications and investigations to optimize the systemic atherosclerotic risk factors to reduce secondary ischemic events after CRAO.

**DECLARATION**

I certify that this thesis does not incorporate without acknowledgment any material previously submitted for a degree or diploma in any university; and that to the best of my knowledge and belief it does not contain any material previously published or written by another person except where due reference is made in the text.

**Signed** ..... **Date** .....



## **ACKNOWLEDGMENT**

I would like to thank my mentors and supervisors, Professor Keryn A. Williams and Douglas J. Costers for their support and advise. I would like to acknowledge

- The American Australian Association Education Fellowship, for funding support for the study performed at the Johns Hopkins Hospital outlined in Chapter 5
- Perpetual Trustee : The Lindsay & Heather Payne Medical Research Charitable Foundation for partial funding for the randomized controlled clinical trial in Australia.

## **CONTEXTUAL STATEMENT**

None of the work submitted in this thesis has previously been submitted for any degree in the University or any other institution.

All the works are original. My contributions for each manuscript will be stated clearly in the Contribution Statement at the end of each chapter.

Publications that are directly related to this thesis are listed in Page 10. My other publications related to retinovascular disease and ischemic disorders of the eye are listed in Page 11-12.

## **PUBLICATIONS**

The following is List of publications directly related to this thesis :

1. Chen CS, Lee AW. Management of acute central retinal artery occlusion. *Nature Clinical Practice Neurology*. 2008; 4:376-83.
2. Rudkin AK, Lee AW, Aldrich E, Miller NR, Chen CS. Clinical characteristics and outcome of current standard management of central retinal artery occlusion. *Clin Experiment Ophthalmol*. 2010;38:496-501.
3. Rudkin AK, Lee AW, Chen CS. Ocular neovascularization following central retinal artery occlusion: prevalence and timing of onset. *Eur J Ophthalmol*. 2010
4. Rudkin AK, Lee AW, Chen CS. Vascular risk factors for central retinal artery occlusion. *Eye (Lond)*. 2010;24:678-81
5. Aldrich EM,\* Lee AW,\* Chen CS,\* Gottesman RF, Bahouth MN, Gailloud P, Murphy K, Wityk R, Miller NR. Local Intraarterial Fibrinolysis Administered in Aliquots for the Treatment of Central Retinal Artery Occlusion. The Johns Hopkins Hospital Experience. *Stroke*. 2008; 39:1746-50. \*first authors contributed equally
6. Rudkin AK, Lee AW, Chen CS. Central retinal artery occlusion: timing and mode of presentation. *Eur J Neurol*. 2009; 16:674-7.
7. Chen CS, Lee AW, Campbell B, Lee T, Paine M, Fraser C, Grigg J, Markus R, Williams KA, Coster DJ. Study of the efficacy of intravenous tissue plasminogen activator in central retinal artery occlusion. *Int J Stroke*; 2011;6(1):87-9.
8. Chen CS, Lee AW, Campbell B, Lee T, Paine M, Fraser C, Grigg J, Markus R. Efficacy of intravenous tissue plasminogen activator in central retinal artery occlusion : report of a randomized controlled trial. *Stroke*. Accepted for publication February 2011.

The following are publications authored by the candidate on ischemic retinovascular disorders :

1. **Chen CS**, Miller NR. Ocular ischemic syndrome : review of clinical presentations, etiology, investigation and management. *Compr Ophthalmol Update* 2007; 8:17-28.
2. **Chen CS**, Johnson MA, Flower RW, Slater BJ, Miller NR, Bernstein SL. A novel primate model of non-arteritic anterior ischemic optic neuropathy (pNAION). *Invest Ophthalmol Vis Sci.* 2008 49(7):2985-92.
3. Ku J, Chen CS. The importance of retinal emboli detection. *Clin Exp Optom* 2010; 93:85-97.
4. Lee AW, Rudkin AK, Patel S, Agzarian M, Lake SL, **Chen CS**. Retinal vascular abnormalities in patients with cerebral amyloid angiopathy. *Cerebrovasc Dis* 2009;28:618-622.
5. **Chen CS**, Lee AW, Kelman S, Wityk R. Ischemic optic neuropathy in moyamoya disease. *European Journal of Neurology* 2007; 14:823-825.
6. Luu S, Lee AW, Chen CS. Bilateral occipital lobe infarction with altitudinal field loss following radiofrequency cardiac catheter ablation. *BMC Cardiovascular disorder* 2010, **10**:14.
7. Luu S, Lee AW, Daly A, Chen CS. Visual field defects after stroke--a practical guide for GPs. *Aust Fam Physician.* 2010;39:499-503.
8. Matti AI, Lee AW, Chen CS. Concurrent branch retinal vein occlusion and cerebral venous thrombosis from oral contraceptive pill use. *Can J Ophthalmol.* 2010;45(5):1
9. Matti AI, Lee AW, Chen CS. Traumatic vertebral artery dissection presenting with incomplete congruous homonymous quadrantanopia. *BMC Ophthalmol.* 2010;10(1):14.

10. Chu ERL, Lee AW, **Chen CS**. Resolution of visual field constriction with verapamil in a patient with bilateral optic neuropathy, migraine and Raynaud's phenomenon. *Internal Medical Journal* 2009; 39:851-852.
11. Luu S, Lee AW, **Chen CS**. Transient Monocular Visual Loss following administration of topical latanoprost: a case report. *Canadian Journal of Ophthalmology*. 2009;44(6):715.
12. **Chen CS**, Gailloud P, Miller NR. Bitemporal hemianopia caused by an intracranial vascular loop. *Archives of Ophthalmology* 2008;126:274-6.

## **LIST OF ABBREVIATION**

BCVA	best corrected visual acuity
CF	counting fingers
CRAO	central retinal artery occlusion
CRP	C-reactive protein
ESR	erythrocyte sedimentation rate
FMC	Flinders Medical Centre
GP	general practitioner
HM	hand movement
JHH	Johns Hopkins Hospital
ICH	intracerebral hemorrhage
IOP	intraocular pressure
IV	intravenous
LIF	local intra-arterial fibrinolysis
LP	light perception
MRI	magnetic resonance imaging
NIHSS	National Institute of Health Stroke Scale
NLP	no light perception
NV	neovascularization
NVD	neovascularization at the disc
NVG	neovascular glaucoma
NVI	neovascularization of the iris
PRP	panretinal photocoagulation
PTT	partial thromboplastin time
RCT	randomized controlled trial
tPA	tissue plasminogen activator
VA	visual acuity

# **Chapter 1**

**LITERATURE**

**REVIEW**

## 1.1 INTRODUCTION

Central retinal artery occlusion (CRAO) may be considered as an acute stroke of the eye, the most common etiology being a fibrin platelet thrombus or embolus that occludes the central retinal artery, leading to ischemia of the retina and optic nerve head with resultant visual loss.(1, 2) The visual prognosis of CRAO is poor with 61% of patients having a final visual acuity of 20/400 or worse. This degree of severe unilateral visual impairment is associated with limitation in social functioning and poor mental health,(3) and is also associated with an increased risk of falls and becoming dependent.(4) In addition, it may also be the first manifestation of atherosclerotic disease presaging either a cerebrovascular or cardiovascular event requiring preventative therapy.(5)

Following diagnosis, prompt acute and on-going management needs to be instituted. Current acute therapy aims to increase both retinal and optic nerve head perfusion by either arterial vasodilation, manually dislodging emboli or increasing retinal and optic nerve head perfusion pressure by decreasing intra-ocular pressure in relation to CRA blood pressure. However, these treatments have not been shown to improve visual acuity beyond the natural history of disease.(6-8)

The aim of the work presented in this thesis was to optimize the management of acute central retinal artery occlusion (CRAO). This literature review will discuss the pathogenesis of CRAO, the efficacy of current acute treatments and the rationale behind the novel treatment of CRAO with local intra-arterial thrombolysis.

## 1.2 REVIEW CRITERIA

For this review, I searched the PubMed database for articles published from 1990 to 2010 including early release publications. Search terms included “central artery occlusion”, “retinal artery occlusion”, “retinal vascular occlusion”, “thrombolysis” in conjunction with “eye” or “retinovascular”. The abstracts of retrieved citations were reviewed and prioritized by relevant content. Full articles were obtained and references were checked for additional material where appropriate.

## 1.3 WHAT IS CENTRAL RETINAL ARTERY OCCLUSION ?

CRAO is an acute occlusion of the CRA resulting in sudden painless monocular loss of vision. The vision at presentation is usually only counting fingers or less in the affected eye. The CRA is a branch of the ophthalmic artery which supplies the prelaminar part of the optic nerve and then branches into arterioles supplying the inner two thirds of the retina.(2) Infarction of the inner retina and intracellular oedema give rise to a pale retinal colour compared to its usual orange colour (Figure 1).



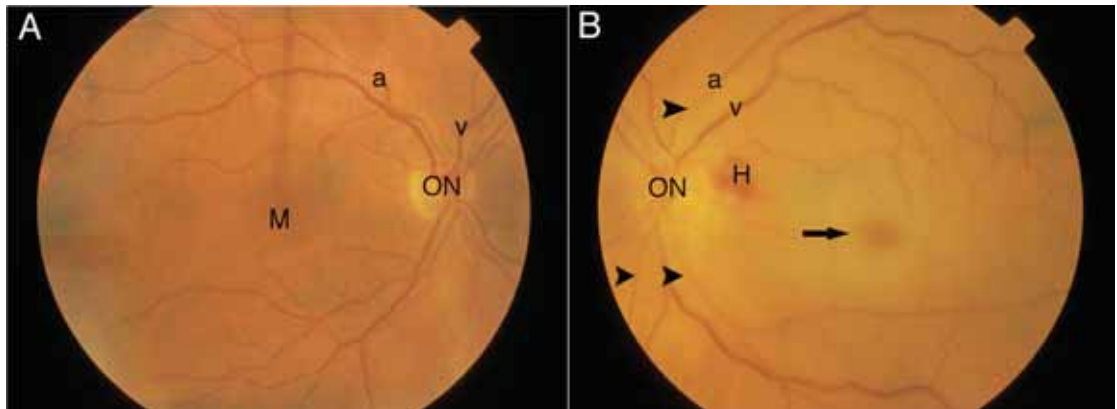


Figure 1 : Colour fundus photograph of the A) right, unaffected eye and B) left eye of the same patient showing signs of an acute CRAO. The CRAO eye shows pallor of the retina compared to A) and the macula (M) is seen as a red spot against the pale retina, described as a “Cherry red spot” (arrow). The retinal arteries (a) and venules (v) are attenuated and there is thinning of the arterioles (arrowheads). ON Optic nerve; H Peripupillary hemorrhage.

The macula is the thinnest part of the retina; the underlying choroid gives rise to a dark orange red color against the pale retina in acute CRAO. This is described as a “cherry red spot” (Figure 1B). Other signs include a relative afferent pupillary defect and a visual field defect. The retinal arterioles may have changes reflecting systemic arteriosclerosis with narrowing of the arterioles and venules and “box-carring” of flow in both arterioles and veins (Figure 1B, arrowheads). Investigation with a fundus fluorescein angiography shows a marked delay in filling of the CRA and its branches (Figure 2). Venous filling is also slowed.

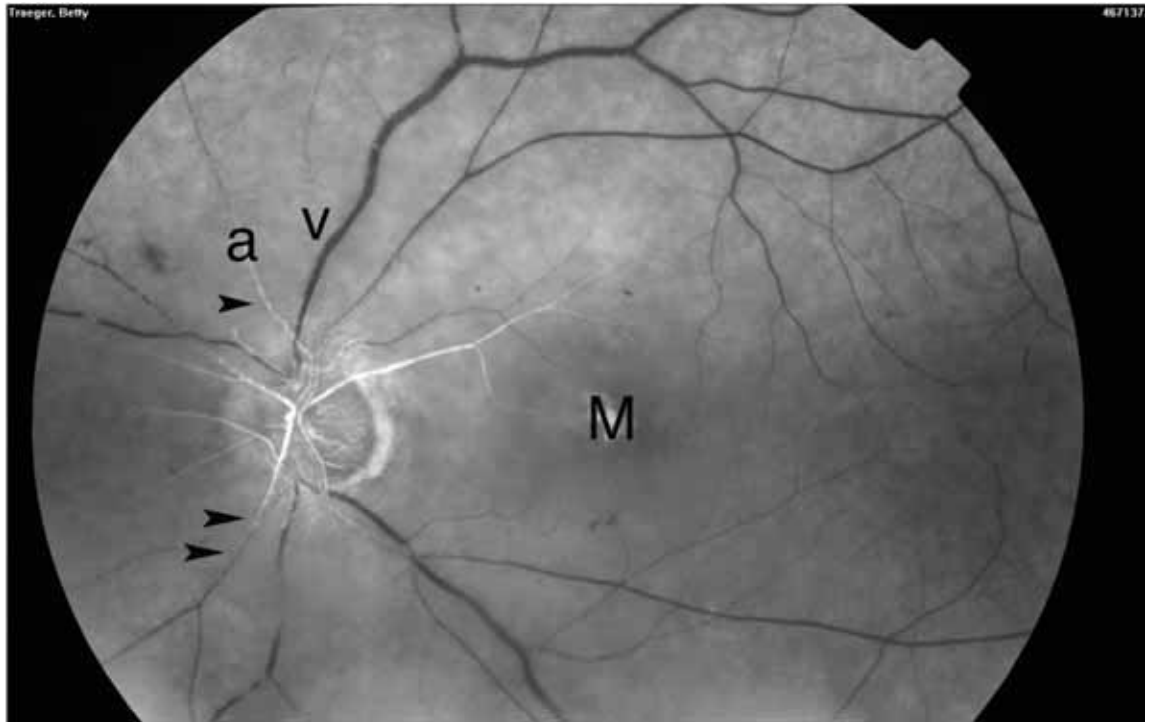


Figure 2 : Fundus Fluorescein angiography of an eye with acute CRAO showing limited and sluggish filling (arrowheads) of the retinal arteries (a) at 40 seconds after injection of fluorescein. The veins (v) were not yet filling. The macula (M) was not perfused.

CRAO may be divided into 4 subclasses: 1) Non arteritic permanent CRAO; 2) non arteritic transient CRAO; 3) non arteritic CRAO with cilioretinal sparing and 4) arteritic CRAO.(1) If the occlusion is transient, it behaves in a similar fashion to a cerebral transient ischemic attack and is termed a transient CRAO. This accounts for 15% of all CRAO cases and is the subtype most likely to have the best visual prognosis. In the vast majority of CRAO cases, the occlusion is permanent resulting in infarction of the retina.

The classification, as well as acute management, is dependent on the pathogenesis and may be broadly divided into arteritic CRAO and non-arteritic CRAO. Non-arteritic CRAO is the most common and accounts for more than two

third of all CRAO cases. Arteritic CRAO refers to vasculitic causes such as giant cell arteritis and accounts for 5% of all CRAO cases. In 15-30 % of the population a cilioretinal artery arises from the ciliary circulation to supply a portion of the papillomacular bundle, the area where the concentration of photoreceptors is maximal and is essential for central vision.(9) In this subset of people during an acute CRAO, the macula may still be perfused (Figure 3) and hence patients may still have good central visual acuity.

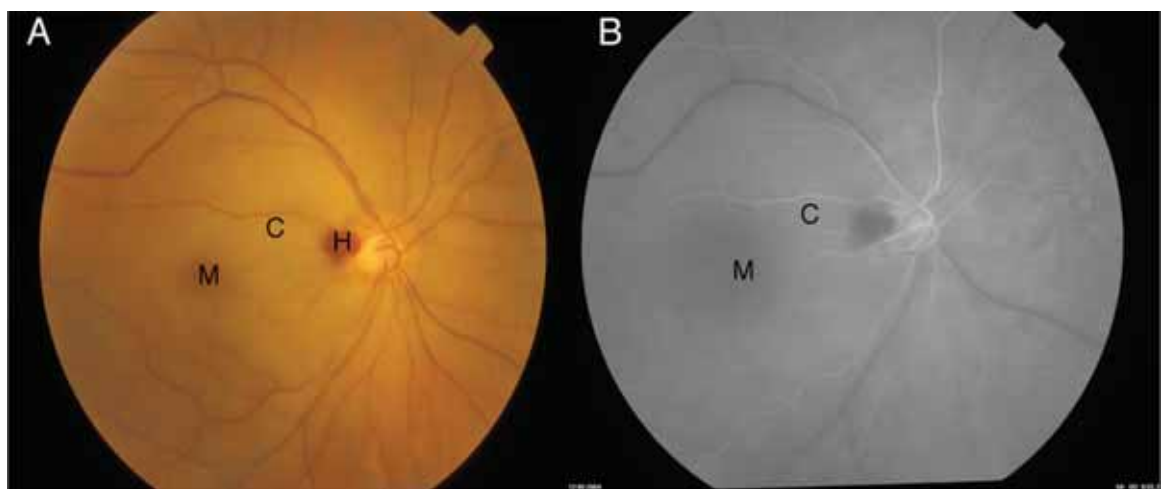


Figure 3 : Cilioretinal artery sparing CRAO. A) Color fundus photograph B) fundus fluorescein angiography. The cilioretinal artery (C ) perfuses the superior part of the macula (M) and the patient had vision of 20/80 at presentation. There is a peripapillary hemorrhage (H) temporal to the optic disc.

## 1.4 PATHOGENESIS OF CRAO

### 1.4.1 Thromboembolism

The most common cause of CRAO is a thrombus or embolus that lodges in the CRA. The nature of occlusion has been debated and it is felt that an acute thrombus more commonly causes a CRAO compared to an embolus that often is

smaller and causes a branch retinal arterial occlusion.(6) The location of occlusion is usually immediately posterior to the lamina cribrosa,(7) the portion of the optic nerve adjacent to the sclera. If the occlusion is anterior to the lamina cribrosa, the embolus may be visible on fundoscopy but this occurs in less than 20% of CRAO cases.(8, 10)

Patients with CRAO due to emboli have a higher mortality rate compared to those without emboli.(11, 12) The majority of emboli originate from the heart or carotid arteries. The composition of these emboli vary and include fibrin-platelet plugs, cholesterol plaques, and calcium fragments.(13) In young patients (ie. age <45) with acute CRAO of embolic origin, a cardiac pathology such as atrial myxoma or other cardiac tumor (14) and congenital or rheumatic heart disease should be considered.(15) In very rare situations, internal carotid artery emboli causing CRAO from a carotid artery dissection or aneurysm have been described.(16)

The risk factors for CRAO are those for atherosclerosis.(17) Hypertension and diabetes are the most common associations. (17) Other associated atherosclerotic risk factors include hypercholesterolemia, smoking and a family history of macrovascular disease.(18, 19) CRAO is also associated with coronary artery disease, atherosclerotic carotid disease and peripheral vascular disease.

In young patients, proatherogenic states such as hyperhomocysteinemia, hypercoagulable states, such as those that occur in patients with Factor V Leiden deficiency, deficiency of protein C, protein S, or antithrombin III, antiphospholipid antibody and mutations in the prothrombin G20210A gene should be investigated.(20-23) Other rare systemic disease reported to cause CRAO include

sickle cell disease (24) and paraneoplastic syndromes;(25) both of which contribute to a hypercoagulable state. In some patients, no significant atherosclerotic risk factors are found but there is a history of migraine,(26) suggesting a possible role of vasospasm in CRAO.

#### 1.4.2 Retinal vasculitis

Vasculitides that affect large and medium-sized vessels may cause inflammatory occlusion of the CRA.(1) Fortunately, these are uncommon and account for less than 5 % of CRAO cases. Of these vasculitides, giant cell arteritis (GCA) is the most common and may produce unilateral or bilateral CRAO that is often, but not always refractory to treatment with systemic corticosteroids. Other causes of vasculitic/arteritic CRAO include systemic lupus erythematosus, polyarteritis nodosa, Takayasu's aortitis, Wegener's granulomatosis(27) and rarely post viral infection such as Herpes zoster.(7)

#### 1.4.3. Iatrogenic

Iatrogenic causes of CRAO are rare but have been described in the context of autologous fat injection into the nasolabial groove, (28) intralesional steroid injection for eyelid capillary hemangioma,(29) or post spinal surgery.(30) The pathogenesis of peri-operative visual loss is not fully known and possibly multi-factorial. Postulated mechanisms include direct pressure on the eye and orbital structures during surgery from an incorrect positioning of a firm headrest that may cause a CRAO,(31) but both hypovolemia and hypotension have also been hypothesized as being contributing factors.(32) Vinerovsky et al. reported two cases of CRAO from peribulbar anaesthesia and postulated these to be from the vasospastic effect of epinephrine on the retinal and optic nerve circulation.(33)

## 1.5 CURRENT ACUTE MANAGEMENT

There is no consensus regarding acute management for CRAO. This is partly because there are many variables involved, including the degree of vascular obstruction, the presence of a cilioretinal artery and the underlying pathogenesis. The rationale for acute treatment is to remove the blockage to the central retinal artery.

Differing opinions exist as to how long after the artery is blocked that permanent visual loss occurs.(34-36) Early primate experiments suggested that the retina had an ischemic tolerance time of a mere 97 – 100 minutes.(35) However experiments in primate models representing an increased burden of atherosclerosis showed that recovery of retinal function could occur at up to 240 minutes post occlusion, resembling to a certain extent the therapeutic window of the ischemic penumbra in cerebral stroke.(34) Clinical improvement with intervention 24-48 hours after the onset of CRAO has also been reported.(37)

The following discussion on therapy concentrates mainly on non-arteritic CRAO of presumed thromboembolic origin that forms the majority of CRAO cases. It is important to note that any clinical suspicion of an arteritic CRAO, from giant cell arteritis, as well as other vasculitides, carries the risk of bilateral visual loss and is associated with a significantly increased mortality and morbidity.(38) These patients should be treated immediately and efforts made to establish the underlying diagnosis. For example, if giant cell arteritis is considered likely, the patient should have an erythrocyte sedimentation ratio (ESR) and C-reactive protein (CRP) assay drawn and then be treated immediately with high-dose intravenous corticosteroids,

following which the diagnosis can be confirmed with a unilateral or bilateral temporal artery biopsy.

Current acute management of non arteritic CRAO can be divided into non-invasive standard therapy versus invasive, local intra-arterial fibrinolysis therapy. Non-invasive therapy can be grouped into 4 main areas.

### 1.5.1. Non-Thrombolytic Therapy

#### *1.5.1.A. Observation*

Physiologically, spontaneous recanalization of the occluded CRA may occur within 48-72 hours. Spontaneous recanalization with restoration of retinal blood flow may be partial(10) and current reported spontaneous visual improvement rate varies from 1-10% of cases of non-arteritic CRAOs.(6, 39, 40)

There is debate amongst various groups as to what constitutes a significant improvement in visual acuity. Some authors have suggested that a 2 - 3 lines or greater visual improvement on Snellen acuity chart is significant as it is considered a doubling of the visual angle(41) but occurs in less than 10% of individuals who re-perfuse spontaneously.(20)

#### *1.5.1.B. Dilation of retinal arteries and increasing oxygen content of blood*

Non-invasive interventions such as giving sublingual isosorbide dinitrate, systemic pentoxifylline, inhalation of carbogen (a mixture of 95% oxygen and 5% carbon dioxide) or rebreathing of expired carbon dioxide have been tried.(20, 42-44) These treatments are thought to vasodilate the central retinal artery and thus increase retinal blood flow. Physiologically, increases in retinal blood flow using retinal

Doppler ultrasonography have been shown but these studies did not document an association between clinical improvement in terms of visual acuity or visual field changes with increases in retinal blood flow.(45)

Hyperbaric oxygen has also been tried, to increase diffusible oxygen content to the ischemic retina, but the results have been equivocal.(46)

#### *1.5.1 C. Attempts to dislodge embolus*

Measures to dislodge the emboli with ocular massage either directly or through a contact lens to allow observation of the retinal circulation at the same time have been described.(10) Rumelt (42) assessed the success of using ocular massage with a three-mirror contact lens with the endpoint being improved retinal arterial blood flow defined as the reestablishment of continuous laminar flow, an increase in the width of the blood column, and disappearance of fragmented flow. All the patients also received sublingual isosorbide dinitrate, intravenous acetazolamide, intravenous mannitol and oral glycerol. Only one out eight patients had improved retinal blood flow on this regimen, suggesting that ocular massage, alone or with measures to dilate the retinal arteries and lower intraocular pressure, has a limited success rate.

#### *1.5.1.D. Increasing retinal artery perfusion pressure by a reduction of intraocular pressure*

As mean ocular perfusion pressure is the difference between mean arterial pressure and intraocular pressure, attempts have been made to reduce the intraocular pressure and thus increase ocular perfusion. Measures used include anterior chamber paracentesis and the withdrawal of a small amount of aqueous fluid from the eye,



intravenous acetazolamide or mannitol to acutely reduce intraocular pressure.(19, 20, 42, 47)

Most patients receive a combination of the above therapies. Atebara *et al.* compared the efficacy of anterior chamber paracentesis and carbogen inhalation versus no acute treatment but found no statistically significant differences between the treated versus the untreated group.(20) Rumelt *et al.*(42) and Landa *et al.*(48) both evaluated the effect of a systemic step-wise approach starting from ocular massage, globe compression, sublingual isosorbide dinitrate, intravenous acetazolamide, followed by intravenous mannitol, methylprednisone and eventually intravenous streptokinase and retrobulbar tolazoline. Both studies were limited by small patient numbers, but found a greater visual improvement in those who received multiple non-invasive interventions versus those who received few interventions. Importantly, Landa *et al.* concluded that all of their patients had decreased visual function post therapy.(48)

### 1.5.2. Thrombolytic Therapy

#### *1.5.2.A. The rationale for thrombolytic therapy*

By far the most recent and exciting development in the treatment of CRAO is the use of thrombolytic therapy. Systemic and intra-arterial thrombolysis have been successful in restoring perfusion to ischemic tissue by fibrin-platelet clot lysis in ischemic stroke and myocardial infarction.(49-51) There are two main assumptions for the use of thrombolysis in CRAO: 1) that it is of a non-arteritic aetiology; and 2) the material occluding the CRA is a fibrin – platelet thrombus or embolus that can be lysed.

In several open-label studies, local intra-arterial fibrinolysis (LIF) was efficacious in the treatment of CRAO, with up to 60-70% of treated subjects experiencing an improvement in visual acuity (VA).(39, 40, 52, 53) In contrast, subjects treated with standard therapy had a poor visual outcome consistent with previous natural history studies of CRAO.(7, 8)

#### *1.5.1.B. Administration of thrombolytics*

Intravenous and intra-arterial administration of streptokinase and tissue plasminogen activator (tPA) have both been used in patients with CRAO. Kattah *et al.*(54) administered tPA intravenously and reported 10 out of 12 CRAO patients achieving some form of VA improvement with no thrombolytic related systemic or neurological complications. However, 4 of these patients consequently developed neovascular glaucoma.

Intra-arterial administration of thrombolytics delivered directly to the ophthalmic artery and hence to the CRA usually uses a continuous infusion of tPA with a dose range of between 40-80mg or urokinase in a dose range from 300,000 to 1 million units.(52, 53, 55) In several open-label studies, the efficacy of local intra-arterial fibrinolysis (LIF) was demonstrated in CRAO, with up to 60-70% of treated subjects experiencing an improvement in visual acuity VA.(40, 52, 53, 56) Reported adverse effects included ischemic cerebrovascular accidents, and both intracerebral and systemic bleeding.(39, 52, 55) A United States Nationwide Inpatient Survey found that intra-arterial thrombolysis was given to 1.9% of patients presenting with CRAO and was offered in selected urban hospitals only. There was no in-hospital

mortality or intracranial hemorrhage reported among any patient with CRAO treated with thrombolysis.(57)

There have been several criticisms levelled at these early reports. The first is that a number of these studies deployed LIF beyond the 97 – 240 minutes that primate experiments showed was the maximal retinal ischemic tolerance time. The second is the assumption that CRAO is caused by fibrin platelet thrombi that are lysable. One early report demonstrated that 50% of visible emboli are of cholesterol and such emboli would not respond to thrombolysis.(58) However this study looked at visible emboli, but in CRAO, the majority of emboli occur at the level of the lamina cribrosa and hence are not visible on funduscopy. Therefore, one cannot assume that a study of visible emboli necessarily represents the frequency distribution of retinal emboli types in CRAO.

The main controversy is whether the use of LIF results in an improvement in visual function that is above and beyond that found in the natural history of disease.(1) The studies listed to date have used variable measures of outcome, such as an improvement in VA of 1 line or more and have not necessarily included physiological secondary endpoints such as objective documentation of retinal blood flow on fluorescein angiography.(59) The lack of consistency of even a primary endpoint such as the number of lines of improvement of VA on a Snellen chart makes comparison between interventional and natural history studies difficult. In addition, questions still remains as to the route of administration and the optimal time window for therapy.

## 1.6 CONCLUSION

In summary, all current acute managements have limited efficacy and are based on non randomized studies. Of all the treatments to date, thrombolysis shows most promise. A randomised controlled trial is required before recommendation for its use in daily clinical practice can be made.

## 1.7 CONTRIBUTION STATEMENT

Parts of the content of this chapter were published in

Chen CS, Lee AW. Management of acute central retinal artery occlusion. *Nature Clinical Practice Neurology*. 2008; 4(7):376-83 (Appendix 1)

( 2009 ISI Impact factor 6.362)

Further literature of literature on the topic from 2007 to 2010 were included in this chapter and the section 1.5.2 on Thrombolytic Therapy updated.

I was the first and corresponding author for this article and was primarily responsible for the design, research, drafting, revision and final approval of the manuscript.

# **Chapter 2**

## **Current Management of Acute Central Retinal Artery Occlusion**

## 2.1 PRECIS

In this chapter, I investigated the visual outcomes after acute central retinal artery occlusion (CRAO) in patients administered current standard therapy at two university teaching hospitals : the John Hopkins Hospital (JHH) in the United States, and the Flinders Medical Centre (FMC), Australia. The outcome measures were visual acuity, and subsequent ocular and systemic ischemic events. All patients from JHH were treated as inpatients, whereas 79% of patients from FMC were treated as outpatients. More patients in the JHH cohort underwent paracentesis, ocular massage or were treated with intraocular hypotensive agents (76%) than in the FMC cohort (26%). However, there was no significant difference in visual outcome between the two cohorts ( $p = 0.114$ ). The results showed that despite differences in management of CRAO between two institutions in different countries, visual outcomes for patients were similar. This in turn suggests a lack of efficacy of current standard treatment in acute CRAO.

## 2.2 INTRODUCTION

Central retinal artery occlusion (CRAO) is an ocular emergency, as it is a stroke of the eye caused by obstruction of the central retinal artery, usually by a thrombus or embolus (42, 60) that results in painless, disabling vision loss. Treatment of CRAO is problematic as both acute and secondary preventive therapies are based on observational studies rather than randomized controlled trials. Part of the problem is the low incidence of CRAO which represents 1 in 10,000 ophthalmic outpatient visits.(61) Therefore, any randomized controlled trial would require participation by multiple centers to achieve a sufficient number of subjects needed to demonstrate efficacy of any proposed therapy. Such a trial might best be performed via an international collaboration to ensure generalizability of this therapy to the global population at risk.

As a prelude to such a trial, it would be useful to determine baseline characteristics, outcomes and current treatments for CRAO at different centers in different countries. Current acute management for CRAO varies depending on physician preference and treatment center protocol. For example, in some hospitals, all CRAO patients are admitted to the stroke ward for secondary vascular prevention evaluation, whereas physicians in other hospitals routinely treat CRAO as outpatients. Current treatment of acute CRAO in most hospitals and eye centres around the world includes measures such as ocular massage, paracentesis, inhalation of a mixture of 95% oxygen and 5% carbon dioxide (carbogen), and other methods aimed at reducing intraocular pressure and improving blood flow to the eye.(18) Although preliminary studies of thrombolytic agents appear promising in acute CRAO, a randomized controlled trial is needed to establish its safety, efficacy and optimal mode of administration prior to its use in standard clinical practice.

Determining the similarities and differences in the visual outcome and treatment of CRAO across national borders would add useful information in planning such a trial. To provide these data, we investigated the current standard management used and visual outcomes in two cohorts of CRAO patients, one from Australia and one from the United States.

### 2.3 METHODS

We performed a retrospective review of two cohorts of patients with acute CRAO treated in two study centers, Johns Hopkins Hospital (JHH) in the United States and Flinders Medical Centre (FMC) in Australia, between 1996 and 2006. The cohort of previously published CRAO patients treated with local intra-arterial thrombolytic at JHH were excluded from this analysis.<sup>(62)</sup> None of the FMC cohort received thrombolytic therapy.

In both groups, the diagnosis of CRAO was based on the initial ophthalmologist's clinical diagnosis of a documented visual disturbance due to a central retinal artery occlusion, characterized by a cherry red spot in the macula and attenuation of blood vessels on fundoscopic examination. Arteritic CRAO was excluded on clinical grounds as well as by the absence of elevated inflammatory markers, a temporal artery biopsy showing no evidence of vasculitis, or a combination of these factors. Only non-arteritic/thromboembolic CRAOs were included in the analysis. Patients with arteritic and transient CRAO, as well as those with cilioretinal artery sparing, were excluded from this study.



The acute management of each cohort consisted of either observation or current recommended interventions, including paracentesis, ocular massage, administration of an ocular hypotensive agent, or a combination of these procedures.

Data collected included demographic details, prior medical history with a particular emphasis on the patient's current or previous vascular risk factors such as hypertension, diabetes mellitus, hypercholesterolemia, and atrial fibrillation as well as any treatment the patient had received both before and immediately after the sentinel CRAO event. Investigative findings were documented, including echocardiography and imaging of the carotid arteries. During the follow-up period, both ocular and systemic vascular events were documented using active ascertainment.

#### 2.3.1.Data Analyzed

The primary visual outcome was the best-corrected visual acuity (BCVA) at final follow up. Visual acuity was assessed using a Snellen chart. For the purpose of analysis, these results were converted to the logarithm of the minimal angle of resolution (logMAR) units. This was calculated by obtaining the logarithm of the reciprocal of the Snellen visual acuity for vision better than or equal to 5/200. If the vision was worse than 5/200, the following conversion was used: counting fingers (CF) = 1.6; hand movements (HM) = 2.0; light perception (LP) = 2.5; and no light perception (NLP) = 3.0 logMAR units.<sup>(63)</sup> Separate outcome measures were the frequency distribution of major vascular risk factors at presentation and following the diagnosis of CRAO in the two cohorts, and the incidence of a subsequent ocular or systemic ischemic event, such as stroke, acute coronary ischemia, or an acute peripheral vascular event.

### 2.3.2. Statistical Analysis

The best corrected visual acuity (BCVA) in LogMAR score was expressed as continuous variable (mean  $\pm$  standard deviation [SD]), whereas dichotomous variables were expressed as a proportion or percentage. The Student's t-test was used, and a p-value less than 0.05 was considered significant. For the purpose of analysis of vascular risk factors, descriptive statistics were used.

The study was approved by the Flinders Clinical Research Ethics Committee.

## 2.4 RESULTS

### 2.4.1. Patient characteristics

There were 21 patients from the JHH cohort and 19 from the FMC group. The JHH cohort comprised of 14 males and seven females. The mean age was  $56.6 \pm 16.3$  years (range: 23-90 years; median age: 65 years). The FMC cohort consisted of nine males and 10 females, with a mean age  $75.9 \pm 8.7$  years (range: 57-88 years; median: 71 years). The mean follow-up period was  $11.2 \pm 13.1$  months (range: 2-56 months) in the JHH cohort and  $35.4 \pm 34.9$  months (range: 4-132 months) in the FMC cohort. The mean time to presentation in the JHH cohort was  $25.8 \pm 20$  hours compared with  $31 \pm 65$  hours in the FMC cohort. There were no statistically significant differences between the demographics and presentation time between the two cohorts.

### 2.4.2 Acute Management of CRAO

Seventy-six percent of patients in the JHH cohort received an acute intervention for CRAO in the form of paracentesis, ocular massage, agents to lower

the intraocular pressure, or a combination of these procedures compared with 26% of FMC patients ( $p=0.008$ ). The percentage of patients receiving each acute treatment option for CRAO is indicated in Table 1. In the JHH cohort, six patients received all three treatments, six received two of the treatments, and three received one treatment. In the FMC cohort, two patients received all three treatments, one received two treatments, and two received one treatment.

Table 2.1: Acute Therapy for CRAO administered by the 2 cohort

	<b>JHH Group (<i>n</i> = 21)</b>	<b>FMC Group (<i>n</i> = 19)</b>
No Treatment	5 (24%)	14 (74%)
Paracentesis	14 (67%)	4 (21%)
Ocular Hypotensive Agent	10 (48%)	3 (16%)
Ocular Massage	9 (43%)	3 (16%)
Average number of non-thrombolytic interventions tried (mean $\pm$ standard deviation)	1.57 $\pm$ 1.20	0.53 $\pm$ 1.02

### 2.4.3 Visual Outcome

The mean change in BCVA in the JHH cohort before and after treatment was 0.07 (range: 2.04  $\pm$  0.57 to 1.97  $\pm$  0.77 [ $p = 0.724$ ]). Six patients had an improvement in BCVA, nine had no change, and six worsened. The mean change in BCVA before and after intervention in the FMC cohort was -0.19 (range: 1.97  $\pm$  0.44 to 2.16  $\pm$  0.59 [ $p = 0.268$ ]). Two patients in this cohort had an improvement in BCVA, 11 had no change and six had a further decline. There was no statistically significant difference in the final BCVA between the two cohorts ( $p = 0.114$ ) (Figure 2.1).

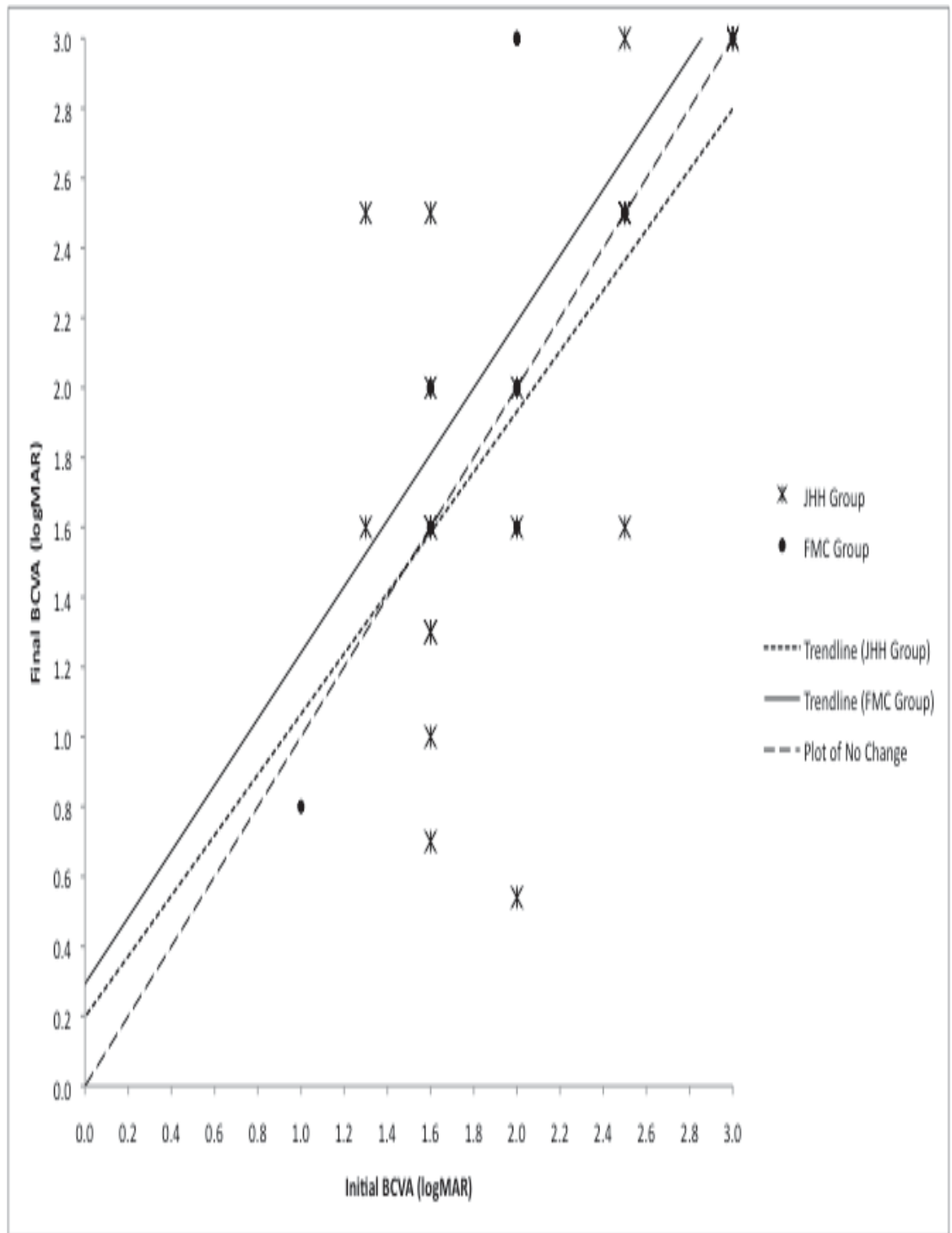


Figure 2.1: Scatter plot showing change in visual acuities in the JHH and FMC groups. The change in visual acuities in the two groups approximates the line showing no change between the final to the initial best corrected visual acuity (BCVA). There was no statistically significant difference in the final BCVA between the two cohorts ( $p>0.05$ ).

#### 2.4.4 Vascular Risk Profile

There were no statistically significant differences between the two cohorts in the major vascular risk factors identified at presentation (Table 2) or diagnosed after the retinal occlusive event (Table 3). Hypertension was the most common vascular risk factor in both cohorts at the time of diagnosis.

In addition to the risk factors summarized in Table 2.2, a number of miscellaneous risk factors for CRAO were present in each cohort at presentation.

Table 2.2: Vascular Risk Factors & Co-morbidities of Patients Presenting with CRAO

	<b>JHH</b>	<b>FMC</b>	<b>P-</b>
	<b>Cohort (%)</b>	<b>Cohort (%)</b>	<b>value</b>
Hypertension	62	57	0.80
Hyperlipidemia	33	33	0.90
Diabetes mellitus	24	26	0.86
Atrial fibrillation	5	10	0.50
Cardiomyopathy or cardiac valvular disease	10	5	0.50
Personal history of vascular disease <sup>#</sup>	43	42	0.96
Family history of vascular disease	29	22	0.66
Tobacco use	38	21	0.25

<sup>#</sup> Includes a history of peripheral vascular disease, coronary artery event, ischemic heart disease, transient ischemic attack or stroke.

The JHH cohort included two patients with a history of intravenous cocaine use, one patient with a history of alcohol abuse, and two patients with chronic renal failure. The FMC cohort included two patients with connective tissue disorders and systemic vasculitis (scleroderma and Sjögren syndrome, respectively).

Sixty-three percent of the FMC cohort and 57% of the JHH cohort had at least one new vascular risk factor found after the CRAO event. Hyperlipidemia was the most common new vascular risk factor diagnosed after the sentinel CRAO event. Many patients required new medications or upward titration of medication for better control of their vascular risk factors (55% of FMC and 48% of JHH patients). All patients received anti-platelet therapy and in some cases anticoagulants depending on the vascular risk factors such as atrial fibrillation. In those with significant ipsilateral carotid stenosis >70%, recanalization procedures with carotid endarterectomy or stenting were performed. In addition to the risk factors diagnosed after presentation, summarized in Table 2.3, one patient in the JHH cohort had a low serum concentration of Protein C, and another had Protein S deficiency.

Table 2.3: New Vascular Risk Factors & Co-morbidities of patients presenting with CRAO (Diagnosed after Investigation)

	<b>JHH</b>	<b>FMC</b>	<b>P-</b>
	<b>Cohort (%)</b>	<b>Cohort (%)</b>	<b>value*</b>
Hypertension*	10	26	0.17
Hyperlipidemia	30	42	0.38
Diabetes mellitus	5	11	0.50
Cardiomyopathy or cardiac valvular disease	19	5	0.20
Atrial fibrillation	0	0	-
Ipsilateral carotid artery stenosis			
50-69%	18	12	0.68
70-100%	12	15	0.98
Hyperhomocysteinemia	10	5	0.53

\* Student's t-test, two-tailed, unpaired

\* Newly diagnosed hypertension or a blood pressure amenable to further reduction to achieve an optimum level.

#### 2.4.5 Inpatient versus Outpatient Management

All 21 patients in the JHH cohort were evaluated and treated as inpatients on the Neurology Stroke Service. In the FMC cohort, four patients (21%) were evaluated and treated as inpatients; the remaining 15 patients (79%) were managed as outpatients. The reasons for inpatient management in the FMC cohort were as follows: two patients had already been admitted to a general medical unit for other medical conditions before an ophthalmologist was asked to assess the patient, and two patients were admitted to a general medical service after the diagnosis of CRAO for occupational therapy and social work input because of concerns that they would require additional support for safe functioning at home.

#### 2.4.6 Secondary Ischemic Events

In the JHH cohort, one patient developed a stroke 3 months post-CRAO. In the FMC group, one patient developed a stroke 5 years post-CRAO on the contralateral side and one developed angina 8 months post-CRAO. The difference in outcomes was not significant ( $p = 0.944$ ). All three patients had significant vascular co-morbidities including hypertension, hyperlipidemia, tobacco use, and carotid artery disease. The patient from the JHH cohort had a total internal carotid artery occlusion that was not amenable to recanalization.

### 2.5 DISCUSSION

In this study, there were notable differences in the initial management of patients with CRAO between the two institutions. JHH managed all CRAO patients as inpatients, whereas 79% of patients in the FMC cohort were managed as outpatients. Recommended treatment strategies including paracentesis, ocular massage and administration of ocular hypotensive agents were frequently employed

in the JHH cohort, whereas the FMC cohort tended to be observed. Despite these differences, including the younger mean age of the JHH cohort, there was no significant difference in the final visual outcome between the two cohorts. Furthermore, the final visual outcome in both populations was similar to that in a large retrospective series of CRAO patients reported by Hayreh and Zimmerman.(1)

The most likely explanation for the lack of significant difference in the final visual acuity between our two cohorts is that the causes of the CRAO were similar in both sets of patients and that there is no benefit of the use of currently recommended interventions compared with observation in this condition. This finding is consistent with other studies that have shown that the use of paracentesis, ocular massage, and acetazolamide does not alter the natural history of disease.(20, 64, 65) Furthermore, the average number of standard non-thrombolytic interventions in this study (1.57 in JHH and 0.53 in FMC) was lower compared with the average number of  $2.5 \pm 1.4$  interventions described in the literature but the visual outcomes were comparable,(42) suggesting that current standard management options, whether single or in combination, do not significantly affect the visual outcome. The use of current standard treatment thus remains at the discretion of the treating ophthalmologist.

Secondary systemic ischemic events occurred in three patients (7.5%). This rate is low compared with previous reports of stroke rates as high as 40% in CRAO patients with known extracranial internal carotid disease who were not treated with endarterectomy.(66) I acknowledge that a limitation of the study is its retrospective design and as such, we are unable to control for all confounders such as the relatively short follow-up period. Indeed, the mean follow-up period for the JHH cohort was



11 months. However, an alternative explanation for the low incidence of secondary systemic vascular events in the two cohorts is that all patients in both cohorts were evaluated for carotid artery disease, and all had management of their disease according to established guidelines,(67) including appropriate intervention for vascular risk factors as well as universal treatment with anti-platelet agents.(17, 68)

Defining effective treatments for CRAO has been problematic as current “standard” therapies are based on non-randomized interventional studies, often comparing outcomes with historical controls that are non-contemporary. In addition, because of the relatively low incidence of CRAO, single-center studies investigating the natural history and baseline characteristics have had to recruit subjects over decades. The two largest series recruited patients spanning 3 decades.<sup>3,15</sup> One of the criticisms of such an approach is that one must assume that both the disease phenotype and the treatment strategy remain static over a long period of time. The alternative is to analyze the same data over a shorter time interval, but in order to achieve sufficient cases in an uncommon disease such as CRAO, a multi-center registry would have to be used. The current study, as well as providing comparative data between two institutions in two different countries, is also a first in terms of demonstrating the feasibility of an international collaboration required for a registry of cases of CRAO.

Fibrinolysis using intra-arterial or intravenous tissue plasminogen activator (tPA) is a promising new therapy in the acute management of CRAO.(69) There is robust evidence to support fibrinolysis in myocardial or cerebral ischemia;(49, 51)<sup>17,18</sup> however, it has not yet been proven in a well-designed randomized controlled trial for CRAO. The potential time window for thrombolysis in CRAO is debated

and thought to be longer than for treatment of ischemic stroke, where tPA is approved by the Federal Drug Administration within 3 hours of stroke onset.(49) In primate models of CRAO, reversing CRA ischemia within 97 minutes achieves complete recovery of the visual evoked potential (VEP).(35) However, in ischemia up to 240 minutes, reversal of CRA ischemia still results in partial VEP recovery. In most retrospective interventional case series, clinical improvement with tPA occurs up to 12 hours. Recently, Aldrich et al.(62) reported a prospective non-randomised interventional study of tPA use in CRAO up to 15 hours from the onset of CRAO. However, it is generally believed that “time is tissue” in thrombolysis and some studies have reported efficacy with vision recovery in CRAO in those who received interventions within 6.5 hours.(70) The time to presentation of CRAO patients in both cohorts described here was generally more than 24 hours ( $25.8 \pm 20$  hours and  $31 \pm 65$  hours respectively), and this may have limited the potential for recovery. If a viable treatment option is available, efforts need to be made to promote patient and physician awareness of the condition and its potential treatment so that patients present within a few hours rather than a day or more after visual loss.

## 2.6 CONCLUSION

In conclusion, notable differences were demonstrated in the initial management of patients with CRAO in two institutions in different countries; however, despite the use of paracentesis, ocular massage and ocular hypotensive agents, visual outcomes were similar. This suggests a lack of efficacy of current standard treatment in acute CRAO.

## 2.7 CONTRIBUTION STATEMENT

This manuscript is published in :

Rudkin AK, Lee AW, Aldrich E, Miller NR, Chen CS. Clinical characteristics and outcome of current standard management of central retinal artery occlusion. Clin Experiment Ophthalmol. 2010;38:496-501. (Appendix 2)

I was the senior and corresponding author who had the conceptual design for the study. I conducted and coordinated the study between two centres at the Johns Hopkins Hospital and the Flinders Medical Centre. I extracted data from the Johns Hopkins Hospital and coordinated the data extraction by Dr. Rudkin who was the Resident Medical Officer working with me at Flinders Medical Centre. I was involved in the design, analysis, revisions and final submitted manuscript.

Dr. Lee performed the statistical analysis and approved the final revision of the manuscript. Drs. Aldrich and Miller were the attending doctors responsible for the patients at Johns Hopkins Hospital and approved the final version of the manuscript.

# **Chapter 3**

## **Managing the ocular consequences of a CRAO**

### 3.1 PRECIS

In this chapter, I describe a retrospective study I conducted to determine the prevalence of ocular neovascularization following acute CRAO at the Flinders Medical Centre. There is no consensus on the best follow-up regimen post CRAO to detect the ocular neovascular complications and optimally manage CRAO. Furthermore, much debate exists in the literature as to the prevalence and etiology of neovascularisation following a CRAO.

In this study, I found a 18.2% prevalence of ocular neovascularisation in our cohort and the mean time from CRAO to observed neovascularization was 8.5 weeks (range 2-16 weeks). There was a definite temporal relationship between the CRAO and neovascularization events, with no other causes of neovascularization demonstrable in our cohort of patients.

Our study suggests that NV can occur early and regular follow-up, especially in the first 4 months, are important post CRAO.

### 3.2 INTRODUCTION

Ocular neovascularisation is a process of unregulated and misguided growth of new vessels in the eye. It is thought to occur as a result of chronic retinal ischaemia, and multiple mediators have been implicated in this process, of which the most important is vascular endothelial growth factor. New vessels can grow into nearly all mature ocular tissues and affect the cornea, iris, retina and optic disc. (71) Central retinal artery occlusion (CRAO) can result in ocular neovascularisation : the most serious of these complications is the development of neovascular glaucoma (NVG). The growth of new vessels in the angle of the anterior chamber initially impairs aqueous outflow in the presence of an open angle, however the disease can progress and lead to formation of peripheral anterior synechiae and subsequent contraction and closure of the angle. This process can be severe and relentless, and may lead to intractable eye pain.(72) NVG is a commonly cited indication for enucleation or evisceration. (73, 74)

The literature reports disparate rates of ocular NV associated with CRAO. These range from as low as 2.5% to as high as 31.6%.(54, 75). The causal association of CRAO and ocular NV has therefore been challenged.(76) Critics of this association argue that in central retinal *vein* occlusion there is chronic retinal hypoxia, whereas in CRAO there is acute, severe retinal ischemia. It is suggested that only chronic retinal hypoxia may liberate vasoproliferative growth factors, a process not present in CRAO.(77) It is thus proposed that other factors, including diabetes mellitus and ocular ischaemic syndrome are responsible for the occurrence of neovascularisation following CRAO.(76)

I present a case series of patients with thromboembolic CRAO, and describe

the prevalence of ocular NV. We conducted a thorough analysis of the patient series in terms of timing of NV post CRAO and co-morbidities to determine whether another cause of neovascularisation was likely to be present.

### 3.3 METHODS

A retrospective review of a cohort of CRAO patients admitted to the Flinders Medical Centre between January 1997 and January 2009 was conducted. The diagnosis of CRAO was based on the initial ophthalmologist's clinical diagnosis, with documented visual disturbance due to retinal artery occlusion and evidence of a cherry red spot and attenuation of blood vessels on fundoscopic examination. Arteritic CRAO was excluded either clinically based on the presence of symptoms and the presence of an elevated ESR, or where possible, on temporal artery biopsy.

A single observer (AKR) extracted data from the case notes. Data collected included basic demographic details, comorbidities, timing of the initial presentation with CRAO, timing and type of ocular neovascularisation. Results from Doppler ultrasonography records and computer tomography angiography (CT-A) for patients with neovascularisation were recorded.

#### 3.3.1 Definitions

We define the term *neovascularization of the iris* (NVI) as the abnormal formation of new blood vessels on the anterior surface of the iris, with no associated elevation in intraocular pressure (IOP).

*Neovascularization of the disc* (NVD) was defined as the presence of abnormal new blood vessels on the optic disc, associated with early leakage on fundus fluorescein angiography. *Neovascular glaucoma* (NVG) was used to refer to

patients with NVI, proliferation of neovascular tissue over the angle, and an intraocular pressure (IOP) greater than 28 mmHg. We used the same threshold for an elevated IOP as another large case series.(78)

A haemodynamically significant carotid artery stenosis was defined as a carotid artery stenosis of greater than 70% according to either ultrasound or angiographic criteria.(79)

### 3.4 RESULTS

Thirty-three patients, mean age  $73\pm 9.7$  years, were identified as having thromboembolic CRAO. The vascular risk profile of this cohort has been previously reported.(80)

The prevalence of ocular neovascularisation was 18% (6/33). The mean age of this group was 77 (range: 57-85 years). Details are reported in Table 3.1. Five of these cases had NVI and each had progressed to NVG. Thus the point prevalence of NVG is 15% (5/33). One case had NVD detected on routine follow up at 2 weeks and confirmed on fundus fluorescein angiogram; neovascularization was not seen at the iris (NVI) or elsewhere .



Table 3.1: Cases of ocular neovascularisation

Case	NVI	NVG	Peak IOP (mmHg)	NVD	Time from onset of CRAO (weeks)	Ipsilateral carotid stenosis (Doppler US)	Vascular risk factors
1	not seen	absent	16	present	2	30-40%	hypertension, DM II, smoker
2	present	present	38	absent	16	50%	DM II
3	present	present	40	present	6	70%	hypertension, hyperlipidemia,
4	present	present	35	absent	6	20-40%	hypertension hyperlipidemia, DM II
5	present	present	36	present	16	<20%	hypertension, hyperlipidemia DM II
6	present	present	70	present	5	50%	hypertension, hyperlipidemia

Abbreviations: CRAO, central retinal artery occlusion; DM II, type II diabetes

mellitus; NVD, neovascularisation of the disc; NVI, neovascularisation of the iris;

NVG, neovascular glaucoma; US, ultrasound.

The mean time to diagnosis of neovascularisation in our cohort was 8.5 weeks, range 2 - 16 weeks. Cases 2 and 5 represented to an emergency ophthalmology clinic with ipsilateral eye pain (both at 16 weeks) and were diagnosed with NVG. In the remaining cases, diagnosis of neovascularisation was made at a scheduled review.

Atherosclerotic narrowing of the carotid vessels was evaluated in each case with Doppler ultrasound (*see* Table 3.1). An ipsilateral haemodynamically-significant carotid stenosis was documented in a single patient (case 3), who subsequently underwent an ipsilateral carotid endarterectomy. All cases were evaluated with a fundus fluorescein angiogram at the point NV was noted. There

were no choroidal filling defects to suggest involvement of the ophthalmic artery or the posterior ciliary artery.

Four patients with neovascular glaucoma post-CRAO had type II diabetes mellitus. In one case this was diagnosed after presenting with CRAO; one case was diet-controlled; both cases were managed with oral hypoglycaemic agents. No patients, however, had evidence of diabetic retinopathy in either ipsilateral or contralateral eye.

All patients underwent pan-retinal photocoagulation (PRP) as treatment for ocular neovascularisation. In case 2, persistently elevated intraocular pressure and chronic eye pain necessitated a trabeculectomy. In the remaining cases, a satisfactory reduction in IOP was observed following PRP with no pain and no further interventions were required.

### 3.5 DISCUSSION

Our series report an 18.2% prevalence of NV post CRAO in 33 eyes, with a mean time of onset at 8.5 weeks. A search for articles published since 1980 on the rate of NVI or NVG following CRAO found seven studies (Table 3.2).

Table 3.2: Incidence of NVI with/without NVG following CRAO

Study	<i>n</i> of eyes	Prevalence of NVI ± NVG	Timing	Methodology
Hayreh et al, 1982(77)	64 <sup>a</sup>	18.8% ( <i>n</i> = 12)	Range: on-presentation to 10 months	Retrospective case series (Study period unstated)
Duker et al, 1988(81)	168	16.7% ( <i>n</i> =28)	Mean 4 weeks; range 1 to 12 weeks	Retrospective case series (1977-1987)
Duker et al, 1991(78)	33	16.6% ( <i>n</i> = 6)	Mean 5.5 weeks. Range: 12days to 12 weeks	Prospective case series (18 month study)
Kattah et al, 2002(54)	19	31.6% ( <i>n</i> = 6) <sup>b</sup>	All cases within 31 days	Prospective case series (primarily evaluating thrombolysis, 1998-2000)
Schafer et al 2005(82)	27	18.5% ( <i>n</i> = 5)	Range: 2months - 2years	Retrospective case series (2 year study)
Hayreh et al 2009(76)	232 <sup>a</sup>	3.0% ( <i>n</i> = 7) <sup>c</sup>	Not stated.	Retrospective case series (1973-2000)
Sagong, et al 2009(75)	36	19.4% ( <i>n</i> = 7)	Range: 2-5 weeks (of the 3 cases described in detail)	Retrospective case series (2004-2008)

There is a wide variation in the reported prevalence from 3 to 28%. The median prevalence of these reported studies is 19%. This is consistent with the estimated point prevalence of NV in our own patient cohort. The majority of the reported studies, including our own, were retrospective. Duker et al., however, conducted an 18 month prospective cohort study examining the prevalence of neovascularisation and factors which may be attributable to its development and documented neovascularisation in 16.6% of cases.(78) This is similar to the prevalence reported in their larger retrospective cohort study of 168 eyes.

In our study, the mean time to neovascularisation was 8.5 weeks which is slightly longer than the 5.5 weeks found in a prospective study with fixed interval follow-up reviews following acute CRAO.(81) Nevertheless our study is in keeping

with previous data that suggests that neovascularisation tends to occur early following CRAO. The timing of neovascularisation in other studies is detailed in Table 3.2.

The optimal follow up regimen post CRAO has not been well defined, partly due to the unknown clinical course of the ocular complications. In contrast, NVG is a well recognised complication in people with central retinal vein occlusion (CRVO), and is sometimes referred to as “100 day glaucoma”.(82) Current guidelines recommend close follow up for patients with CRVO to measure IOP and investigate for NV, especially in the first 6 months (14). Our series, in keeping with other reported series, suggest that NV in CRAO occurs earlier and can be as early as 2 weeks.(72, 78) This suggests the need for close follow-up especially in the initial stages post CRAO. Early intervention with panretinal photocoagulation when NVD and NVI are detected might prevent NVG.

One of the problems inherent in the current literature relating to NV in CRAO is that the estimates of the point prevalence vary considerably. Some of this may be due to the differing definitions of NV, for instance some authors report the point prevalence of NVI as opposed to NVG. Similarly, in the definition of NVG, the upper threshold of an “elevated” intraocular pressure is not stated by many investigators; NVG often occurs in a continuum from NVI with the new blood vessels proliferation across in the drainage angle that then results in secondary reduction in aqueous drainage and hence elevated IOP.

The prevalence of neovascularisation at the disc is not a commonly recorded complication of CRAO. Duker et al. reported an incidence of 1.8% from a retrospective study of 168 patients with CRAO, and 3.0% in a prospective study of

33 patients.(78, 83) The observation of NVD in 12.2% NVD in our cohort is comparatively high. This may be a bias of small sample size, though it may represent underreporting in some studies secondary to follow-up methodology, or a variation secondary to the investigators' definition for NVD.

In our study, we observed a causal relationship between the CRAO and ocular NV based on the timing between the two events and the absence of other contributing factors to NV. In our study, in each of the 6 cases of ocular neovascularisation there were no concurrent clinical features of ocular ischaemia. Only one of six patients had a haemodynamically significant stenosis of the internal carotid artery and we could not see any evidence of ophthalmic artery ischemia based on fundus fluorescein angiograph at the time of neovascularization. There were four patients who had diabetes mellitus type II, but none had evidence of diabetic retinopathy in either eye.

### 3.6 CONCLUSION

In our cohort the overall rate of neovascularisation was 18.2%. Consistent with the majority of other studies, we have demonstrated a clear empirical correlation between thromboembolic CRAO and NVI. The majority (four of five) of cases of NVI progressed to NVG. In the majority of cases of neovascularisation there were no clinical features of ocular ischaemia, and no association with a haemodynamically-significant stenosis of the carotid artery. Given the association between neovascularisation and CRAO, prudent clinical practice would be to review all patients with acute CRAO at regular intervals as early as 2 weeks then monthly up to 4 months post CRAO.

### 3.7 CONTRIBUTION STATEMENT

The content of this chapter is published in :

Rudkin AK, Lee AW, Chen CS. Ocular neovascularization following central retinal artery occlusion: prevalence and timing of onset. Eur J Ophthalmol. 2010;20(6):15.

(Appendix 3)

I was the senior and corresponding author for the manuscript. I was responsible for the concept, drafting, revision and final approval of the manuscript; AKR was responsible for the data extraction and first draft of the manuscript; AWL provided statistical analysis and critical revision of the manuscript.

# **Chapter 4**

## **Managing systemic complications of a CRAO**

#### 4.1 PRECIS

The optimal management of a CRAO needs to address systemic atherosclerotic risk factors to reduce secondary ischemic events. I aimed to determine the proportion of patients presenting with thromboembolic central retinal artery occlusion (CRAO) who had undiagnosed vascular risk factors amenable to modification. This was performed by a retrospective audit of consecutive patients with non-arteritic/thromboembolic CRAO presenting between 1997 and 2008 to the Flinders Medical Centre. Thirty-three patients with non-arteritic CRAO were identified. Twenty-one patients (64%) had at least one new vascular risk factor found after the retinal occlusive event with hyperlipidemia being the most common undiagnosed vascular risk factor at the time of the sentinel CRAO event (36%). Nine patients had ipsilateral carotid stenosis of greater than 50%; six of these proceeded with carotid endarterectomy or stenting. One patient had significant new echocardiogram finding. A systemic ischemic event post-CRAO occurred in two patients with stroke and acute coronary syndrome. This study found that patients presenting with CRAO often have a previously undiagnosed vascular risk factor that may be amenable to medical or surgical treatment. As this population is at high risk of secondary ischaemic events, risk factor modification is prudent.



## 4.1 INTRODUCTION

Central retinal artery occlusion (CRAO) is defined as an occlusion of the central retinal artery usually by a fibrin-platelet thrombus or embolus with resultant reduced perfusion to the retina and painless visual loss that is frequently irreversible.(60)

CRAO by virtue of its pathogenesis shares important risk factors with other vascular diseases such as ischemic heart disease and cerebrovascular disease.(39) It is known from the study of heart disease and stroke, that following the occurrence of a sentinel vascular event, the patient is more likely to develop subsequent vascular events.(84, 85) Similarly CRAO may also be the harbinger of a more serious vascular event.(5, 86) The current management of CRAO is aimed at secondary prevention of another ischemic event.

My aim here was to quantify the pre-existing vascular risk factors in a cohort of patients with CRAO, and to determine the vascular risk factors amenable to modification following the CRAO event.

## 4.2 METHODS

An audit of a cohort of CRAO patients admitted to the Flinders Medical Centre between January 1997 and September 2008 was conducted. The diagnosis of CRAO was based on the initial ophthalmologist's clinical diagnosis with documented visual disturbance due to retinal artery occlusion, with evidence of a cherry red spot and attenuation of blood vessels on fundoscopic examination. Arteritic CRAO was excluded either clinically based on the presence of symptoms and the presence of an elevated ESR or where possible on temporal artery biopsy.

A single observer (AKR) abstracted data from the case notes. Data that were collected included demographic details, the prior medical history with a particular emphasis on the subject's previous risk factors such as hypertension, diabetes, hypercholesterolemia and the presence of atrial fibrillation as well as treatment that the patient had received both before and after the sentinel CRAO event. A haemodynamically-significant carotid artery stenosis was defined as a carotid artery stenosis of greater than 70% according to either ultrasound or angiographic criteria.(79) Information on revascularization procedures was also recorded. In addition, passive ascertainment was used to determine patient outcomes in the years following the initial event with particular emphasis on subsequent vascular events of either the retinal arteries or other vascular beds.

For the purpose of analysis, descriptive statistics were used. Continuous variables were expressed as a mean  $\pm$  standard deviation (SD) while dichotomous variables were expressed as a proportion or percentage.

#### 4.4 RESULTS

Thirty-three patients, mean age  $73 \pm 10$  years, 20 males, were reviewed with acute loss of vision due to CRAO.

##### 4.4.1 Vascular Risk Factors and Co-morbidities

Hypertension was the most common vascular risk factors in subjects with CRAO (Table 1), followed by hyperlipidemia. The diagnosis of these were based on documented past medical history recorded in the case notes. On average, most patients had  $2.4 \pm 1.6$  number of known vascular risk factors at the time of CRAO

diagnosis. Table 4.1 summarises the vascular risk factors present in our study population.

Table 4.1 : Vascular risk factors at the time of CRAO diagnosis

Vascular Risk Factors	At the time of CRAO diagnosis Number (%)
Hypertension	14 (42%)
Hyperlipidemia	12 (36%)
Tobacco use	12 (36%)
Family history of vascular disease	8 (24%)
Diabetes mellitus	7 (21%)
Atrial fibrillation *	3 (9%)
Cardiomyopathy or valvular disease # *	4 (12%)

\* Includes one patient with known atrial fibrillation and on warfarin, but whose international normalization ratio (INR) was subtherapeutic at the time of CRAO.

# Includes one instance of aortic stenosis, one of aortic insufficiency, one of congestive cardiac failure, one of moderate left atrial dilatation with atrial fibrillation.

At the time of CRAO diagnosis, five patients (15%) had already had an episode of amaurosis fugax and one had a branch retinal artery occlusion in the same eye (3%) prior to the CRAO event. Five patients (15%) had a history of stroke or transient ischaemic attack on the ipsilateral side and 12 (36%) had ischemic heart disease.

#### 4.4.2 Previously Undiagnosed Vascular Risk Factors and Treatment

Twenty-one patients (64%) had at least one new vascular risk factor found after the retinal occlusive event. Hyperlipidemia was the most common previously undiagnosed vascular risk factor at the time of the sentinel CRAO event, found in 12

patients (36%), followed by hypertension in 9 patients (27%), and diabetes mellitus in 4 patients (12%) (Table 4.2). Eighteen patients (55%) required either a new medication or upward titration of their dose.

Table 4.2 : Vascular risk factors found after the sentinel CRAO event

Vascular Risk Factors	After CRAO diagnosis
Hyperlipidemia	12 (36%)
Hypertension <sup>#</sup>	9 (27%)
Diabetes mellitus	4 (12%)
Atrial fibrillation	1 (3%)
Cardiomyopathy or valvular disease	1 (3%)
Hyperhomocysteinemia	1 (3%)
Renal artery stenosis (atherosclerotic)	1 (3%)

<sup>#</sup> Newly diagnosed hypertension or a blood pressure amenable to further reductions to achieve an ideal blood pressure.

In 2 instances, patients presenting with CRAO had more complex risk factors. The youngest patient, aged 50 years at presentation, had a history of hypertension, hyperlipidemia, and on further investigation was found to have elevated homocysteine levels. One patient had uncontrolled accelerated hypertension from underlying renal artery stenosis that was diagnosed after the CRAO event and subsequently referred to an internal medicine physician.

#### 4.4.3 Carotid Artery Disease and Cardiac diseases

Duplex doppler examination of the carotid arteries was performed on all patients. Five patients (15%) had significant carotid artery stenosis ( $\geq 70\%$ ) ipsilateral to the retinal occlusion; four proceeded with carotid endarterectomy, and one patient, because of perioperative risks, had carotid stenting (Table 4.3). Four patients (12%)

had moderate carotid narrowing (51-69%); one of these individuals, given recurrent ipsilateral ischemic symptoms, proceeded with carotid endarterectomy after consultation with a vascular surgeon and a stroke physician. All the carotid recanalization surgery was performed within 1 month of the sentinel CRAO event. One patient had an ipsilateral carotid endarterectomy prior to presentation with CRAO.

Table 4.3 : Summary of carotid artery disease and treatment

<b>Ipsilateral carotid artery stenosis</b>	<b>Number (%)</b>	<b>Number treated for carotid recanalization</b>
70-100% narrowing	5 (15%)	4 with carotid endarterectomy 1 with carotid stenting
50-69% narrowing	4 (12%)	1
< 50% narrowing	23 (70%)	0
Previous carotid surgery	1 (3%)	N/A

A transthoracic echocardiogram was performed in 29 of 33 patients (88%) to investigate possible cardio-embolic causes of retinal occlusion.(9) In one case, an echocardiogram revealed previously undiagnosed moderate left atrial enlargement associated with atrial fibrillation, which was then treated with oral anti-coagulation.

#### 4.4.4 Systemic vascular events in follow-up period

The average follow-up period in this study was 35±34 months (range 4-132). One patient (3%) experienced a stroke on the contralateral vascular territory five years later. One patient (3%) developed chest pain and shortness of breath eight months after the CRAO presentation. Subsequent investigation showed she had an anterior myocardial infarction and she was treated with angioplasty.

#### 4.5 DISCUSSION

Like stroke and ischemic heart disease, retinal ischemia due to CRAO is caused by a platelet fibrin clot or in rare instances, pure cholesterol emboli.(8) The ultimate source of these thrombi or emboli is atherosclerotic disease and thus the same risk factors that predispose to atherosclerotic disease are prevalent in patients with CRAO.(12) In our own cohort, hypertension was the most prevalent risk factor, a similar finding to a recent large case series of CRAO.(17) However a significant proportion of individuals also had carotid artery stenoses that were amenable to immediate carotid intervention, in addition to a proportion of individuals with 50 – 69% stenoses where carotid intervention is a potential treatment option.(87)

In addition to known risk factors documented prior to presentation of CRAO, there are also a significant number of individuals with previously undiagnosed vascular risk factors. In some individuals, escalation of existing anti-hypertensive medication or the addition of further vascular preventative medication was required. While it is not known whether the use of anti-hypertensives, anti-platelets or cholesterol lowering agents will reduce the risk of a subsequent CRAO based on definitive randomized controlled trials, such agents are accepted as standard clinical practice for the secondary prevention of stroke or ischemic heart disease.(88, 89) In our study, one patient developed a cerebral stroke following the CRAO and one patient developed symptoms related to ischemic heart disease. Therefore the presentation of a CRAO, while being rare given its overall incidence, nevertheless has significant associations with an increased subsequent incidence of vascular disease involving important end organs such as the brain and heart.

CRAO as a disease process is considered an ocular emergency, however treatment in the past has been limited by the lack of effective acute treatments supported by robust evidence.(18) This coupled with its low incidence has resulted in clinicians ignoring the potential for secondary prevention of further ocular ischemic events as well as stroke and heart disease. This is reflected by the fact that while there is voluminous guideline-level literature on the treatment of heart disease, stroke and peripheral vascular disease, equivalent literature is lacking for CRAO. Our audit of a prospective cohort of CRAO patients is important for two reasons. First it supports the existing literature that shows the presence of a significant burden of pre-existing vascular risk factors that are present prior to CRAO, headed by hypertension.(10, 17, 34, 90) In addition our study also shows that in a significant proportion of cases, the control of such risk factors is inadequate as 55% (18 of 33 patients) required either the addition or escalation of existing macrovascular preventative medications in the follow up period following CRAO. The second important aspect of this study is that it demonstrates that CRAO is not a benign disease but is a marker for subsequent vascular disease such as stroke and ischemic heart disease with known attendant significant morbidity and mortality. The fact that 6% of CRAO patients in our cohort went on to have a cerebral stroke mirrors in magnitude the risk of transient ischemic attacks (TIA) proceeding on to a completed stroke.(84) This calls for a need for aggressive pharmacotherapy for secondary prevention of an ischemic event. Referral to a dedicated vascular physician whether it be a stroke neurologist, cardiologist or internal medicine specialist would facilitate such therapy, in addition to ongoing ophthalmology input.

Not only is CRAO followed by ischemia in other organs but it is often preceded by warning symptoms of retinal ischemia. In our cohort, 18% of

individuals (6 of 33 patients) had either preceding symptoms of transient monocular blindness or evidence of branch retinal artery occlusion. Over half of patients (51%) also had previous end-organ ischemia such as ischemic heart disease or stroke. These sentinel events, if recognized early, afford the clinician not only the opportunity to prevent a CRAO, but by starting anti-platelets, anti hypertensive or cholesterol lowering agents also reduce the burden of subsequent disease in other vascular beds such as subsequent stroke or retinal artery occlusion.(17, 91, 92)

#### 4.6 CONCLUSION

A high proportion of patients presenting with CRAO often have an undiagnosed vascular risk factor. In this study, 64% of patients had at least one undiagnosed vascular risk factors and a significant proportion required either the addition or escalation of existing macrovascular preventative medications and 18% required surgical intervention for carotid recanalization. As this population is at high risk of secondary ischaemic events, risk factor modification is prudent to prevent further ischemic events.

#### 4.7 CONTRIBUTION STATEMENT

The content of this chapter has been published in the following peer-reviewed journal :

Rudkin AK, Lee AW, Chen CS. Vascular risk factors for central retinal artery occlusion. Eye (Lond). 2010;24:678-81 (Appendix 4)

I was the senior and corresponding author who was responsible for the concept, data analysis and interpretation, drafting, revision and final approval of the manuscript; AKR was responsible for the data extraction; AWL provided statistical analysis and critical revision of the manuscript.



# **Chapter 5**

## **New Treatment Option for Acute CRAO**

## 5.1 PRECIS

Several open-label clinical studies using continuous infusion of thrombolytic agents have suggested that local intra-arterial fibrinolysis (LIF) is efficacious in the treatment of an acute CRAO. The aim of the study presented here was to compare the visual outcome in patients with acute CRAO of presumed thromboembolic etiology treated with LIF administered in aliquots with that of patients treated with standard therapy. Twenty-one patients received LIF and 21 received standard therapy. Seventy-six percent of subjects in the LIF group had a visual acuity (VA) improvement of one line or more, compared with 33% in the standard therapy group ( $p=0.012$ , Fisher's exact test). Multivariate logistic regression controlling for gender, history of prior stroke/TIA, and history of hypercholesterolemia, showed that patients who received tPA were 36 times more likely to have an improvement in VA after adjusting for these covariates ( $p=0.0001$ ). Post-hoc analysis showed that patients who received tPA were 13 times more likely to have improvement in VA of three lines or more ( $p=0.03$ ) and 5 times more likely to have a final VA of 20/200 or better ( $p=0.04$ ). Two groin hematomas were documented in the LIF group. No ischemic strokes, retinal or intracerebral hemorrhages were documented. This shows that LIF administered in aliquots is associated with an improvement in VA compared with standard therapy and has few side effects, and is a potential treatment to optimize visual outcome in acute CRAO.

## 5.2 INTRODUCTION

Central retinal artery occlusion (CRAO), a cause of acute visual loss is seen in 1 per 10,000 ophthalmology outpatient visits.(42) The visual prognosis of CRAO often is poor, with 61% of patients having a final visual acuity of 20/400 or worse.(1) This degree of severe unilateral visual impairment is associated with limitations in social functioning, poor mental health,(3) and is a risk factor for becoming dependent.(4) Most CRAOs are thought to be caused by thrombosis or embolism.(6) Standard therapies for acute CRAO include ocular massage, paracentesis, and other methods of reducing intraocular pressure as well as inhalation of a mixture of 95% oxygen and 5% carbon dioxide (carbogen). These treatments have not been shown conclusively to improve visual acuity beyond the natural history of disease.(20, 64)

Systemic and intra-arterial thrombolysis have been successful in restoring perfusion to ischemic tissue by fibrin-platelet clot lysis in ischemic stroke and myocardial infarction.(49-51) In several open-label studies, local intra-arterial fibrinolysis (LIF) was shown to be efficacious in the treatment of CRAO, with up to 60-70% of treated subjects experiencing an improvement in visual acuity (VA).(39, 40, 52, 53, 56)

Most studies of LIF therapy in CRAO have used a continuous infusion of the thrombolytic agent.(52) Despite the efficacy of LIF in restoring VA in CRAO, concerns remain with its use in clinical practice. First, it is an invasive procedure that can cause embolic stroke and second, thrombolytic agents may result in either intracranial or systemic hemorrhages.(53, 55, 56)

An alternative to the continuous infusion of thrombolytic is its administration in small aliquots until patency of the central retinal artery is clinically established. There are two theoretical advantages of this approach. First, titration of the thrombolytic agent may result in a reduction in the total dose that is administered, thus potentially reducing the risk of hemorrhage. Second, the titration approach may reduce procedural time. Given that the duration of cerebral angiography is correlated with the risk of peri-procedural stroke, reduced angiography time might be expected to reduce the incidence of complications.(93-95)

We hypothesized that the treatment of acute CRAO with LIF administered in aliquots might achieve a better visual outcome than standard therapy alone and with a lower complication rate.

### 5.3 METHODS

We performed a retrospective analysis of a consecutive cohort of 42 patients admitted to the Johns Hopkins Hospital with acute CRAO from July 1999 to July 2006. All patients gave informed consent for the off-label use of tissue plasminogen activator (tPA) by intra-arterial administration.

All patients were assessed by an ophthalmologist who confirmed the diagnosis of acute CRAO using standard clinical criteria of monocular vision loss associated with an ipsilateral relative afferent pupillary defect and diffuse, pale swelling of the retina with a macular “cherry-red” spot and attenuation of retinal vessels by ophthalmoscopy.

VA at presentation was measured by Snellen chart at 20 feet for all patients whose VA in the affected eye was 20/400 or better. Patients with VA less than 20/400 in the affected eye were assessed on an ordinal categorical scale progressing from counting finger (CF), to hand movement (HM), to light perception (LP) and finally to no light perception (NLP). Fluorescein angiography was performed whenever possible. Demographic details and vascular risk factors on admission were recorded.

Two therapeutic procedures were compared in this study: standard therapy alone (control group), or LIF in addition to standard therapy (LIF group). The decision for a subject to undergo LIF was made by the treating ophthalmologist and neurologist if the patient was eligible.

The inclusion criteria for LIF were: 1) time to presentation of CRAO within 15 hours of symptom onset; 2) a presumed thromboembolic cause; 3) no evidence of vasculitis by clinical assessment or laboratory studies (e.g., erythrocyte sedimentation rate [ESR]); and 4) no evidence of hypoperfusion of the ipsilateral internal carotid artery as a cause of CRAO documented either angiographically or with duplex ultrasonography. Exclusion criteria included uncertain time of CRAO onset, a current or previous history of systemic hemorrhage within the last 3 months, brain imaging showing evidence of intracranial hemorrhage, clinical evidence of CRAO from giant cell arteritis, or inability to obtain subject consent.

Standard therapy of CRAO included ocular paracentesis, carbogen inhalation, topical intraocular pressure lowering agents, or a combination of these. All patients eligible for LIF underwent computerized head tomography (CT) or magnetic

resonance brain imaging (MRI) with a FLAIR sequence to exclude cerebral hemorrhage.

A diagnostic four-vessel angiogram was performed under local sedation to assess the intracranial vasculature, with an emphasis on the patency of the ipsilateral carotid and ophthalmic arteries. All angiograms and LIFs were performed by KM or PG. LIF was performed by advancing a guide catheter using a fluoroscopic roadmap of the internal carotid artery ipsilateral to the affected eye, following which 3000 units of heparin were infused to prevent peri-procedural thrombosis. A 1018 microcatheter (Boston Scientific, Natick, Massachusetts) steamed to the shape conforming to the ophthalmic artery siphon was then advanced to the origin of the ophthalmic artery and aliquots of 3mg tPA, in 3cc normal saline increments, were infused over 5 minutes each. Aliquot infusion was stopped if there was a clinical VA improvement, or a pre-specified maximum dose of 20 mg of tPA was reached, at which time the guiding and micro-catheters were removed. All patients were admitted to an intensive care unit and partial thromboplastin time (PTT) was measured every two hours. Once the PTT value had dropped below 1.5 times the normal value, an infusion of intravenous (IV) heparin was begun, without a bolus, using a weight-based nomogram. Once the therapeutic range of a PTT value of 1.5 to 2.5 times normal was reached the PTT was checked every 6 hours. The IV heparin infusion was stopped after 24 hours.(96) All adverse events were recorded.

In both standard and LIF groups, VA was assessed on day 1 post-procedure and then daily until discharge. The final VA for all patients was obtained from the patients' ophthalmologists for the most recent follow-up and the duration of follow-up recorded.

### 5.3.1 Outcome Measures

The primary outcome was defined as a one-line improvement in VA on the Snellen chart for patients with initial VA of 20/400 or better at 24 hours post admission. For patients with initial VA worse than 20/400, a improvement was considered to have occurred if VA improved from no perception of light (NPL) to light perception (LP), from LP to hand movement (HM), from HM to counting fingers (CF), and from CF to 20/400 or better at 24 hours following LIF.(39) Secondary outcomes included improvement in VA of three lines or more, signifying a doubling of visual angle (97) and achieving a VA of 20/200 or better, signifying the US definition for the cut-off for legal blindness.(98) Any adverse effects related to LIF were recorded.

### 5.3.2. Statistical Methods

Statistical analyses were performed with Stata statistical software, version 9.0 (StataCorp TX 2005). Univariate comparisons between baseline categorical characteristics in the two groups were made using Fisher's exact test. Comparisons between continuous characteristics were made using a Student's t-test, with adjustment for unequal variances when appropriate. Simple logistic regression was used to compare the primary outcome in the two groups, and multivariate stepwise logistic regression was performed including other covariates thought to be potential confounders. These variables were selected for clinical reasons or because they were found to have univariate associations with either the outcome or the use of LIF.

Although the initial analyses were performed using an automated stepwise comparison, subsequent decisions were made based on clinical importance, variables

with an adjusted p-value <0.10 (by likelihood ratio testing), those that moderately changed the point estimate for the primary variable of interest (LIF group), or those variables that were believed to be clinically significant despite non-significant p-values were included in the final model. Goodness of fit was assessed using the Hosmer-Lemeshow statistic. P-values for regression analyses were reported using likelihood ratio testing results. In addition, for analysis of the primary outcome, multinomial logistic regression was performed, with a 3-level outcome (worsening/no change/improvement in VA) and appropriate adjustment for potential confounders. Unless otherwise specified, an alpha < 0.05 was considered to be statistically significant.

## 5.4 RESULTS

### 5.4.1 Demographics and Vascular Risk Factors

Twenty-one subjects with a mean age of  $65 \pm 13$  years and  $57 \pm 15$  years were in each of the LIF and standard treatment groups, respectively. The demographic details were comparable between the two groups (Table 8). The most common vascular risk factor was systemic hypertension in 71% and 65% of the LIF and control groups respectively. There were no significant differences in the proportion of individual risk factors between the two groups. Two patients, one in each group, had ipsilateral carotid stenosis greater than 70% and underwent carotid endarterectomies subsequently.



Table 5.1 – Demographic Parameters in the LIF and control group

	<b>LIF group (n = 21)</b>	<b>Control group (n = 21)</b>	<b>p-value</b>
<b>Age</b> (mean±SD)	65.1 ± 13	56.6 ± 15	0.07
<b>Gender</b> (% male)	52.4%	33.3%	0.35
<b>Race</b>			0.31
Caucasian (%)	80.9%	61.9%	
African-American (%)	19.1%	33.3%	
Asian (%)	0	4.8%	
<b>Vascular risk factors at admission (%)</b>			
Hypertension	71.4 %	65.0 %	0.74
Diabetes mellitus	28.6%	23.8%	1.00
Hypercholesterolemia	28.6%	33.0%	1.00
Current smoker	28.6%	38.1%	0.74
Prior cerebrovascular events	28.6%	23.8%	1.00
Coronary artery disease			
Peripheral vascular disease	19.1%	19.1%	1.00
	4.8%	4.8%	1.00
<b><u>Mean time to presentation</u></b> <b>(mean ± SD hours)</b>	3.3 ± 2.0	25.8 ± 20	< 0.001*

Table 5.1: Baseline demographic characteristics, vascular risk factors and time to presentation of LIF and control groups. Continuous variables are expressed as a mean ± standard deviation (SD) and comparisons are made with a Student’s t-test. Dichotomous variables are expressed as a percentage of the total number of subjects, with a Fisher’s exact test used to compare differences between the groups.

\* Statistically significant at an alpha = 0.05.

The mean time between the onset of CRAO to presentation to an ophthalmologist or emergency room was 3.4±2.0 hours in the LIF group compared with 25.8±20 hours in the control group (95% CI: 13.5-31.4 hours; p<0.001.). In 76% of controls, time of presentation after 15 hours was the main reason for not receiving LIF. Six patients presented within 15 hours, but were not given tPA. Of these, two patients refused LIF treatment; two patients had significant medical co-

morbidities and were deemed unsuitable for LIF; and one patient had an elevated ESR, raising the clinical suspicion of giant cell arteritis. This patient underwent a temporal artery biopsy that was negative and thus is included in our analysis. Finally, one patient had an ipsilateral internal carotid artery occlusion on angiography and the micro-catheter could not be passed through the occlusion for LIF. These patients all received standard therapy.

The mean time from onset of visual loss to LIF was  $9.3 \pm 2.9$  hours. The mean time of the LIF procedure was  $96.3 \pm 28.3$  minutes. The mean dose of tPA was  $11.25 \pm 3.5$  mg.

#### 5.4.2 Visual Outcome

VA at presentation was 20/400 or worse in all patients. There was no statistically significant difference in the distribution of VA at presentation between the two groups using Fisher's exact test (Table 5.2).

Table 5.2 – Visual acuity at admission for the LIF and control groups.

<u>Initial acuity</u>	<b>LIF group (n=21)</b>	<b>Control group (n=21)</b>	
No light perception	4.8%	9.5%	p=0.31
Light perception	9.5%	23.8%	
Hand movement	47.6%	19.1%	
Count fingers	28.6%	28.6%	
20/800	0	9.5%	
20/400	9.5 %	9.5%	

In the LIF group, 71% experienced a 1 line or more of improvement in VA within 24 hours following completion of LIF compared with baseline versus 10% in the control group ( $p<0.001$ ). At final examination, 76% of subjects in the LIF group had an improvement in VA of 1 line or more (mean follow-up, 15 months) versus 33.3% in the control group (mean follow-up time, 11 months) ( $p=0.018$ ) (Table 5.3).

Table 5.3 – Visual Acuity Within 24 Hours Following LIF or Standard Therapy and at final examination

	LIF group (n = 21)	Control group (n = 21)	p-value
<b>Immediate vision change at 24 hours post admission</b>			
Visual improvement (by $\geq 1$ line)	71.4%	9.5%	$<0.001^*$
No change in vision	28.6%	71.4%	
Visual worsening (by $\geq 1$ line)	0%	19.1%	
<b>Vision change at final follow up</b>			
Visual improvement (by $\geq 1$ line)	76.2%	33.3%	0.018*
No change in vision	19.0%	38.1%	
Visual worsening (by $\geq 1$ line)	4.8%	28.6%	
<u>Follow-up time</u> (months $\pm$ SD)	15.2 $\pm$ 15.7	11.2 $\pm$ 13.1	

\*Statistically significant  $p<0.05$

Univariate logistic regression for the primary outcome showed that patients who received LIF were 6.4 times more likely to have an improvement in VA compared with the control group (95% CI 1.65-24.77,  $p=0.0045$ ). Adjusted analysis (including adjustment for gender, prior history of stroke/TIA, and history of hypercholesterolemia) yielded an odds ratio (OR) for an effect of LIF of 36.0 (95% CI: 3.09 - 417.6;  $p=0.0001$ ). We assessed for interaction between use of LIF and prior conservative measures, as well as between LIF and baseline acuity. No

significant interaction was found (OR 1.97, p=0.57 and OR 4.5, p=0.19 respectively).

Secondary analyses were performed using a 3-level outcome measure. The reference group was no change in visual acuity. Using the same set of covariates described in the multivariate model, subjects were 22 times more likely to experience improvement in VA and 86% less likely to experience worsening of VA if they received LIF (adjusted; p=0.0003). In addition, a history of hypercholesterolemia impacted negatively on visual outcome, although only in the adjusted models (adjusted OR = 0.10; 95% CI: 0.012 – 0.85, p = 0.02).

Table 5.4 : Multivariate logistic regression analysis with adjusted odds ratio for visual acuity improvement

Variable	Multivariate logistic regression with adjusted odds ratios (OR)
LIF	OR= 36.0, p=0.0001 *
History of elevated cholesterol	OR= 0.10, p=0.0195
Prior TIA or stroke	OR= 0.11, p=0.054
Female gender	OR= 0.08 , p=0.025

\*p<0.05

Multivariate stepwise logistic regression adjusting for gender, prior history of stroke/TIA and history of hypercholesterolemia showed that LIF was the most statistically significant factor associated with VA improvement.

A post hoc analysis was performed using a visual acuity improvement of 3 lines or more. One third of the group receiving LIF had an improvement of VA by 3 lines or more compared with 4.8% of the standard therapy group (p=0.018). On

multi-logistic regression analysis subjects undergoing LIF had a 13 times increased likelihood of achieving a VA improvement of 3 lines or more compared with those receiving standard therapy (OR=13, 95% CI: 1.2 – 145; p=0.03). In addition, subjects in the LIF group were 4.9 times more likely to have a final VA of 20/200 or better (OR 4.9, 95% CI : 1.05-23.4; p=0.04).

#### 5.4.3 Complications

Two patients in the LIF group had groin hematomas that resolved without long-term sequelae. No intracerebral, intraocular or orbital hemorrhages occurred in any patients in either group.

### 5.5 DISCUSSION

Patients with presumed thromboembolic CRAO have a poor visual outcome, with 78% having no spontaneous visual recovery.(1) Current standard therapies do not alter the natural history of disease whereby 0-30% may have spontaneous improvement.(1, 20, 65) In contrast, case series of patients with CRAO who undergo LIF report an improvement in final VA in 40 to 74% of subjects, and retrospective, non-randomized studies of LIF treatment in CRAO document an improvement of VA in 20-70% of LIF subjects.(39, 52, 99)

In our study, 71% of subjects in the LIF group had an improvement of VA within the first 24 hours and 76% at final examination. In contrast, 9.5% and 33.3% of patients in the standard therapy cohort experienced improvement in VA at 24 hours and final examination respectively. These point estimates are in keeping with previous studies and more importantly demonstrate a significant therapeutic

advantage over the proportion of subjects who have a VA improvement either spontaneously or with standard therapy alone.(1, 20, 65) This is reflected in the regression analyses where the use of tPA was associated with a 36-fold greater likelihood of recovery of VA versus standard therapy. In addition the benefit of tPA was also found using a more stringent outcome measure of an improvement in VA of 3 lines or more.

LIF is not without potential risk. Cerebral ischemia,(39, 53, 56) intracerebral hemorrhage,(55) and bleeding at the site of femoral catheterization have been documented.(53) The hemorrhage risk is related to the dose of thrombolytic, whereas the ischemic stroke risk may be related to the procedure duration.(93-95) Our study was unique in that we used a dose titration of tPA in aliquots until clinical improvement of CRAO occurred. Using this approach, the mean tPA dose of  $11.3\pm 2.5$  mg was smaller compared with a range of 30-70 mg of tPA used in previous studies.(39, 53, 55, 56) The duration of LIF of  $96.3\pm 28.3$  minutes was within the range of procedural times of 70-150 minutes previously cited.(39, 55)

An important consideration in determining the risk-benefit ratio of LIF in CRAO in regular clinical practice is the severity of adverse events. In contrast to thrombolysis in cerebral ischemia where the rate of hemorrhage varies from 3 to 20%, (49, 100, 101) there are no reports of intraocular hemorrhage to date. The thrombolytic-related intracranial hemorrhage risk, according to the myocardial infarction literature, is 1%.(51, 102)

The rationale for thromboembolic CRAO fibrinolysis is the assumption of a fibrin-platelet clot composition that may be thrombolytic-responsive. Criticism of

this assumption revolves around the fact that in one study of CRAO due to emboli, 57% (40/70) were found to be of the cholesterol type.(1, 36, 58) It is commonly thought that the site of occlusion in CRAO is at the level of the lamina cribrosa and as such is not visible on fundoscopic examination.(64, 103) The study by Arruga et al.(58) demonstrating the high proportion of patients with cholesterol emboli was a study of visible emboli and does not necessarily reflect the distribution of emboli types in CRAO. It thus does not invalidate the use of thrombolysis.

In internal carotid occlusion models of ischemic stroke in primates, relief of the occlusion results in recovery of cortical action potentials by salvaging cells in the ischemic penumbra.(104) Similarly, reperfusion after occlusion of blood flow in CRAO primate models also results in restoration of retinal and visual evoked potentials.(34, 35) These findings, and the observation in permanent CRAO of the presence of a sluggish retinal circulation on fluorescein angiography, suggests the presence of collateral blood supply and a retinal penumbra.(1, 36) Reperfusion of this retinal penumbra could explain the marked VA improvement following LIF.

A potential limitation of this study is its non-randomized nature that is subject to selection bias. In our study, the time to presentation was much shorter in the LIF group as compared to the standard therapy group. The fact that subjects arriving earlier were selected for LIF reperfusion therapy, compared with those who arrived later and were treated with standard therapy, could skew the results in favor of thrombolysis. Nevertheless, the point estimate of the efficacy of thrombolysis corresponds with previous studies and is above that of the rate of spontaneous recovery in CRAO.

Another limitation is the lack of fluorescein angiography and visual field assessment in all patients, making it impossible to subclassify our subjects with the same degree of detail as previous studies.(1) Although it is possible that the apparent efficacy of LIF in our study reflects the spontaneous recovery rate described in transient CRAO; transient CRAO comprise about 16% of all CRAOs.(1) We believe that the probability that we enrolled consecutive transient CRAO subjects in our LIF group is low and our sample likely reflect the majority of CRAO cases that are thromboembolic in origin.

#### 5.6 CONCLUSION

Our results support the hypothesis that the treatment of acute thromboembolic CRAOs with LIF administered in aliquots results in a better visual outcome than standard therapy alone, and has few complications. It is a biologically plausible therapy modeled on the treatment of similar conditions such as stroke and myocardial infarction. Nevertheless, because of the non-randomized nature of this and previous studies, LIF use cannot be recommended as standard therapy in daily clinical practice, pending the publication of randomized clinical trials.(105) Such a trial is already underway in Europe, and a further trial in North America may be warranted in the light of these findings.

#### 5.7 CONTRIBUTION STATEMENT

I am the co-first author for this manuscript published in Stroke (Impact factor 7.041, ERA ranking A).

Aldrich EM,\* Lee AW,\* Chen CS,\* Gottesman RF, Bahouth MN, Gailloud P, Murphy K, Wityk R, Miller NR. Local Intraarterial Fibrinolysis Administered in



Aliquots for the Treatment of Central Retinal Artery Occlusion. The Johns Hopkins Hospital Experience. Stroke. 2008; 39(6):1746-50. \*first authors contributed equally (Appendix 5)

I, in conjunction with Drs Eric Aldrich and Andrew Lee, wrote and revised the manuscript and was involved in collecting data for this study. EMA, AWL and CSC are thus acknowledged as having contributed equally in their roles as joint first co-authors in this manuscript

Dr Rebecca Gottesman performed the statistical analyses.

Ms Mona Bahouth collected the initial data.

Drs Gailloud and Murphy performed the interventional procedure for intra-arterial thrombolysis and wrote the methods section for the interventional procedures.

Dr Robert Wityk was involved in recruitment of subjects, study design and revising the manuscript.

Dr Neil Miller is the Senior Author and was integral in the conception of the study, implementation of the protocol and reviewed the overall manuscript.

# **Chapter 6**

## **Feasibility and time window of administering thrombolysis in acute CRAO**

## 6.1 PRECIS

Thrombolysis may improve visual outcomes in acute CRAO but a randomized controlled trial (RCT) was required to determine its efficacy. In planning such a study it was important to determine the proportion of individuals with CRAO who would present within an acceptable study time window to receive tPA and also to characterize potential causes of delayed presentation. The aim of the work described in this chapter was to ascertain, through audit, the timing and mode of presentation of individuals with potentially thrombolysable CRAOs. In this series, 31 patients with acute CRAO were identified who were treated at an Ophthalmology Department. The mean time from onset of vision loss to presentation was 31 hours  $\pm$  65 hours. Eighteen patients (58%) presented within 20 hours of vision loss, and the majority presented first to a general practitioner. Fifteen patients (48%) were reviewed by an in-hospital ophthalmologist within 20 hours of vision loss. The mean delay from the referring source to assessment by an in-hospital ophthalmologist was 5.2 hours (median 3.3 hours, range 50 minutes to 24 hours). This delay was, on average, shorter for patients referred directly to an ophthalmology clinic. This study showed that just under half of CRAO present to an in-hospital ophthalmologist within the 20 hour therapeutic time window for thrombolytic therapy and thus could qualify for inclusion in a randomised controlled trial.

## 6.2 INTRODUCTION

Central retinal artery occlusion (CRAO) is an acute occlusion of the central retinal artery (CRA) resulting in acute, painless monocular visual loss and is analogous to an ischemic cerebral stroke. Spontaneous recovery rates are poor, with less than 10% of all patients reporting a significant recovery of visual acuity (VA).(20, 65) Like cerebral ischemia, CRAO is caused by thrombi or emboli consisting of platelet fibrin material.(6) A number of recommended therapies for thromboembolic CRAO have been used in daily clinical practice, but a recent Cochrane meta-analysis found that they did not improve visual outcomes beyond the natural course of disease.(18)

Thrombolysis using tissue plasminogen activator (tPA) has been licensed for the treatment of acute cerebral ischaemia in a number of countries based on 2 pivotal randomized controlled trials of efficacy, (49, 106) supported by an ongoing prospective multi centre registry of effectiveness.(107, 108) There is evidence that tPA could also be used in the treatment of CRAO.(109) The main barrier to implementation is the absence of a randomized controlled trial confirming efficacy and the fact that most publications have centred around the intra-arterial delivery of thrombolytics.(109)

It is an accepted principle that the earlier reperfusion occurs in an ischemic end organ, the better the prognosis. In ischemic stroke, the shorter the delay between symptom onset and the administration of thrombolytic, the better the prognosis and the less chance there is of developing a symptomatic intracranial hemorrhage. While the time window for tPA use in ischemic stroke is well defined, tPA for CRAO has been deployed up to 24 hours of symptom onset. The European Assessment Group

for Lysis in the Eye (EAGLE) study has a time window of 20 hours for intra-arterial tPA use.(105) One of the limitations in conducting a randomized controlled trial of tPA in CRAO is its low incidence of 1 in 10,000 ophthalmic outpatient visits.(42) In planning such a study it would be important to determine the proportion of individuals with CRAO who would present within an acceptable study time window to receive tPA, and also to characterize potentials causes of delayed presentation.

In this paper, we presented an audit on the presentation of individuals with potentially thrombolysable CRAOs to our hospital. Specifically, we described the time-to-presentation, mode of presentation, and aimed to identify possible causes of delay.

### 6.3 METHODS

A retrospective audit of all patients diagnosed with acute CRAO referred to the Ophthalmology Department at the Flinders Medical Centre between January 1997 and July 2008 was performed.

All patients had CRAO confirmed clinically by an ophthalmologist. Patients with arteritic CRAO were excluded from the study using standard clinical criteria and investigations such as inflammatory markers and tissue pathology. Five patients in whom there was clinical and/or biochemical suspicion of giant cell arteritis underwent temporal artery biopsies, all of which were negative.

Data collected included age, gender, time of symptom onset, time-to-presentation, type of health provider at presentation (general practitioner, emergency department, optometrist or ophthalmologist), and the time interval between symptom

onset and in-hospital ophthalmologist review. Continuous variables are presented as a mean  $\pm$  standard deviation (SD).

#### 6.4 RESULTS

Thirty one patients were identified with acute loss of vision from CRAO. Their mean age was  $73 \pm 9.5$  years. The mean time from loss of vision to initial presentation to a health care provider was  $31 \pm 65$  hours (median 17, range 1.5 to 360 hours). The timing and initial health care provider are detailed in Table 1. Eighteen patients (58%) presented within 20 hours of vision loss, of which the 9 out of the 18 (50%) were first assessed by a general practitioner.

Table 6.1. Timing and Mode of Presentation of Patients with CRAO.

Initial Health Care Provider	Number of patients	Mean time from onset of vision loss to health provider consultation (hours $\pm$ SD)	Number presenting within 20 hours of vision loss (%)
General Practitioner	12	$13.4 \pm 10.7$	9 (75%)
Emergency Department	8	$13.1 \pm 11.9$	5 (63%)
Ophthalmologist	10	$71.0 \pm 111.0$	4 (40%)
Optometrist	1	24.0	0 (0%)
TOTAL	31	$31.2 \pm 65$	18 ( 58%)

Abbreviations: CRAO, central retinal artery obstruction; SD, standard deviation.

Ten patients were seen by an ophthalmologist following the acute visual loss. Three patients presented directly to an in-hospital ophthalmology clinic but seven were seen by an ophthalmologist in private practice outside a teaching hospital.

Table 6.2 : Analysis of referral pattern and referral detail to the in-hospital ophthalmologist from the initial health care provider

Initial Health Care Provider	Number of patients	Referred urgently within 24 hours	Number referred urgently who were within 20 hours of symptom onset	Number of patients seen within 20 hours of symptom onset by an in-hospital ophthalmologist	Mean delay from initial provider to in-hospital ophthalmologist (hours $\pm$ SD)	
General Practitioner	12	11	9	6	4.9 $\pm$ 6.3	
Emergency Department	8	8	5	5	5.3 $\pm$ 7.7	
Ophthalmologist	10	In-hospital 3	N/A	2	2	N/A
		Private practice 7	3	2	2	7.3 $\pm$ 13.6
Optometrist	1	1	0	0	4.0 $\pm$ 0	
TOTAL	31	23	18	15	5.2 $\pm$ 2.8	

N/A not applicable

Of the remaining 28 patients who were seen by a health care provider who is not an in-hospital ophthalmologist, the referral pattern showed that 23 out of the 28 were referred urgently within 24 hours. Analysis of the 5 that were referred non-urgently showed that 4 were from an ophthalmologist in private practice outside a teaching hospital and one from a general practitioner in a non-metropolitan region. The four patients from the ophthalmologists in private practice presented three or more days after the onset of symptoms and were hence referred non-urgently. The

patient from the non-metropolitan area was seen after one day, when transport arrangements were made.

Of the total study cohort, 15 (48%) reached an in-hospital ophthalmologist within 20 hours of symptom onset. The mean delay for urgent referral on the same day (n=23) from presentation to a health care provider until review by an in-hospital ophthalmologist was  $5.2 \pm 2.8$  hours (median 3.3 hours, range 50 minutes to 24 hours).

Of the 11 patients seen by a general practitioner who were referred urgently on the same day, three cases were referred directly to the in-hospital ophthalmologist. The mean delay in this group was shorter, being  $2.4 \pm 2.4$  hours (median 1.3 hours, range 1.0-6.0 hours). The rest were sent to the Emergency Department where they were then directed to the Ophthalmology Department.

## 6.5 DISCUSSION

Just under half (15/31, 48%) of our cohort of CRAO patients were reviewed by a hospital ophthalmologist within 20 hours of symptom onset and therefore could qualify for a thrombolysis trial based on time of symptom onset alone according to the EAGLE inclusion criteria.(105) CRAO patients were on the whole either seen by a general practitioner or an ophthalmologist as their first health practitioner and a large proportion of these could qualify for thrombolysis based on a 20 hour time window.

Time to intervention in CRAO is crucial. In animal models of total occlusion



of the retinal artery, complete recovery occurs if the occlusion is released within 97-100 minutes.(35) *In vivo* fluorescein angiography in humans suggest that occlusion of the central retinal artery is often subtotal, with some residual delayed flow from the incompletely occluded central retinal artery assisted by choroidal collaterals.(39) The presence of residual retinal tissue perfusion may be the mechanism whereby observational studies of thrombolysis suggest benefit even after 24 hours of visual loss.(39, 56)

The John Hopkins Hospital study excluded CRAO patients who presented at more than 15 hours after visual loss.(62) Seventy-six percent of patients receiving intra-arterial thrombolysis ( $n = 21$ ) compared to 33% of patients receiving standard therapy ( $n = 21$ ) had a visual acuity improvement of one or more lines on a Snellen chart ( $p = 0.018$ ). A retrospective case series performed by Richard *et al* investigated 53 patients (46 with CRAO and 7 patients with branch retinal artery occlusion) who were treated with intra-arterial thrombolysis.(56) The mean time to treatment was  $14 \pm 10$  hours. In 66% of patients, vision improved by at least one line on a Snellen chart. Schmidt *et al* did not have exclusion criteria in their retrospective cohort study, however the mean time to treatment for patients receiving intra-arterial thrombolysis was  $10.8 \pm 9.5$  hours and 58% of patients receiving thrombolysis demonstrated improvement in visual acuity, compared to 29% in the control group ( $p = 0.002$ ). (39) Subgroup analysis demonstrated that both the frequency and the extent of visual recovery was greater in patients who received thrombolysis within 6 hours, but noted that visual improvement was still observed in patients receiving treatment at more than 14 hours after visual loss.

A number of important aspects became apparent in this audit. First, the majority of referrals came from general practitioners (GP). One possible reason for this is the relative ease of obtaining an appointment in a GP clinic compared to an appointment in an ophthalmology clinic. In this study, only 3 patients (9.6%) were seen by an in-hospital ophthalmologist. In comparison to the study by Schmidt et al, 76.7% of retinal artery occlusions were seen within 24 hours in a university teaching hospital ophthalmology eye department.(61) This likely reflects a difference in the structure of the health care system between countries, as well as differences in infrastructure relating to patient education. Similar to the public education campaign for symptom recognition of heart attacks and acute stroke, if thrombolysis is proven to be a feasible and safe treatment option, public awareness must be raised of the symptoms and presentation, to aid early treatment.

Second, patients were assessed more quickly when they were referred directly to the in-hospital ophthalmologist compared to those who were referred to the emergency department first, then re-directed to the ophthalmology department. Education of primary care providers for prompt recognition of acute central retinal artery occlusion and potential management options, and the time window for effective treatment thus is important, and a pathway needs to be set-up for fast access to an in-hospital ophthalmologist. This issue of the rapid transfer of care to the specialist responsible for reperfusion therapy has been emphasized repeatedly in the stroke literature and often requires structural re-organization for rapid tPA delivery.(110) Such re-organization mandates the use of pre-hospital assessment tools for the rapid identification of stroke patients that would qualify for thrombolysis and couples this with the activation of a stroke response team according

to a set protocol.(111) For thrombolysis in CRAO to work, be it in standard clinical practice or a study situation, a similar set of protocols needs to be designed, or better still, CRAO as a disease needs to be on to the existing framework for thrombolysis in cerebral ischemia. Despite the absence of a rapid response CRAO protocol, just under half of our current CRAO population could be potential subjects for a thrombolysis study.

## 6.6 CONCLUSION

CRAO is an ocular emergency with no known effective therapies at present. Thrombolytic therapy with tPA shows promise, but requires confirmation in a randomized control trial in which a short time interval between symptom onset and treatment is crucial. This current audit demonstrates that just under 50% of CRAO patients were reviewed by a hospital ophthalmologist within the 20 hour time window for thrombolytic therapy and thus could qualify for inclusion in such a study. The most efficient way to prevent delays in therapy may be to add CRAO to existing stroke thrombolysis protocols, and emphasize the importance of collaboration between vascular neurology and ophthalmology specialists for such a randomized controlled trial to occur.

## 6.7 CONTRIBUTION STATEMENT

The content of this chapter is published in :

Rudkin AK, Lee AW, Chen CS. Central retinal artery occlusion: timing and mode of presentation. *Eur J Neurol.* 2009; 16:674-7. (Appendix 6)

I was the senior and corresponding author for the manuscript. I was responsible for the concept and design, drafting, revision and final approval of the

manuscript; AKR was responsible for the data extraction and first draft of the manuscript; AWL provided critical revisions of the manuscript.

# Chapter 7

**A randomized controlled  
clinical trial  
to assess the efficacy of  
intravenous thrombolysis  
in acute CRAO**

## 7.1 PRECIS

I designed and registered the first randomized controlled clinical trial to determine the efficacy of intravenous thrombolysis in acute treatment of central retinal artery occlusion (CRAO) {Australia and New Zealand Clinical Trial Registry 12608000441314 <http://www.ANZCTR.org.au/ACTRN12608000441314.aspx>}. It is a phase II, placebo-controlled, double blind, randomised controlled trial comparing intravenous tissue plasminogen activator at 0.9mg/kg to placebo (normal saline) 100 ml in a 1:1 block randomization. The primary outcome measure is an improvement of 3 lines or more on the Snellen visual acuity chart which signifies a doubling of the visual angle. The trial was terminated early due to a significant adverse event of an intracerebral hemorrhage in a patient given tPA. The Data Safety and Monitoring Committee called a review of the study. Analysis of the results showed that there was no difference in VA between placebo and tPA groups at 6 months. Subgroup analysis demonstrated that tPA administered within 6 hours of symptom onset had an improvement in visual acuity (mean logMAR improvement of -1.1). Therefore, the use of tPA, even in a radiologically normal brain, is not without risk of intracerebral hemorrhage and cannot be recommended in routine clinical practice pending further study of the optimal time window for intervention.

## 7.2 INTRODUCTION

Central retinal artery occlusion (CRAO) is an acute stroke of the eye, most commonly caused by an embolus or thrombus occluding the central retinal artery. This results in acute visual loss, occurring at a rate of 1 per 10,000 ophthalmology outpatient visits.(10). The visual prognosis of CRAO is poor with 61% of patients having a final visual acuity (VA) of 20/400 or worse.(1)

In acute CRAO, standard therapies include ocular massage, paracentesis, inhalation of a mixture of 95% oxygen and 5% carbon dioxide (carbogen) and other methods of reducing intraocular pressure. These treatments have not been shown to improve visual acuity beyond the natural history of disease.(18, 49, 64, 65)

Systemic thrombolysis has been successful in restoring perfusion to ischemic tissue by fibrin-platelet clot lysis in ischemic stroke and myocardial infarction.(49, 50) In several open-label studies, local intra-arterial thrombolysis using catheter angiography was efficacious in the treatment of CRAO, with up to 60-70% of treated subjects experiencing an improvement in visual acuity (VA).(40, 52, 53, 56, 112) From a clinical standpoint, the intra-arterial administration of thrombolytic would limit its availability to subjects presenting to hospitals that have highly specialized interventional neuro-radiology services. Furthermore, angiography is an invasive procedure that can occasionally cause embolic stroke. A recent randomized controlled trial using intra-arterial fibrinolysis in acute CRAO did not demonstrate the superiority of intra-arterial fibrinolysis over conservative standard therapy. Instead, there was a higher rate of adverse events including cerebral hemorrhage and as such, the authors concluded that intra-arterial fibrinolysis should not be used as a standard treatment for acute CRAO.(114)

An alternative route of administering thrombolytic is by *intravenous* injection. This has the advantage of being a non-invasive procedure with increased accessibility given an intra-arterial approach required the use of a neuro-radiology intervention service.(116) A systematic review of all observational studies of intravenous tPA in acute CRAO showed that 48.5% of subjects had a 4 lines or more visual acuity improvement with fewer complications when compared with intra-arterial administration.(59) Hattenbach et al. used low dose intravenous tPA in acute CRAO and noted that one third of cases (32%) had three or more lines of vision improvement and those treated within 6.5 hours had significantly better vision improvement.(70) The risk of intracerebral hemorrhage would be expected to be low given that concurrent cerebral stroke and CRAO is rare and thus cerebral vessels and parenchyma should be normal. Based on this assumption, the risk of hemorrhage should approximate 0.3% (95% CI 0.2-0.4), based on the more than 6000 patients in the GISSI-2 trial who received systemic tPA in myocardial infarction.(113) (117)

The optimal time window for treating an acute CRAO is unknown. In cerebral ischemic stroke, tPA is approved for treatment within 4.5 hours of symptom onset.(49) Animal models of CRAO have suggested that the retina can tolerate up to 97 minutes of ischemia before irreversible retinal damage occurs. Partial recovery was seen after ischemia of up to 240 minutes.(35) In most retrospective interventional case series, clinical improvement with tPA has been observed up to 12 hours after the onset of retinal ischemia.(39, 52, 54, 56, 112) Aldrich et al.(62) reported a prospective non-randomised study of intra-arterial tPA use in CRAO up to 15 hours from the onset of CRAO and 75% of tPA patients had visual acuity improvement. There were no cases of hemorrhage, locally or systemically amongst



the 21 patients. The European Assessment Group for Lysis in the Eye (EAGLE) study was designed in 2006 as a prospective randomised trial to assess the efficacy of intra-arterial thrombolysis within 20 hours of onset of acute CRAO to allow treatment within 24 hours.(105)

Given the convenience of intravenous delivery and the fact that the time window for thrombolysis in CRAO could extend to 24 hours, we hypothesized that intravenous tPA given within 24 hours of onset of CRAO would improve visual recovery compared with placebo as assessed by visual acuity. We therefore have designed and registered an open label, RCT to study the efficacy of intravenous tPA in CRAO (<http://www.ANZCTR.org.au/ACTRN12608000441314.aspx>). To our knowledge this is the first RCT of *intravenous* tPA in CRAO.

### 7.3 METHODS

#### 7.3.1 Design

An open label, phase II, proof of concept placebo controlled, randomised clinical trial of intravenous tPA in the treatment of CRAO.

#### 7.3.2 Patient Population - inclusion and exclusion criteria

##### *Inclusion criteria:*

- Age  $\geq$  18 years
- Acute CRAO within 24 hours of onset of symptoms (ie within 24 hours of last known time with normal vision)
- A presumed thromboembolic cause
- No evidence of temporal arteritis by clinical assessment or laboratory studies (e.g., erythrocyte sedimentation rate [ESR])

- No acute intra-cranial haemorrhage infarction or mass on non-contrast CT brain
- No ipsilateral carotid artery occlusion on CT angiography.

*Exclusion criteria:*

- A history of intracerebral haemorrhage at any stage
- A history of ischaemic stroke within the last 3 months
- A history of systemic haemorrhage within the last 3 months
- Inability to obtain informed consent
- Pregnancy
- Clinical, biochemical or imaging predictors of increased risk of intracerebral haemorrhage including:
  - Major surgery or trauma within 2 weeks
  - Gastrointestinal or urinary bleeding within 3 weeks
  - Arterial puncture or lumbar puncture within 7 days
  - A platelet count of  $<100 \times 10^9$  per liter
  - Heparin administered within the last 48 hours or vitamin K antagonist with an international normalised ratio (INR) of  $>1.6$
  - Systolic blood pressure of  $>185$  and diastolic blood pressure of  $>110$  mmHg
  - Serum glucose  $>22$  mmol/L

### 7.3.3. Randomization

Treatment were be randomized 1:1 in a block design via a website run by the co-ordinating centre at Flinders Medical Centre, Adelaide. A concealed print-out of treatment allocation were be passed to the administering nurse instructing the dose of

tPA or placebo to be prepared. The patient and assessing doctors remained blinded to treatment allocation to avoid bias.

#### 7.3.4. Treatment or intervention

Alteplase (Actilyse® Boehringer Ingelheim, GmbH, Germany) was administered intravenously according to the standard stroke unit protocol of 0.9 mg/kg (max 90 mg) with a 10% bolus given over 1-2 minutes, followed by 90% infusion over 1 hour. No antiplatelet or anticoagulants were given for 24 hours after tPA.

Clinical data collected included patient age, gender, vascular risk factors, medication list, visual acuity at presentation, ophthalmological and neurological findings, time from onset of symptoms to presentation, treatment received and visual outcomes. These data were entered via a secure website and the de-identified data transferred to the study co-ordinator in Adelaide.

Patients were admitted to a Stroke Unit and received standard investigations and management to address vascular risk factors. Participants were examined by an ophthalmologist blinded to treatment allocation on day one to document the visual acuity and some received a repeat visual field and fluorescein angiography prior to discharge from the Stroke Unit. All participants were followed up clinically and with computerised visual field assessment at 1 month, 3 months and 6 months in the neuro/ophthalmology outpatient clinic. The assessors remained blinded to treatment allocation.

All adverse events, in particular haemorrhagic complications, were documented at each visit and patient given access to the Principal Investigator of each participating centre at the Flinders Medical Centre, the Royal Victorian Eye and Ear Hospital/St. Vincent's Hospital Melbourne and Sydney Eye Hospital/St. Vincent's Hospital Sydney, to discuss any concerns. All serious adverse events (e.g. hemorrhage or allergic reaction) were reported immediately (within 24 hours) to the Data Safety and Monitoring Board (DSMB). The report of such an event triggered an immediate halt to the study and an analysis of results.

#### 7.3.5 Primary Outcomes

The primary outcome was improvement in Snellen visual acuity by greater than or equal to 3 lines between baseline and 6 months. This reflects a doubling of the visual angle and is a standard endpoint in clinical trials using visual function as a clinical endpoint.

#### 7.3.6 Secondary Outcomes

The secondary outcomes were mean improvement in Snellen acuity, mean deviation in visual field (dB) at 6 months and an exploratory analysis of the time course of visual recovery.

#### 7.3.7 Data Safety and Monitoring Body (DSMB)

The DSMB was based at Flinders Medical Centre Adelaide and comprised of independent members including a stroke physician, two emergency physicians, a stroke nurse practitioner and the chief pharmacist.

All serious adverse events (eg haemorrhage or allergic reaction) were to be reported immediately (within 24hours) to the DSMB, to trigger a review of the study. The results of this review were fed back to the Human Resource Ethics Committee (HREC) overseeing the study.

### 7.3.8 Sample Size

Biousse et al.(59) performed a meta-analysis of 103 cases of acute CRAO treated with intravenous thrombolysis. They found 48.5% had 3 lines or more of visual acuity improvement on reading the Snellen acuity chart. The “standard therapy” data demonstrated in the study by Aldrich et al.(62) showed that 4.8% of those treated with standard therapy achieved a 3-line or more of visual acuity improvement. Using the above figures (48.5% in treatment arm versus 4.8% in placebo arm), a sample size of 25 in each group was required to demonstrate an absolute difference of 43.7% in the proportion of subjects achieving a 3 line improvement in Snellen visual acuity with tPA compared to controls, at an alpha of 0.05 and power of 80%.

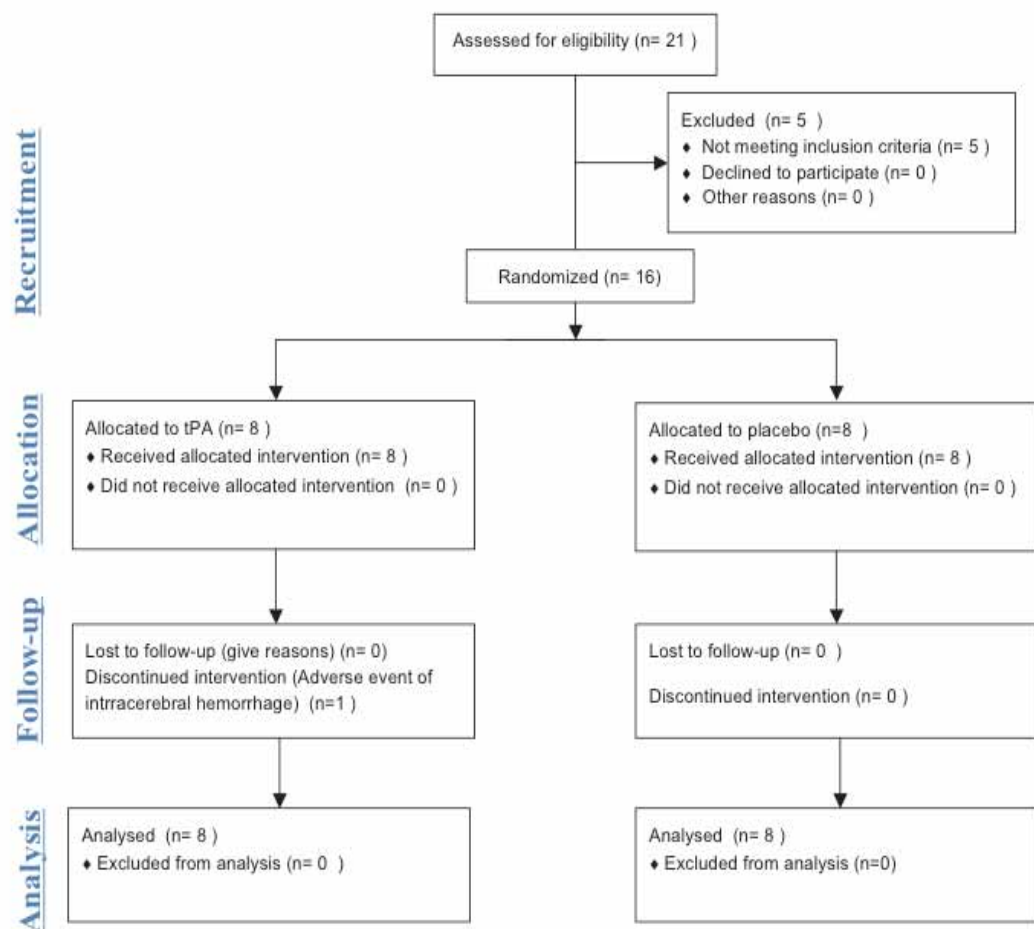
### 7.3.9 Statistical Analyses

Nonparametric techniques (Mann-Whitney U-test), were used to compare tPA and placebo groups on the primary outcome, as well as by pre-specified time stratification into 0-6 hour, 6-12 hour and 12-24 hour treatment time windows. The dichotomous variables were analyzed using Fisher’s exact test. Statistical significance was considered using an alpha = 0.05.

## 7.4 RESULTS

### 7.4.1 Study Patients

From July 1st 2008 to April 1st 2010, 21 subjects presented with acute CRAO and 16 were eligible for the study. All 16 subjects consented to be involved in the study. The mean age was 70±9 years. There were 11 men and 5 women. Fourteen patients were recruited from the Flinders Medical Centre, South Australia and 2 from the Royal Victorian Eye and Ear Hospital/St Vincent's Hospital, Melbourne, Victoria, Australia. Eight were randomized to intravenous tPA therapy and 8 received placebo consisting of an intravenous saline infusion. Five people with acute CRAO were referred but were ineligible for the study based on the exclusion criteria; two were on vitamin K antagonists with an INR above 1.7, one had suspected giant cell arteritis that was later confirmed with a temporal artery biopsy and in two subjects, the time of onset could not be determined. The patient flow is shown in Figure 7.1.



There were no significant differences between the mean age of the 2 groups, the gender distribution or vascular risk factors (Table 7.1). The baseline VA between

the groups were comparable with vision of counting finger or worse at presentation (p = 0.25). The mean time to presentation was 6.5±5.2 hours. Subjects who were assigned to the placebo group had a shorter mean time of presentation compared to the t-PA group (p=0.04). The average time from the onset of CRAO to the patient receiving a treatment was 10.8±6.1 hours from the onset. No patient in either the tPA or placebo group had neurological deficits prior to randomization (ie baseline NIHSS = 0 ).

Table 7.1 : Patient characteristics between the two groups.

Subject characteristics	t-PA (n = 8)	Placebo (n = 8)	P - value
Age (years)	73 ± 8	67 ± 9	0.18
Male (%)	6 (75%)	5 (62.5%)	0.59
Time to presentation (hours)	9.1 ± 6.1	3.9 ± 2.7	0.04 *
Time to treatment delivery (hours)	14.4 ± 6.5	7.3 ± 3.0	0.01*
NIHSS at randomization	0	0	
VA at baseline			0.25
NLP	0	1	
LP	0	2	
HM	5	4	
CF	3	1	
VA improvement by 3 or more lines at			
1 week	2 (25%)	0	1.00
3 months	0	0	
Adverse events			
ICH	1 (12.5%)	0	0.54
retinal hemorrhage	0	0	
systemic hemorrhage	0	0	
retinal NV	1 (12.5%)	1 (12.5%)	
death	0	0	

NIHSS National Institute of Health Stroke Score, NLP no light perception, LP light perception, HM hand movement, CF counting fingers, VA visual acuity, ICH intracerebral hemorrhage, NV neovascularization

#### 7.4.2 Visual Outcomes

At 1 week, 2 of the 8 patients (25%) who had received t-PA had an improvement in their VA of 3 lines or more. One patient improved from HM to 6/24 (log MAR 2.0 to 0.6) and another from CF to 6/36 (log MAR 1.6 to 0.8). There were no changes in VA in the other 6 patients receiving tPA. The mean change at 1 week was  $-0.275 \pm 0.53$  log MAR in the tPA group compared to  $0.05 \pm 0.14$  ( $p= 0.144$ ) in the control group.

The change in VA at 1 months and 3 months are shown in Table 3. There were no significant differences in the VA at 6 months between the tPA and placebo groups ( $p=0.535$ ).

Table 3 : Comparison of the mean Log MAR visual acuity between the two groups.

	Mean LogMAR Visual Acuity				
	Baseline	Change at 1 week from baseline	Change at 1 month	Change at 3 month	Change at 6 month
t-PA	$1.85 \pm 0.21$	$-0.275 \pm 0.53$	$-0.10 \pm 0.46$	$0 \pm 0.21$	$0.10 \pm 0.18$
Placebo	$2.2 \pm 0.44$	$0.05 \pm 0.14$	$0.05 \pm 0.14$	$0.05 \pm 0.14$	$0.05 \pm 0.14$
p – value	0.061	0.144	0.589	0.540	0.535

The patient whose vision went from HM to 6/24 at 1 week decreased to 6/38 (log MAR 0.8) at 1 month. At 3 months, the vision was counting fingers (log MAR 1.6) at the scheduled visit and a vitreous haemorrhage seen. The patient was asymptomatic. Fundus fluorescein angiography (FFA) showed retinal neovascularization. The other patient had initial improvement in vision and noted



sudden vision deterioration. Immediate ophthalmological examination showed no ocular hemorrhage and FFA showed delayed arterial filling. In both cases, there was a relatively short symptom to t-PA delivery time of 6 and 4.5 hours respectively. By contrast, none of the patients receiving placebo had an improvement of their VA.

Secondary outcome analysis of timing of presentation showed that only those presenting from 0-6 hours had VA improvement (Figure 7.2).

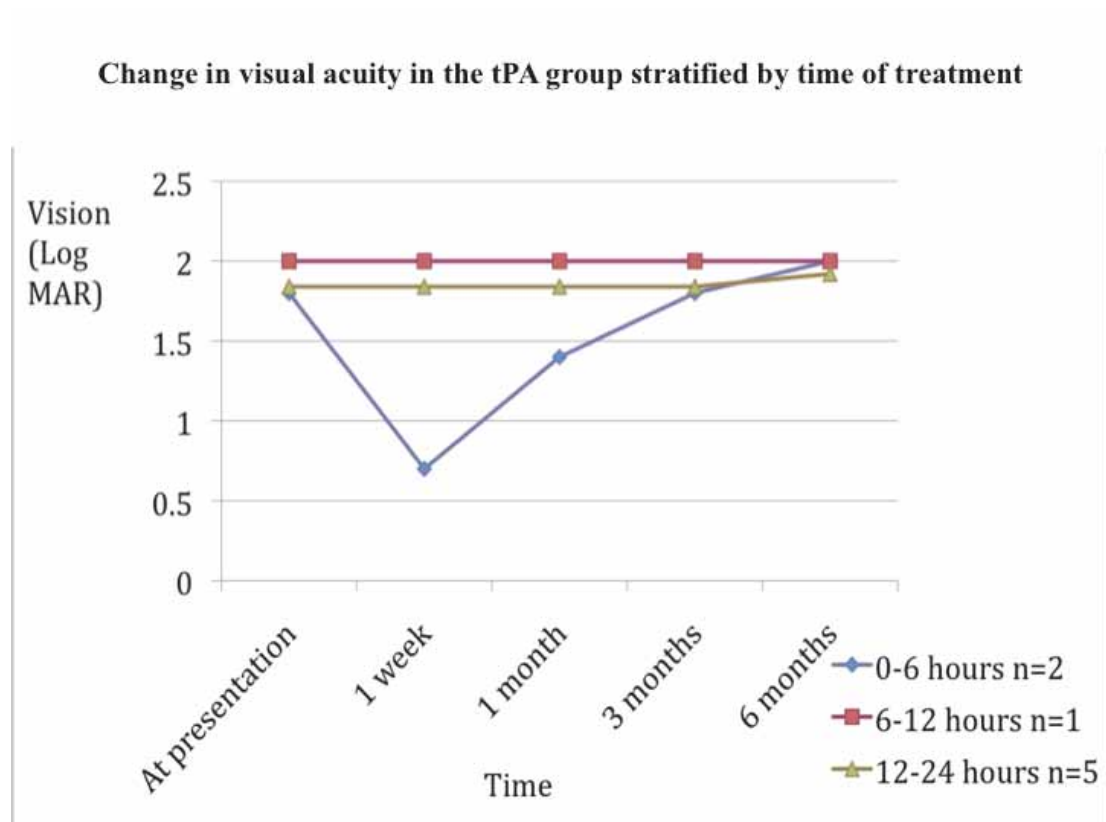


Figure 7.2 : Change in visual acuity (logMAR) of patients with acute CRAO treated with intravenous tPA stratified by time of treatment (0-6, 6-12 and 12-24 hours from the onset of CRAO).

#### 7.4.3 Safety and adverse effects

One subject had a serious adverse effect with an intracranial haemorrhage within 45 minutes of starting the t-PA infusion. The haemorrhage and subsequent

oedema were of sufficient severity to cause significant midline shift and he required intubation. He subsequently had a hemi-craniectomy and evacuation of the haematoma and was given pro-thrombinex and recombinant factor VII with a platelet infusion to reverse the effects of thrombolytic. He has made a good recovery with minimal right sided pyramidal deficits with a modified Rankin score of 2 on discharge. He had no recovery of vision from his CRAO.

There were no deaths and no retinal or systemic hemorrhages. Two patients developed neovascularization of the retina, including the patient who had vitreous hemorrhage with deterioration in vision at 3 months. The other patient received placebo treatment and had neovascularization of the disc seen at the 1 month review. The patient was asymptomatic and did not have increased intraocular pressure from neovascular glaucoma. Both were treated successfully with panretinal photocoagulation.

## 8.5 DISCUSSION

This study is the first randomized, controlled trial of intravenous t-PA versus placebo in the treatment of CRAO. Our results showed that the early improvement in VA of 3-lines or more seen in 2 subjects during the first week following t-PA was not sustained beyond 3 months. Thus the primary outcome measure of a 3-line or more improvement in VA at 6 months was not achieved. Nevertheless, our study does provide important information for the design of future trials in terms of the time window for intervention as well as giving a point estimate for potential adverse effects.

Previous human studies of CRAO have postulated that the time window for

intervention could extend to 24 hours.(105) The EAGLE study enrolled patients within 20 hours of symptom onset but did not show a significant change in visual function. This study concluded that local intra-arterial fibrinolysis should not be used in acute CRAO. Our study also demonstrated an overall lack of efficacy of thrombolysis, when using a 24 hour time window. In the sub-group analysis, 2 patients had significant improvement in VA when tPA was given within a 6 hour time window. This suggests that earlier treatment may result in better outcomes. This is comparable to the finding by Hattenbach et al. who showed a visual acuity improvement if tPA was administered within 6.5 hours of symptom onset. Whilst we agree with the EAGLE study that thrombolysis cannot be recommended as routine practice at present, review of the results suggest that it is not completely futile and possible subgroups may receive beneficial effect if an optimal time window can be defined.

This study was halted by the Data Safety And Monitoring Board for 2 reasons. First, there was no sustained improvement in VA in those patients receiving tPA compared with placebo. Second, one patient in the tPA group sustained a significant adverse event of an intra-cerebral hemorrhage (ICH) post tPA infusion. To date the point estimate of ICH post CRAO tPA treatment has been reported as low by virtue of the fact that the brain parenchyma is normal and concurrent ischemic stroke and CRAO rarely occurs.(113) The recent publication of the EAGLE study shows that thrombolytic use in CRAO is not without risk, with 2 of 42 (4.8%) of their lytic patients suffering an intracerebral hemorrhage and 1 of 42 (2.3%) experiencing a post-procedural haemorrhage and oral haemorrhage respectively.(114) Despite being of a young age (64 years) with no contraindications to thrombolysis (119) and with a normal brain on CT scan, a single tPA subject

developed an intracranial haemorrhage in our study. Thus if one were to consider all symptomatic forms of haemorrhage post tPA, the risk is 9.6% even if t-PA is delivered intra-arterially, as in the EAGLE study.

In our protocol, we used a standard stroke intravenous thrombolysis protocol of 0.9 mg/kg alteplase in the tPA group, up to a maximum dose of 90 mg, with anti-platelets medications such as aspirin administered 24 hours post infusion. This differs from the Hattenbach study that used a low-dose 50mg alteplase with 5 days worth of intravenous heparin and daily oral aspirin. There were no serious adverse events from their series.(70) In the intra-arterial fibrinolysis trials, the Johns Hopkins series utilized a lower intra-arterial tPA dosage averaging  $11.25 \pm 3.5$  mg with intra-procedural heparin therapy of 3000 units. There were no serious adverse reactions.(62) This is opposed to the 50 mg tPA dosage with 5000 units of heparin used in the EAGLE study and the hemorrhage rate as discussed above. This reflected the wide heterogeneity with the thrombolysis protocol for CRAO and the difficulty in comparing the results for recommended practice. In general, the lower tPA dosages reported to date have been associated with a lower serious adverse event rate. The use of the adjunctive therapy is not uniform and may also play a significant role in the differing results between various studies.

Our study showed initial statistically significant vision improvement in the intravenous tPA group but the result was not sustained. In the study by Hattenbach et al.,(70) the follow up period ranged from 1 to 4 months with a mean of 2.2 months. In our study, the vision improvement diminished after 3 months. It is a possibility that re-occlusion of the central retinal artery occurred. The size of the central retinal artery approximates that of subcortical cerebral blood vessels. In people with

subcortical stroke, arteriosclerotic risk factors place a person at increased risk of further vascular occlusion.(120) One patient who had an initial vision improvement from hand movement to 6/36 post tPA subsequently deteriorated at 1 week. The FFA performed at the time of the vision deterioration did not show any haemorrhage or emboli, but there was delayed arterial filling and a persistent cherry red spot. This suggests possible re-occlusion and raises the issue of optimal management of a thrombotic reocclusion and the importance of tight vascular risk factor control in CRAO.(80)

It is possible that newer generation thrombolytics that are more fibrin specific such as tenecteplase, could be more effective and reduce the risk of haemorrhage.(121) Fundus fluorescein angiography could potentially be used as a surrogate marker for retinal tissue at risk, in the same way that brain perfusion imaging in stroke gives one an idea of the volume of ischemic brain tissue that can be salvaged with reperfusion. These concepts require evaluation in future controlled trials.

In this study, whilst the primary outcome of this study was negative, it adds to the body of knowledge on the treatment of CRAO and direction for future studies. There are three areas that future studies will need to address. The first is a tighter time window of treatment, most possibly within 6 hours of CRAO onset. The second is the dosage of thrombolytic agents to achieve a positive benefit versus the risk of intracranial hemorrhage. The third is consideration of adjunctive therapies.

The main limitations of this study were the small sample size and the wide therapeutic time window used. The initial wide inclusion time window was selected

for pragmatic reasons of recruitment potential, as limited community awareness generally leads to late presentation. We have noted that the single most important enabler is an increase in awareness by the primary care provider (ophthalmologists in private practices, general practitioners, emergency physicians and optometrists) to contact the chief investigators directly. There is an average time delay of 5 hours from the time that a CRAO is confirmed to the time of treatment infusion. Given that "time is retina", streamlined referral and management pathways need to be created, analogous to those utilized in ischemic stroke and myocardial infarction.(122)

## 7.6 CONCLUSION

In conclusion, this study demonstrated the futility of intravenous tPA in CRAO using a 24 hour treatment window. It also demonstrated that the use of tPA, even in a radiologically normal brain, is not without risk. Subgroup analysis suggested that a beneficial effect of 3 lines or more of vision improvement could be seen if tPA was administered within 6 hours of CRAO onset. Future randomized controlled trials will need to test the efficacy and safety of IV tPA in the 0-6 hour treatment window. For now, the use of IV t-PA for the treatment of CRAO cannot be recommended in routine clinical practice.

## 7.5 CONTRIBUTION STATEMENT

The introduction and the methods section of this chapter forms the protocol paper that is in press with the International Journal of Stroke (Impact : 2.871)

Chen CS, Lee AW, Campbell B, Lee T, Paine M, Fraser C, Grigg J, Markus R, Williams KA, Coster DJ. Study of the efficacy of intravenous tissue plasminogen activator in central retinal artery occlusion. International Journal of Stroke.

Accepted for publication June 2010.

The results of the randomized controlled clinical trial is a manuscript currently in press with the journal Stroke (Impact factor 7.041, ERA ranking A), accepted for publication February 2011.

I am the primary and corresponding author for the manuscript. I was responsible for the design of the trial, the drafting and revision of the manuscript. Dr. Andrew W. Lee is the co-investigator for the trial at Flinders Medical Centre who was involved in the design and concept of the trial. Professors Keryn A. Williams and Doug J. Coster provided critical revision of the study and manuscript. Drs Bruce Campbell and Mark Paine are the investigators responsible for the patient care and recruitment at the Royal Victorian Eye and Ear Hospital and St. Vincent's Hospital Melbourne. Drs. Clare Fraser, John Grigg and Romesh Markus are the investigators responsible for the patient recruitment and care at Sydney Eye Hospital and St. Vincent's Hospital Sydney. Dr Tien Lee designed the computerized database for patient entry and randomization. All authors approved the final version of the manuscript.

# **Chapter 8**

## **Final Discussion**



## 8.1 INTRODUCTION

In this discussion, I will aim to address the relevance of the results according to the overall aim of the study : to optimize the management of acute central retinal artery occlusion. All results presented in this thesis will be discussed with specific reference to the current management, the results from the randomized controlled trial and future directions.

## 8.2 CURRENT MANAGEMENT OF ACUTE CRAO

The results from the review of current acute management from two tertiary teaching hospitals, the Flinders Medical Centre in Australia (FMC) and the Johns Hopkins Hospital (JHH) in the United States highlighted two issues. Firstly, there is no consensus on the best management for CRAO. Second, despite different practices in different institutions across the world, the visual prognosis of CRAO is poor, implying a lack of efficacy of current recommended therapies.

The current regimens for CRAO differs by institution and treating physician. In general, the management of acute CRAO at JHH was more intensive, with all patients managed as in-patients on the stroke unit. Those patients had more acute procedures such as paracentesis or ocular hypotensive therapies where the intent was to increase perfusion across the optic nerve head by reducing intra-ocular pressure. On the other hand, most FMC patients were managed as outpatients unless there were other reasons, such as social or concurrent medical conditions that required in-patient treatment. In general, there were few acute procedures performed in the FMC cohort. Despite these differences, there were minimal change in the visual outcome (log MAR  $1.97 \pm 0.77$  in JHH versus  $2.16 \pm 0.59$  in FMC cohort, equating to vision of hand movements in both groups.)

The most likely explanation for the lack of significant difference in the final visual acuity between our two cohorts is the lack of benefit of current standard interventions, compared with observation in this condition. This finding is consistent with other studies that have shown that paracentesis, ocular massage, and acetazolamide do not alter the natural history of disease.(20, 64, 65) Furthermore, the average number of standard non-thrombolytic interventions in this study (1.57 in JHH and 0.53 and FMC) was lower compared with the average number of  $2.5 \pm 1.4$  interventions described in the literature but the visual outcomes were comparable,(42) suggesting that current standard management options, whether single or in combination, do not alter visual outcomes. The use of current standard treatment thus remains at the discretion of the treating ophthalmologist.

### 8.3 OPTIMAL MANAGEMENT OF CRAO EXTENDS BEYOND THE EYE

#### 8.3.1. Managing ocular complications of CRAO

The eye is perhaps the only organ in the body that attempts to grow new blood vessels in response to ischemia. Unfortunately, the process of growing new vessels, called neovascularization (NV), is maladaptive and can result in an increased risk of intraocular hemorrhage and neovascular glaucoma. The consequences can be severe and often relentless leading to intractable eye pain.(72) Neovascularization is a commonly cited indication for enucleation . (73, 74)

The rate of ocular NV associated with CRAO varies from as low as 2.5% to as high as 31.6%.(54, 75). Due to this variability, a causal association between CRAO and ocular NV is debatable.(76) The management of this particular

complication is therefore haphazard and there is a lack of information on when and in which patients ocular NV will occur.

In our study a definite temporal relationship between CRAO and ocular NV was observed. In our cohort, the overall rate of NV was 18% and this is consistent with the median prevalence of all reported studies (19%). The mean time to developing NV was 8.5 weeks. In the majority of cases of neovascularisation, there were no clinical features of general ocular ischaemia, and no association with a haemodynamically-significant stenosis of the ipsilateral carotid artery. Given the association between NV and CRAO, prudent clinical practice would be to review all patients with acute CRAO at regular intervals as early as 2 weeks, then monthly up to 4 months post CRAO.

### 8.3.2 Managing systemic complications of CRAO

An important issue in managing a patient with acute CRAO is to deal with the predisposing vascular risk factors. CRAO is analogous to a stroke of the eye and thus these patients are at increased risk of other vaso-occlusive diseases such as cerebral stroke and ischemic heart disease. As such, the life expectancy in a patient with CRAO is 5.5 years after the sentinel event compared to 15.4 years in age-matched controls. In addition, the mortality in a CRAO patient is almost double that of age matched controls.(123) Six percent of CRAO patients in our cohort went on to have a cerebral stroke, which is the same order of magnitude of the risk of transient ischemic attacks (TIA) proceeding on to a completed stroke.(84) Therefore the presentation of a CRAO, while rare, nevertheless has serious implications associated with the increased incidence of vascular disease involving important end organs such as the brain and heart. Aggressive secondary prevention measures are thus needed.

In our cohort, a large proportion of patients with CRAO had underlying atherosclerotic risk factors, with hypertension being the most common condition. A significant proportion of individuals had carotid artery stenoses that were amenable to immediate carotid intervention. More importantly, a significant number of patients had previously undiagnosed vascular conditions. In some individuals escalation of existing anti-hypertensive medication or the addition of further vascular preventative medication was required. While it is not known whether the use of anti-hypertensives, anti-platelets or cholesterol-lowering agents will reduce the risk of a subsequent CRAO based on definitive randomized controlled trials, these agents are accepted as standard clinical practice for the secondary prevention of stroke or ischemic heart disease.(88, 89)

### 8.3.3 Recommendations for optimal management of CRAO

The optimal management of a CRAO is lacking at present in both the acute as well as chronic phase. Potential therapeutic options will be discussed in the next section. Based on the results from the systemic vascular risk factor reviews in Chapter 4, I would recommend a protocol for management of CRAO that includes :

#### **a. Investigations for vascular risk factors at the time of presentation**

- Blood pressure measurement
- Fasting blood sugar levels
- Fasting cholesterol and profile
- Carotid ultrasound
- Echocardiogram

In those with no conventional vascular risk factors, one should consider hypercoagulable and vasculitic screens including :

- Homocysteine level
- Protein C and S, Factor V Leiden mutation
- Antinuclear antibody (ANA), Extractable nuclear antigen (ENA), Antineutrophil cytoplasmic antibody (ANCA)

**b. Follow-up schedules**

- 2 weeks
  - to review investigation results and referral to appropriate ancillary specialities e.g. vascular surgeon if there are significant carotid stenosis that are amenable to recanalization.
  - check intraocular pressure and neovascularization.
- 4 weeks, 2 months and 3 months
  - check for neovascularization
- Thereafter management as appropriate, e.g. yearly if the patient is diabetic and requires a diabetic retinopathy check up.

8.4 POTENTIAL NEW THERAPEUTIC OPTIONS IN ACUTE CRAO

To optimize the management of central retinal artery occlusion, new therapeutic options need to be explored given the lack of efficacy of current standard treatments. Thrombolytics restore vessel patency and tissue perfusion via clot lysis. They are Federal Drug Administration-approved medications for tissue reperfusion in acute stroke and ischemic heart disease.(124) Thrombolysis, administered intra-arterially or intravenously, has shown potential in the treatment of acute CRAO in interventional case series.

In chapter 5, I described the outcome of an interventional case series comparing the visual outcome in 21 patients with acute CRAO treated with intra-

arterial thrombolysis compared with 21 patients treated with standard therapy. In the intra-arterial thrombolysis group, 71% of subjects had an improvement of visual acuity (VA) within the first 24 hours and 76% at final examination. In contrast, 9.5% and 33.3% of patients in the standard therapy cohort experienced improvement in VA at 24 hours and final examination respectively. Multivariate regression analyses showed that the use of tPA was associated with a 36-fold greater likelihood of recovery of VA versus standard therapy. The results supported the hypothesis that the treatment of acute thromboembolic CRAOs with intra-arterial thrombolysis results in a better visual outcome than standard therapy alone and has few complications. The European Assessment Group for Lysis in the Eye (EAGLE) was the first clinical trial to compare treatment outcomes of conservative standard treatment and local *intra-arterial* fibrinolysis (LIF) for acute non-arteritic CRAO (105). They concluded that LIF cannot be recommended as standard therapy in daily clinical practice (114). There are no randomized clinical trials looking at *intravenous* thrombolysis, which is less invasive than intra-arterial administration.

## 8.5 THE NEED FOR A RANDOMIZED CONTROLLED TRIAL TO ASSESS THE EFFICACY OF THROMBOLYSIS IN ACUTE CRAO

Randomized controlled trials (RCT) are lacking to help guide clinical recommendations. In the design for a randomized controlled trial, the following considerations come into play : mode of administration of the lytic agent, the time-window for intervention, and the adequacy of timely referral pathways.

### 8.5.1 Mode of administration

Thrombolytics can be administered intra-arterially or intravenously. The

intra-arterial route has the theoretical advantage that the drug is administered directly to the site of action for maximum efficacy. From a daily clinical practice stand point, the intra-arterial administration of thrombolytic would limit its availability to subjects presenting only to hospitals with highly specialized interventional neuro-radiology services. Furthermore, intra-arterial administration requires an invasive angiography procedure that can cause embolic stroke. Therefore a more accessible route of thrombolytic deployment needs to be examined.

Intravenous administration of thrombolytics is more expeditious and less invasive. It is the method used in current cerebral stroke reperfusion. A systematic review of all observational studies of intravenous tPA in acute CRAO showed that 48.5% of subjects had a 4 lines or more visual acuity improvement with fewer complications when compared with intra-arterial administration.(59, 109) Hattenbach et al. used low dose intravenous tPA in acute CRAO and noted that one third of cases (32%) had three or more lines of vision improvement and those where tPA was administered within 6.5 hours had significantly better vision improvement.(70) The risk of intracerebral hemorrhage would be expected to be low given that concurrent cerebral stroke and CRAO is rare.

#### 8.5.2 The time window for intervention

In the current RCT of IV tPA, the inclusion criterion is an acute CRAO within 24 hours of symptom onset. The potential time window for thrombolysis in CRAO is not known and debated. The initial wide time window was selected for pragmatic reasons. A retrospective analysis of presentations to the Flinders Medical

Centre with acute CRAO showed that patients tend to present late (31 hours  $\pm$  65 hours) and the majority presented first to a general practitioner. Only 3% of CRAO patients in our cohort were seen within 20 hours first presenting to a tertiary teaching hospital ophthalmology department. This is in contrast to the study by Schmidt et al in Germany, where 76.7% of retinal artery occlusions were seen within 24 hours in a university teaching hospital ophthalmology eye department.(125) This likely reflects a difference in the structure of the health care system between countries, as well as differences in education of patients. If thrombolysis becomes a feasible treatment option with the tighter time window, a public education campaign aimed at recognition that acute monocular vision loss is a possible symptom of central retinal artery occlusion, requiring prompt action, should be initiated. This would mirror similar campaigns in recognition of the symptoms of heart attack and acute stroke.

### 8.5.3 Referral pathways

Another important issue to consider from the results described in Chapter 6 on the mode and presentation of CRAO is that of a better referral pathway for use by the primary care providers. This issue of the rapid transfer of care to an end organ specialist responsible for reperfusion therapy has been emphasized repeatedly in stroke literature and often requires structural re-organization for rapid tPA delivery.(110) In the review on Chapter 6, I noted that patients were assessed more quickly when they were referred directly to the in-hospital ophthalmologist, compared to those who were referred to the emergency department first, then re-directed to the ophthalmology department. Education of the primary care providers of prompt recognition of acute central retinal artery occlusion and the potential management options and time window for treatment are important, and a pathway



needed for fast access to an in-hospital ophthalmologist needs to be established. Such re-organization mandates the use of pre-hospital assessment tools for the rapid identification of potential patients who would qualify for thrombolysis and couples this with the activation of a stroke response team according to a set protocol.(111) For thrombolysis in CRAO to work be it in standard clinical practice or a study situation, a similar set of protocols needs to be designed, or better still, CRAO as a disease is added on to the existing framework for thrombolysis in cerebral ischemia.

We have set the time window in our RCT to be 24 hours, similar to the EAGLE trial in Europe that recruited patients within 20 hours in order for treatment to be implemented within 24 hours(105). We recognize that the treatment effect size is likely to vary across the 24 hour inclusion window. The decision was made to allow a wide inclusion time given the recruitment consideration, but we planned for pre-specified subgroup analysis stratified by time to treatment (0-6hours, 6-12 hours and 12-24 hours).

#### 8.5.4 Recruitment centres

In the consideration for a design for a RCT, the main challenge is achieving sufficient numbers to power such a study. This is especially difficult given the incidence of acute CRAO is 1.3 to 1.9 per 100,000 population (126). Thus, even with an estimated sample size of 50 (25 in each the tPA and placebo groups), multi-centre recruitment was needed.

In planning the described multi-centre study, the following hospitals were approached as collaborators to participate (Table 8.1).

Table 8.1 : Participating centres and estimated recruitment number.

Hospital	Population served	Estimated acute CRAO per year
Sydney Eye Hospital as triaging/referral centre to : St Vincent's Hospital Sydney or Royal Prince Alfred Hospital, NSW	1,160,000	11
Royal Victorian Eye & Ear Hospital / St Vincent's Hospital Melbourne, Vic	3,000,000	30
Flinders Medical Centre	800,000	8

Allowing 50% attrition rate, an estimated 25 patients could be recruited per year and a 24 months recruitment process was planned to obtain the target sample size of 25 in each group.

#### 8.5.5 Other inclusion criteria considerations

Elderly patients (eg  $\geq 80$  years old) are often excluded from clinical trials. However with the aging population, elderly patients form an increasing proportion of the patients we treat. In this condition there is no indication that patient  $\geq 80$  years are particularly more at risk of adverse consequences of participation in the trial. In the stroke population, patients in their 80s and 90s are treated routinely with thrombolysis and the published data (largely non-randomised) suggest the benefits and risks approximate those of younger patients. We chose not to exclude elderly

patients, to improve the generalisability of the trial results.

## 8.6 RESULTS OF THE RANDOMIZED CONTROLLED TRIAL

The randomized controlled trial comparing the efficacy of intravenous tPA in acute CRAO within 24 hours of treatment showed no difference between the placebo and thrombolysis treatment group. In both groups, the final vision was that of hand movements. The study was completed just prior to the results of the EAGLE trial in Europe treating patients within 24 hours intra-arterially. The EAGLE trial was also a negative study that did not show efficacy (114). Although futility was demonstrated in both randomized controlled trials, several important lessons were gained from both studies.

The first is that the use of thrombolytics in acute CRAO is not without its risks. The point estimate of intracerebral haemorrhage post CRAO tPA treatment has been reported as low by virtue of the fact that the brain parenchyma is normal and concurrent ischemic stroke and CRAO rarely occur.(113) The recent publication of the EAGLE study shows that thrombolytic use in CRAO is not without risk, with 2 of 42 (4.8%) of their lytic patients suffering an intracerebral hemorrhage and 1 of 42 (2.3%) experiencing a post-procedural haemorrhage and oral haemorrhage respectively.(114) Thus, if one were to consider all symptomatic forms of haemorrhage post tPA, the risk is 9.6% even if t-PA is delivered intra-arterially as in the EAGLE study. Symptomatic intracerebral haemorrhage (ICH) occurs in approximately 2 % of tPA-treated ischemic stroke patients, with a case fatality of 50%. Thrombolysis for coronary artery disease with normal brain tissue is associated with a risk of intra-cerebral hemorrhage of 0.5% and is associated with significant neurological deficits. The occurrence of symptomatic ICH in one of the tPA treated patients in this study serves as a reminder that thrombolytic medications,

even in the setting of a normal brain CT, is not without risk. In addition, when one looks at the cost-benefit of tPA in this setting, clinicians must question the value of restoring sight as opposed to the potential morbidity and mortality associated with the use of the thrombolytic.

## 8.7 FUTURE DIRECTIONS

Whilst the RCT on the efficacy of intravenous tPA in CRAO at 24 hours yielded a negative result, review of the data suggests that it was not completely futile and that subgroups may receive a beneficial effect if an optimal time window can be established.

### 8.7.1. Time window for treatment

Closer analysis of the data raises the possibility that earlier treatment (perhaps <6 hours from onset) may be beneficial. The improvement in the sub-6 hour group with significant vision improvement was more than by chance alone and the two patients' results accounted for the significant change for the overall group. This result is comparable to the case series reported by Hattenbach et al.,(70) where visual recovery was confined to those treated within 6.5 hours.

Future studies should aim for the sub-6 hour presentation. This would be similar to the stroke thrombolysis trials where the efficacy was first established in those who presented within 3 hours, then the window for treatment was extended to 4.5 hours with the aid of imaging guidance.

### 9.7.2 Thrombolytic agents and adjuvant therapy

A review of the thrombolytic trials in CRAO showed significant variability in the use of thrombolytic agent dosage and adjunctive therapies. The following table is a summary of the treatment protocols in recent interventional case series and the two RCTs, including our study and the haemorrhagic complications (Table 8.2).

Table 8.2 : Summary of thrombolysis trials in CRAO

Authors (Year)	Route	Dosage	Thrombolytic agent	Therapeutic window	Adjunctive therapy	Haemorrhagic complication
Chen et al. (2010)	Intravenous	0.9 mg/kg (max 90 mg)	Actilyse	24 hours	Anti-platelet	Intracerebral hemorrhage (1/8, 12.5%)
Schumacher et al. (2010)	Intra-arterial	Max 50mg	Actilyse	20 hours	Heparin 5000 Unit stat + 5 days Aspirin 100mg/day	Intracerebral hemorrhage (2/35, 5.7%)
Zhang et al. (2009)	Intravenous	Averaged 626,000 U	Urokinase	6 hours	Aspirin 300 mg/day or clopidogrel 250 mg/day	Retinal hemorrhage (2/49, 4.1%)
Hattenbach et al. (2008)	Intravenous	50mg	Actilyse	12 hours	Heparin 1200 U/hr for 5 days Aspirin 100mg/day	Nil
Aldrich et al. (2008)	Intra-arterial	Average 11.25±3.5 mg	Actilyse	15 hours	3000 U Heparin intra-procedural	Groin hematoma (2/21, 9.5%)
Arnold et al. (2005)	Intra-arterial	Average 677 000 units	Urokinase	6 hours	Heparin (dosage and duration not specified) Aspirin 250-500 mg/day	Cerebrovascular accidents (3/37, 8.1%)
Pettersen et al. (2005)	Intra-arterial	10-20 mg	Actilyse	6-18 hours	Nil	Nil

CBE complete blood examination, ESR erythrocyte sedimentation rate, CT computerized tomography, CRP C-reactive protein, MRI magnetic resonance imaging

The use of heparin and aspirin varied depending on the protocol. In our study, re-occlusion appeared to be an issue. This was illustrated specifically by the

patient who had an initial vision improvement from hand movement to 6/36 post tPA, but who subsequently deteriorated at 1 week. The FFA performed at the time of the vision deterioration did not show any haemorrhage or emboli, but there was delayed arterial filling and a persistent cherry red spot. This suggests possible re-occlusion. The size of the central retinal artery approximates that of subcortical cerebral blood vessels. In people with subcortical stroke, arteriosclerotic risk factors place a person at increased risk of further vascular occlusion.(120) This raises the issue of optimal management in the event of thrombotic reocclusion, and if the heparin and anti-platelet prophylaxis hold the key for optimal management for recanalization post CRAO.

Further studies are required to determine the optimal acute management of CRAO with the consideration of a tighter time window and adjuvant therapy. For now, the use of IV t-PA for the treatment of CRAO cannot be recommended in routine clinical practice and the best management of CRAO involves limiting the ocular neovascular complications and optimizing the systemic atherosclerotic risk factors to reduce secondary ischemic events to prevent further ischemic end organ damage.

## **BIBLIOGRAPHY**

1. Hayreh SS, Zimmerman MB. Central Retinal Artery Occlusion: Visual Outcome. *Am J Ophthalmol* 2005;140(3):376-381.
2. Hayreh SS. The 1994 Von Sallman Lecture: the optic nerve head circulation in health and disease. *Exp Eye Res* 1995;61:259-72.
3. Chia EM, Mitchell P, Rochtchina E, Foran S, Wang JJ. Unilateral visual impairment and health related quality of life: the Blue Mountains Eye Study. *Br J Ophthalmol* 2003;87(4):392-5.
4. Vu HTV, Keeffe JE, McCarty CA, Taylor HR. Impact of unilateral and bilateral vision loss on quality of life. *Br J Ophthalmol* 2005;89(3):360-3.
5. Recchia FM, Brown GC. Systemic disorders associated with retinal vascular occlusion. *Curr Opin Ophthalmol* 2000;11:462-7.
6. Duker JS. Retinal artery obstruction. In: Yanoff M, Duker JS, Augsburger JJ, editors. *Ophthalmology*. Second ed. St Louis: Mosby; 2004.
7. Mangat HS. Central retina artery occlusion. *Surv Ophthalmol* 1995;40(2):145-56.
8. Babikian V, Wijman CA, Koleini B. Retinal ischemia and embolism, etiologies and outcomes based on a prospective study. *Cerebrovasc Dis*. 2001;12:108-13.

9. Lorentzen SE. Incidence of cilioretinal arteries. *Acta Ophthalmol (Copenh)*. 1970;48:518-24.
10. Rumelt S, Brown GC. Update on treatment of retinal arterial occlusions. *Curr Opin Ophthalmol* 2003;14(3):139-41.
11. Savino PJ, Glaser JS, Cassady J. Retinal stroke. Is the patient at risk? *Arch Ophthalmol* 1977;95(7):1185-9.
12. Wong TY, Klein R. Retinal arteriolar emboli: epidemiology and stroke risk. *Curr Opin Ophthalmol* 2002;13(3):142-6.
13. Biousse V. Cerebrovascular disease. In: Miller NR, Newman NJ, Biousse V, Kerrison JK, editors. *Walsh and Hoyt's Clinical Neuro-Ophthalmology*. Philadelphia: Lipincott, Williams and Wilkins; 2005. p. 1967-2168.
14. Schmidt D, Hetzel A, Geibel-Zehander A. Retinal arterial occlusion due to embolism of suspected cardiac tumors -- report on two patients and review of the topic. *Eur J Med Res* 2005;10(7):296-304.
15. Sharma S, Sharma SM, Cruess AF, Brown GC. Transthoracic echocardiography in young patients with acute retinal arterial obstruction. RECO Study Group. Retinal Emboli of Cardiac Origin Group. *Can J Ophthalmol* 1997;32(1):38-41.



16. Mokhtari F, Massin P, Paques M, Biousse V, Houdart E, Blain P, et al. Central retinal artery occlusion associated with head or neck pain revealing spontaneous internal carotid artery dissection. *Am J Ophthalmol* 2000;129(1):108-9.
17. Schmidt D, Hetzel A, Geibel-Zehender A, Schulte-Mönting J. Systemic Diseases in Non-inflammatory Branch and Central Retinal Artery Occlusion. An Overview of 416 Patients. *Eur J Med Res* 2007;12(12):595-603.
18. Fraser S, D S. Interventions for acute non-arteritic central retinal artery occlusion. *Cochrane Database of Systematic Reviews* 2002;1:CD001989.
19. Ffytche TJ. A rationalization of treatment of central retinal artery occlusion. *Trans Ophthalmol Soc U K* 1974;94(2):468-79.
20. Atebara NH, Carter GC, Cater J. Efficacy of anterior chamber paracentesis and carbogen in treating acute nonarteric central retinal artery occlusion. *Ophthalmology* 1995;102:2029 - 35.
21. Wenzler EM, Rademaker AJ, Boers GH, Cruysberg JR, Webers CA, Deutman AF. Hyperhomocysteinemia in retinal artery and retinal vein occlusion. *Am J Ophthalmol* 1993;115(2):162-7.
22. Betram B, Remky A, Arend O, Wolf S, Reim M. Protein C, protein S, and antithrombin III in acute ocular occlusive diseases. *Ger J Ophthalmol.* 1995;4:332-5.
23. Rumelt S, Rehany U. Central retinal artery occlusion associated with primary antiphospholipid syndrome. *Eye.* 1999;13:699-700.

24. Liem RI, Calamaras DM, Chhabra MS, Files B, Minniti CP, Thompson AA. Sudden onset blindness in sickle cell disease due to retinal artery occlusion. *Pediatr Blood Cancer*. 2007:E-pub ahead of print.
25. Cohen RJ, Hedges TRr, Duker JS. Central retinal artery occlusion in a child with T-cell lymphoma. *Am J Ophthalmol*. 1995;120(1):118-20.
26. Chawluk JB, Kushner MJ, Bank WJ, Silver FL, Jamieson DG, Bosley TM, et al. Atherosclerotic carotid artery disease in patients with retinal ischemic syndromes. *Neurology*. 1988;38(6):858:63.
27. Costello F, Gillberg S, Karsh J, Burns B, Leonard B. Bilateral simultaneous central retinal artery occlusions in wegener granulomatosis. *J Neuroophthalmol*. 2005;25:29-32.
28. Lee DH, Yang HM, Kim JC, Shyn KH. Sudden unilateral visual loss and brain infarction after autologous fat injection into the nasolabial groove. *Br J Ophthalmol*. 1996;80:1026-7.
29. Egbert JE, Schwartz GS, Walsh AW. Diagnosis and treatment of an ophthalmic artery occlusion during intralesional injection of corticosteroid into an eyelid capillary hemangioma. *Am J Ophthalmol*. 1996;121:638-42.
30. Grossman W, Ward WT. Central retinal artery occlusion after scoliosis surgery with a horseshoe headrest. Case report and literature review. *Spine*. 1993;18(9):1226-8.

31. Bekar A, Tureyen K, Aksoy K. Unilateral blindness due to patient positioning during cervical syringomyelia surgery: unilateral blindness after prone positioning. *J Neurosurg Anesthesiol.* 1996;8(3):227-9.
32. American-Society-of-Anesthesiologists. Practice parameters: perio-operative visual loss associated with spine surgery. *Anesthesiology.* 2006;104:139-1328.
33. Vinerovsky A, Rath EZ, Rehany U, Rumelt S. Central retinal artery occlusion after peribulbar anesthesia. *Journal of Cataract & Refractive Surgery.* 2004;30(4):913-5.
34. Hayreh SS, Zimmerman MB, Kimura A, Sanon A. Central retinal artery occlusion. Retinal survival time. *Experimental Eye Research.* 2004;78:723-36.
35. Hayreh SS, Kolder HE, Weingeist TA. Central retinal artery occlusion and retinal tolerance time. *Ophthalmology.* 1980;87:75 - 8.
36. Hayreh SS. Prevalent misconceptions about acute retinal vascular occlusive disorders. *Progress In Retinal and Eye Research.* 2005;24:493-19.
37. Augsburger JJ, Magargal LE. Visual prognosis following treatment of acute central retinal artery occlusion. *Br J Ophtalmol.* 1980;64(12):913-7.
38. Connolly BP, Krishnan A, Shah GK, Whelan J, Brown GC, Eagle RC. Characteristics of patients presenting with central retinal artery occlusion with and without giant cell arteritis. *Can J Ophthalmol.* 2000;35(7):379-84.

39. Schmidt DP, Schulte-Monting J, Schumacher M. Prognosis of central retinal artery occlusion: local intraarterial fibrinolysis versus conservative treatment. *AJNR Am J Neuroradiol.* 2002;23(8):1301 - 7.
40. Beatty S, Au-Eong KG. Local intra-arterial fibrinolysis for acute occlusion of the central retinal artery: a meta-analysis of the published data. *Br J Ophthalmol.* 2000;84:914 - 6.
41. Rosser DA, Cousens SN, Murdoch IE, Fitzke FW, Laidlaw DA. How sensitive to clinical change are ETDRS logMAR visual acuity measurements? *Invest Ophthalmol Vis Sci.* 2003;44(8):3278-81.
42. Rumelt S, Dorenboim Y, Rehany U. Aggressive systematic treatment for central retinal artery occlusion. *American Journal of Ophthalmology.* 1999;128(6):733-8.
43. Harino S, Grunwald JE, Petrig BJ, Riva CE. Rebreathing into a bag increases human retinal macular blood velocity. *Br J Ophthalmol.* 1995;79(4):380-3.
44. Deutsch TA, Read JS, Ernest JT, Goldstick TK. Effects of oxygen and carbon dioxide on the retinal vasculature in humans. *Arch Ophthalmol.* 1983;101(8):1278-80.
45. Incandela L, Cesarone MR, Belcaro G, Steigerwalt R, De Sanctis MT, Nicolaides AN, et al. Treatment of vascular retinal disease with pentoxifylline: a controlled, randomized trial. *Angiology.* 2002;53(supp1):S31-4.

46. Beiran I, Goldenberg I, Adir Y, Tamir A, Shupak A, Miller B. Early hyperbaric oxygen therapy for retinal artery occlusion. *Eur J Ophthalmol.* 2001;11(4):345-50.
47. Rassam SM, Patel V, Kohner EM. The effect of acetazolamide on the retinal circulation. *Eye.* 1993;7(5):697-702.
48. Landa E, Rehany U, Rumelt S. Visual functions following recovery from non-arteritic central retinal artery occlusion. *Ophthalmic Surg Lasers Imaging.* 2004;35(2):103-8.
49. NINDS. Tissue Plasminogen Activator for Acute Ischemic Stroke. *N England J Med.* 1995 December 14, 1995;333(24):1581-8.
50. Furlan A, Higashida R, Wechsler L, Gent M, Rowley H, Kase C, et al. Intra-arterial Prourokinase for Acute Ischemic Stroke: The PROACT II Study: A Randomized Controlled Trial. *JAMA.* 1999 December 1, 1999;282(21):2003-11.
51. Waters IIRE, Mahaffey KW, Granger CB, Roe MT. Current perspectives on reperfusion therapy for acute ST-segment elevation myocardial infarction: integrating pharmacologic and mechanical reperfusion strategies. *American Heart Journal.* 2003;146(6):958-68.
52. Arnold M, Koerner U, Remonda L, Nedeltchev K, Mattle HP, Schroth G, et al. Comparison of intra arterial thrombolysis with conventional treatment in patients with acute central retinal artery occlusion. *J Neurol Neurosurg Psychiatry.* 2005;76:196 - 9.

53. Schumacher M, Schmidt D, Wakhloo AK. Intra-arterial fibrinolytic therapy in central retinal artery occlusion. *Neuroradiology*. 1993;35(8):600-5.
54. Kattah JC, Wang DZ, Reddy C. Intravenous Recombinant Tissue-Type Plasminogen Activator Thrombolysis in Treatment of Central Retinal Artery Occlusion. *Arch Ophthalmol*. 2002 September 1, 2002;120(9):1234-6.
55. Butz B, Strotzer M, Manke C, Roeder J, Link J, Lenhart M. Selective intraarterial fibrinolysis of acute central retinal artery occlusion. *Acta Radiol*. 2003;44(6):680 - 4.
56. Richard G, Lerche RC, Knospe V, Zeumer H. Treatment of retinal arterial occlusion with local fibrinolysis using recombinant tissue plasminogen activator. *Ophthalmology*. 1999;106(4):768-73.
57. Suri MF, Nasar A, Hussein HM, Divani AA, Qureshi AI. Intra-arterial thrombolysis for central retinal artery occlusion in United States: Nationwide In-patient Survey 2001-2003. *J Neuroimaging*. 2007;17(4):339-43.
58. Arruga J, Sanders MD. Ophthalmic findings in 70 patients with evidence of retinal embolism. *Ophthalmology*. 1982;89:1336 - 7.
59. Biousse V, Calvetti O, Bruce BB, Newman NJ. Thrombolysis for central retinal artery occlusion. *J Neuroophthalmol*. 2007;21(3):215-30.
60. Chen CS, Lee AW. Management of acute central retinal artery occlusion. *Nat Clin Pract Neuro*. 2008;4(7):376-83.

61. Schmidt D, Schumacher M, Feltgen N. Circadian incidence of non-inflammatory retinal artery occlusions. *Graefes Arch Clin Exp Ophthalmol*. 2009 Apr;247(4):491-4.
62. Aldrich EM, Lee AW, Chen CS, Gottesman RF, Bahouth MN, Gailloud P, et al. Local Intraarterial Fibrinolysis Administered in Aliquots for the Treatment of Central Retinal Artery Occlusion: The Johns Hopkins Hospital Experience. *Stroke*. 2008 6/1;39(6):1746-50.
63. Arroyo JG, Postel EA, Stone T, McCuen BW, Egan KM. A matched study of primary scleral buckle placement during repair of posterior segment open globe injuries. *Br J Ophthalmol*. 2003;87(1):75-8.
64. Karjalainen K. Occlusion of the central retinal artery and retinal branch arterioles. *Acta Ophthalmol*. 1971;109 (suppl):1-96.
65. Mueller AJ, Neubauer AS, Schaller U, Kampik A. Evaluation of Minimally Invasive Therapies and Rationale for a Prospective Randomized Trial to Evaluate Selective Intra-arterial Lysis for Clinically Complete Central Retinal Artery Occlusion. *Arch Ophthalmol*. 2003 October 1, 2003;121(10):1377-81.
66. Douglas DJ, Schuler JJ, Buchbinder D, Dillon BC, Flanigan DP. The association of central retinal artery occlusion and extracranial carotid artery disease. *Ann Surg*. 2008;208:85-90.
67. Russo C, Jin Z, Rundek T, Homma S, Sacco RL, Di Tullio MR. Atherosclerotic Disease of the Proximal Aorta and the Risk of Vascular Events in a

Population-Based Cohort: The Aortic Plaques and Risk of Ischemic Stroke (APRIS) Study. *Stroke*. 2009 7/1;40(7):2313-8.

68. Donnan GA, Fisher M, Macleod M, Davis SM. *Stroke*. *Lancet*. 2008;371:1612-23.

69. Noble J, Weizblit N, Baerlocher MO, Eng KT. Intra-arterial thrombolysis for central retinal artery occlusion: a systematic review. *Br J Ophthalmol*. 2008 May;92(5):588-93.

70. Hattenbach LO, Kuhli-Hattenbach C, Scharrer I, Baatz H. Intravenous thrombolysis with low-dose recombinant tissue plasminogen activator in central retinal artery occlusion. *Am J Ophthalmol*. 2008 Nov;146(5):700-6.

71. Lee P, Wang CC, Adamis AP. Ocular neovascularization: an epidemiologic review. *Surv Ophthalmol*. 1998 Nov-Dec;43(3):245-69.

72. Shazly TA, Latina MA. Neovascular glaucoma: etiology, diagnosis and prognosis. *Semin Ophthalmol*. 2009 Mar-Apr;24(2):113-21.

73. de Gottrau P, Holbach LM, Naumann GO. Clinicopathological review of 1146 enucleations (1980-90). *Br J Ophthalmol*. 1994 Apr;78(4):260-5.

74. Saeed MU, Chang BY, Khandwala M, Shivane AG, Chakrabarty A. Twenty year review of histopathological findings in enucleated/eviscerated eyes. *J Clin Pathol*. 2006 Feb;59(2):153-5.



75. Sagong M, Kim J, Chang W. Intravitreal bevacizumab for the treatment of neovascular glaucoma associated with central retinal artery occlusion. *Korean J Ophthalmol.* 2009 Sep;23(3):215-8.
76. Hayreh SS, Podhajsky PA, Zimmerman MB. Retinal artery occlusion: associated systemic and ophthalmic abnormalities. *Ophthalmology.* 2009 Oct;116(10):1928-36.
77. Hayreh SS, Podhajsky P. Ocular neovascularization with retinal vascular occlusion. II. Occurrence in central and branch retinal artery occlusion. *Arch Ophthalmol.* 1982 Oct;100(10):1585-96.
78. Duker JS, Sivalingam A, Brown GC, Reber R. A prospective study of acute central retinal artery obstruction. The incidence of secondary ocular neovascularization. *Arch Ophthalmol.* 1991 Mar;109(3):339-42.
79. NASCET-Collaborators. Beneficial effect of carotid endarterectomy is symptomatic patients with high grade stenosis. *N England J Med.* 1991;325:445-3.
80. Rudkin AK, Lee AW, Chen CS. Vascular risk factors for central retinal artery occlusion. *Eye (Lond).* 2010 Apr;24(4):678-81.
81. Duker JS, Brown GC. Iris neovascularization associated with obstruction of the central retinal artery. *Ophthalmology.* 1988 Sep;95(9):1244-50.
82. Schäfer S, Lang GE. Iris neovascularization as a complication of central artery occlusion. *Klinische Monatsblätter für Augenheilkunde.* 1995;222:343-5.

83. Duker JS, Brown GC. Neovascularization of the optic disc associated with obstruction of the central retinal artery. *Ophthalmology*. 1989 Jan;96(1):87-91.
84. Giles MF, Rothwell PM. Risk of stroke early after transient ischaemic attack: a systematic review and meta-analysis. *The Lancet Neurology*. 2007;6(12):1063-72.
85. Giannuzzi P, Temporelli PL, Marchioli R, Maggioni AP, Balestroni G, Ceci V, et al. Global secondary prevention strategies to limit event recurrence after myocardial infarction: results of the GOSPEL study, a multicenter, randomized controlled trial from the Italian Cardiac Rehabilitation Network. *Arch Intern Med*. 2008 Nov 10;168(20):2194-204.
86. Chawluk JB, Kushner MJ, Bank WJ, Silver FL, Jamieson DG, Bosley TM, et al. Atherosclerotic carotid artery disease in patients with retinal ischemic syndromes. *Neurology*. 1988 6/1;38(6):858.
87. Barnett HJ, Taylor DW, Eliasziw M, Fox AJ, Ferguson GG, Haynes RB, et al. Benefit of carotid endarterectomy in patients with symptomatic moderate or severe stenosis. North American Symptomatic Carotid Endarterectomy Trial Collaborators. *N Engl J Med*. 1998 Nov 12;339(20):1415-25.
88. Graham GD. Secondary stroke prevention: from guidelines to clinical practice. *J Natl Med Assoc*. 2008 Oct;100(10):1125-37.
89. Paciaroni M, Hennerici M, Agnelli G, Bogousslavsky J. Statins and stroke prevention. *Cerebrovasc Dis*. 2007;24(2-3):170-82.

90. Gaunt M, Davis P, Lee AG, Lee MS. Getting to the heart of the matter. *Surv Ophthalmol.* 2008 Nov-Dec;53(6):636-40.
91. Romano JG, Sacco RL. Progress in secondary stroke prevention. *Ann Neurol.* 2008 Apr;63(4):418-27.
92. Campbell CL, Smyth S, Montalescot G, Steinhubl SR. Aspirin Dose for the Prevention of Cardiovascular Disease: A Systematic Review. *JAMA.* 2007 May 9, 2007;297(18):2018-24.
93. Willinsky RA, Taylor SM, terBrugge K, Farb RI, Tomlinson G, Montanera W. Neurologic Complications of Cerebral Angiography: Prospective Analysis of 2,899 Procedures and Review of the Literature. *Radiology.* 2003 May 1, 2003;227(2):522-8.
94. Leffers A, Wagner A. Neurologic complications of cerebral angiography: A retrospective study of complication rate and patient risk factors. *Acta Radiologica.* 2000;41:204-10.
95. Heiserman JE, Dean BL, Hodak JA, Flom RA, Bird CR, Drayer BP, et al. Neurologic complications of cerebral angiography. *AJNR Am J Neuroradiol.* 1994;15(8):1401 - 7.
96. del Zoppo GJ, Higashida RT, Furlan AJ, Pessin MS, Rowley HA, Gent M. PROACT : A phase II randomized trial of recombinant pro-urokinase by direct arterial delivery in acute middle cerebral artery stroke. *Stroke.* 1998 January 1998;29(1):4-11.

97. Rosser D, Cousens S, Murdoch I, Fitzke F, Laidlaw D. How sensitive to clinical changes are ETDRS log MAR visual acuity measurements ? Invest Ophthalmol Vis Sci. 2003;44:3278-81.
98. The-Eye-Diseases-Prevalence-Research-Group. Causes and Prevalence of Visual Impairment Among Adults in the United States. Archives of Ophthalmology. 2004 4/1;122(4):477-85.
99. Weber J, Remonda L, Mattle HP, Koerner U, Baumgartner RW, Sturzenegger M, et al. Selective intra-arterial fibrinolysis of acute central retinal artery occlusion. Stroke. 1998;29(10):2076-9.
100. Kohrmann M, Juttler E, Fiebach JB, Huttner HB, Siebert S, Schwark C, et al. MRI versus CT-based thrombolysis treatment within and beyond the 3 h time window after stroke onset: a cohort study. The Lancet Neurology. 2006;5(8):661-7.
101. Albers G, Thijis VN, Wechsler L, Kemp S, Schlaug G, Skalabrin E, et al. Magnetic resonance imaging profiles predict clinical response to early reperfusion: The diffusion and perfusion imaging evaluation for understanding stroke (DEFUSE) study. Ann Neurol. 2006;60:508-17.
102. GUSTO. An International Randomized Trial Comparing Four Thrombolytic Strategies for Acute Myocardial Infarction. N England J Med. 1993 September 2, 1993;329(10):673-82.
103. Hayreh SS, Dass R. The central artery of the retina I. Origin and course. Br J Ophtalmol. 1960;44:193-212.

104. Astrup J, Symon L, Branston NM, Lassen NA. Cortical evoked potential and extracellular K<sup>+</sup> and H<sup>+</sup> levels at critical levels of brain ischemia. *Stroke*. 1977;8:51-7.
105. Feltgen N, Neubauer A, Jurklies B, Schmoor C, Schmidt D, Wanke J, et al. Multicenter study of the European Assessment Group for Lysis in the Eye (EAGLE) for the treatment of central retinal artery occlusion: design issues and implications. EAGLE study report no. 1. *Graefes Arch Clin Exp Ophthalmol*. 2006;244:950-6.
106. Hacke W, Kaste M, Bluhmki E, Brozman M, Davalos A, Guidetti D, et al. Thrombolysis with Alteplase 3 to 4.5 Hours after Acute Ischemic Stroke. *The New England Journal of Medicine*. 2008 9/25;359(13):1317-29.
107. Wahlgren N, Ahmed N, Davalos A, Ford GA, Grond M, Hacke W, et al. Thrombolysis with alteplase for acute ischaemic stroke in the Safe Implementation of Thrombolysis in Stroke-Monitoring Study (SITS-MOST): an observational study. *The Lancet*. 2007;369(9558):275-82.
108. Wahlgren N, Ahmed N, Dávalos A, Hacke W, Millán M, Muir K, et al. Thrombolysis with alteplase 3-4.5 h after acute ischaemic stroke (SITS-ISTR): an observational study. *The Lancet*. 2008;372(9646):1303-9.
109. Biousse V, Calvetti O, Bruce BB, Newman NJ. Thrombolysis for central retinal artery occlusion. *J Neuro Ophthalmol*. 2007;27:215-30.

110. Alberts MJ, Latchaw RE, Selman WR, Shephard T, Hadley MN, Brass LM, et al. Recommendations for Comprehensive Stroke Centers: A Consensus Statement From the Brain Attack Coalition. *Stroke*. 2005 July 1, 2005;36(7):1597-616.
111. Schwamm LH, Pancioli A, Acker JE, III, Goldstein LB, Zorowitz RD, Shephard TJ, et al. Recommendations for the Establishment of Stroke Systems of Care: Recommendations From the American Stroke Association's Task Force on the Development of Stroke Systems. *Stroke*. 2005 March 1, 2005;36(3):690-703.
112. Schmidt DP, Schulte-Monting J, Schumacher M. Prognosis of central retinal artery occlusion: local intraarterial fibrinolysis versus conservative treatment. *AJNR Am J Neuroradiol*. 2002 Sep;23(8):1301-7.
113. The-GISSI-Study-Group. GISSI-2: A factorial randomised trial of alteplase versus streptokinase and heparin versus no heparin among 12 490 patients with acute myocardial infarction *Lancet* 1990;336:65-71.
114. Schumacher M, Schmidt D, Jurklics B, Gall C, Wanke I, Schmoor C, et al. Central retinal artery occlusion: local intra-arterial fibrinolysis versus conservative treatment, a multicenter randomized trial. *Ophthalmology*. 2010 Jul;117(7):1367-75 e1.
115. Wardlaw JM, Murray V, Berge E, Del Zoppo GJ. Thrombolysis for acute ischaemic stroke. *Cochrane Database Syst Rev*. 2009(4):CD000213.

116. Chen CS, Lee AW, Campbell B, Paine M, Lee T, Fraser C, et al. Study of the efficacy of intravenous tissue plasminogen activator in central retinal artery occlusion. *International Journal of Stroke*. 2010;In press.
117. Fibrinolytic-therapy-Trialist-Collaborative-Group. Indications for fibrinolytic therapy in suspected myocardial infarction : collaborative overview of early mortality and major morbidity results from all randomised trials of more than 1000 patients. *Lancet*. 1994;343(311-321).
118. Lansberg MG, Albers GW, Wijman CA. Symptomatic intracerebral hemorrhage following thrombolytic therapy for acute ischemic stroke: a review of the risk factors. *Cerebrovasc Dis*. 2007;24(1):1-10.
119. Derex L, Nighoghossian N. Intracerebral haemorrhage after thrombolysis for acute ischaemic stroke: an update. *J Neurol Neurosurg Psychiatry*. 2008 Oct;79(10):1093-9.
120. Norrving B. [Lacunar infarcts]. *Ther Umsch*. 2003 Sep;60(9):535-40.
121. Meretoja A, Tatlisumak T. Novel thrombolytic drugs: will they make a difference in the treatment of ischaemic stroke? *CNS Drugs*. 2008;22(8):619-29.
122. Rudkin AK, Lee AW, Chen CS. Central retinal artery occlusion: timing and mode of presentation. *Eur J Neurol*. 2009 Jun;16(6):674-7.

123. Wang JJ, Cugati S, Knudtson MD, Rochtchina E, Klein R, Klein BE, et al. Retinal arteriolar emboli and long-term mortality: pooled data analysis from two older populations. *Stroke*. 2006 Jul;37(7):1833-6.
124. The National Institute of Neurological Disorders Stroke rt PASSG. Recombinant Tissue Plasminogen Activator for Minor Strokes: The National Institute of Neurological Disorders and Stroke rt-PA Stroke Study Experience. *Annals of Emergency Medicine*. 2005;46(3):243-52.
125. Schmidt D, Schumacher M, Feltgen N. Circadian incidence of non-inflammatory retinal artery occlusion. *Graefes Arch Clin Exp Ophthalmol*. [[Epub ahead of print]]. 2008 2008 Nov 7.
126. Brown GC. Retinal arterial obstruction disease. Ryan S, editor. St. Louis: Mosby; 1994.



REVIEW

www.nature.com/clinicalpractice/neuro

## Management of acute central retinal artery occlusion

Celia S Chen and Andrew W Lee\*

### SUMMARY

Central retinal artery occlusion (CRAO) is considered to be an acute stroke of the eye that results in profound visual loss. Spontaneous recovery rates are poor. Most CRAOs are caused by thromboembolism in the central retinal artery. Current standard therapies for CRAO that aim to restore perfusion to the retina and optic nerve head have not been shown to alter the natural course of the disease. Thrombolytic therapy for acute management of CRAO has shown promise in nonrandomized studies with regard to improving visual outcomes. A randomized controlled trial will be required to confirm the efficacy of thrombolytic therapy before it can be recommended for use in CRAO in daily clinical practice.

**KEYWORDS** central retinal artery occlusion, retina, stroke, thromboembolism, thrombolytic therapy

### REVIEW CRITERIA

For this Review, we searched PubMed for articles published from 1990 to 2007, including early release publications. Search terms included "central artery occlusion", "retinal artery occlusion", "retinal vascular occlusion" and "thrombolysis", in conjunction with "eye" or "retinovascular". The abstracts of retrieved citations were reviewed and prioritized by relevant content. Full articles were obtained and references were checked for additional material where appropriate.

### INTRODUCTION

Central retinal artery occlusion (CRAO) is considered to be an acute stroke of the eye. The most common etiology is a fibrin-platelet thrombus or embolus that occludes the central retinal artery (CRA), leading to ischemia of the retina and optic nerve head with resultant visual loss.<sup>1,2</sup> The visual prognosis of CRAO is poor, with 61% of patients having a final visual acuity of 20/400 or worse. This degree of severe unilateral visual impairment can limit social functioning, lead to mental health problems,<sup>3</sup> and increase the risk of experiencing falls and becoming dependent on others.<sup>4</sup> In addition, CRAO might be the first manifestation of atherosclerotic disease, presaging either a cerebrovascular or a cardiovascular event and necessitating preventive therapy.<sup>5</sup>

Following diagnosis of CRAO, prompt acute and ongoing management strategies need to be instituted. Current acute therapy aims to increase both retinal and optic nerve head perfusion through arterial vasodilation, manually dislodging emboli, or increasing the perfusion pressure by decreasing intraocular pressure in relation to CRA blood pressure. None of these treatments, however, has been shown to improve visual acuity beyond that achieved if the disease is left to take its natural course.<sup>6-8</sup>

This Review will discuss the pathogenesis of CRAO and the efficacy of current acute treatments. The article will go on to outline the rationale behind a new treatment strategy for CRAO that involves local intra-arterial thrombolysis and survey the promising results that have been obtained with this approach to date.

### WHAT IS CENTRAL RETINAL ARTERY OCCLUSION?

CRAO is an acute occlusion of the CRA that results in a sudden, painless monocular loss of vision. The patient's vision at presentation is usually only 'counting fingers' or less in the affected eye. The CRA branches off the ophthalmic artery and supplies blood to

CS Chen is a Consultant Neuro-ophthalmologist in the Department of Ophthalmology and AW Lee is a Consultant Cerebrovascular Neurologist in the Department of Neurology, Flinders Medical Centre, Flinders University, Bedford Park, South Australia, Australia.

#### Correspondence

\*Department of Neurology, Flinders Medical Centre, Bedford Drive, Bedford Park, South Australia 5042, Australia  
awmlee1@gmail.com

Received 1 October 2007 Accepted 27 March 2008 Published online 10 June 2008

www.nature.com/clinicalpractice  
doi:10.1038/ncpneuro0811

the prelaminar part of the optic nerve before branching into arterioles, which supply blood to two thirds of the inner retina.<sup>2</sup> In CRAO, infarction of the inner retina and intracellular edema give rise to a pale retina compared with its usual orange color (Figure 1). In acute CRAO, the choroid underlying the macula—the thinnest part of the retina—produces a dark orange-red color, described as a 'cherry red spot', against the pale retina (Figure 1B). Other signs in the affected eye include an afferent pupillary defect relative to the unaffected eye and a visual field defect. The retinal arterioles can show changes that reflect systemic arteriosclerosis, including narrowing of the arterioles and venules and 'box-carrying' of flow in both arterioles and veins (Figure 1B, arrowheads). Investigations with fundus fluorescein angiography show a marked delay in filling of the CRA and its branches (Figure 2). Venous filling is also slowed.

CRAOs can be divided into four subclasses: nonarteritic transient CRAO, nonarteritic permanent CRAO, arteritic CRAO, and nonarteritic CRAO with cilioretinal sparing.<sup>1</sup> Nonarteritic transient CRAOs, which are analogous to cerebral transient ischemic attacks, account for 15% of all CRAO cases, and they tend to have the best visual prognosis of all CRAOs. In the vast majority of CRAO cases, however, the occlusion is permanent, resulting in infarction of the retina. Nonarteritic permanent CRAOs account for more than two-thirds of all CRAO cases. Arteritic CRAO, which includes vasculitic etiologies such as giant cell arteritis (GCA), accounts for under 5% of the total number of CRAOs.<sup>1</sup>

In 15–30% of the general population, a cilioretinal artery arises from the ciliary circulation to supply blood to a portion of the papillomacular bundle—the area that contains the maximum concentration of photoreceptors and is essential for central vision.<sup>9</sup> In this subset of people, the macula can still be perfused during an acute CRAO (Figure 3), enabling good vision to be retained.

#### **PATHOGENESIS OF CENTRAL RETINAL ARTERY OCCLUSION**

##### **Thromboembolism**

The most common cause of CRAO is a thrombus or embolus that lodges in the CRA. The nature of the occlusion has been debated, although the general view is that CRAOs are more commonly caused by acute thrombi than by emboli.<sup>6</sup> Emboli

are usually smaller than thrombi and are more likely to cause a branch retinal arterial occlusion than a CRAO. The occlusion in CRAO is usually located immediately posterior to the lamina cribrosa,<sup>7</sup> the portion of the optic nerve adjacent to the sclera. If the occlusion is anterior to the lamina cribrosa, as occurs in fewer than 20% of CRAO cases, the embolus might be visible on fundoscopy.<sup>8,10</sup>

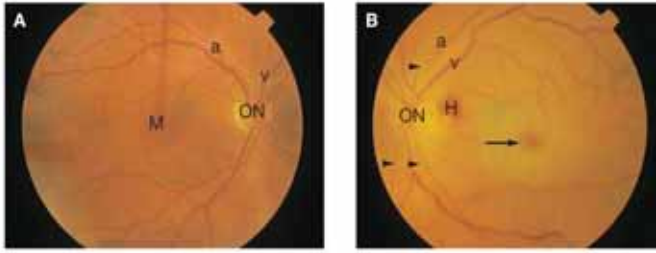
Patients with CRAO caused by emboli have a higher mortality rate than those without emboli.<sup>11,12</sup> The majority of emboli originate from the heart or carotid arteries. The composition of these emboli vary, and they include fibrin-platelet plugs, cholesterol plaques, and calcium fragments.<sup>13</sup> In young patients (<45 years of age) with acute CRAO of embolic origin, a cardiac pathology such as an atrial myxoma or other cardiac tumor,<sup>14</sup> or congenital or rheumatic heart disease, should be considered.<sup>15</sup> In very rare situations, internal carotid artery emboli from a carotid artery dissection or aneurysm have been reported to cause CRAO.<sup>16</sup>

The risk factors for CRAO are the same as those for atherosclerosis, with hypertension and diabetes being the most common associations.<sup>17</sup> Other atherosclerotic risk factors associated with CRAO include hypercholesterolemia, smoking, and a family history of macrovascular disease.<sup>18,19</sup> In addition, coronary artery disease, atherosclerotic carotid disease, and peripheral vascular disease are associated with CRAO.

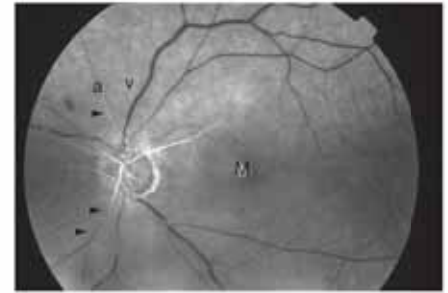
In young patients, proatherogenic states, such as hyperhomocysteinemia, and hypercoagulable states, such as those that occur in patients with factor V Leiden, with protein C, protein S or antithrombin III deficiencies, with antiphospholipid antibodies, or with Gly20210Ala mutations in the prothrombin gene, should be investigated.<sup>20–23</sup> Other rare systemic diseases reported to cause CRAO include sickle cell disease<sup>24</sup> and paraneoplastic syndromes,<sup>25</sup> both of which contribute to a hypercoagulable state. Some patients have no notable atherosclerotic risk factors but do have a history of migraine, which suggests a possible role for vasospasm in CRAO.<sup>26</sup>

##### **Retinal vasculitis**

Vasculitides that affect large-sized and medium-sized vessels can cause inflammatory occlusion of the CRA.<sup>1</sup> Fortunately, these vasculitides are uncommon and account for fewer than 5% of CRAO cases. Of these vasculitides, GCA is the



**Figure 1** Color fundus photographs in a patient with acute central retinal artery occlusion. (A) The unaffected right eye. (B) Left eye showing signs of an acute central retinal artery occlusion. The left eye shows pallor of the retina compared with the right eye, and the macula, indicated by (M) in part A, is seen as a 'cherry red spot' (arrow) against the pale retina. The retinal arteries (a) and venules (v) are attenuated and there is box-carring of the arterioles (arrowheads). The optic nerve (ON) is swollen, resulting in blurred disc margins, and there is a peripupillary hemorrhage (H) temporal to the optic nerve.



**Figure 2** Fundus fluorescein angiography of an eye with acute central retinal artery occlusion. The image shows limited and sluggish filling (arrowheads) of the retinal arteries (a) 40 s after injection of fluorescein. The veins (v) were not yet filling. The macula (M) was not perfused.

most common and can produce unilateral or bilateral CRAO that is often, but not always, refractory to treatment with systemic corticosteroids. Other causes of vasculitic CRAO include systemic lupus erythematosus, polyarteritis nodosa, Takayasu's aortitis, Wegener's granulomatosis,<sup>27</sup> and, in rare cases, postviral syndromes such as herpes zoster.<sup>7</sup>

#### Iatrogenic causes

Iatrogenic causes of CRAO are rare but have been described in the context of autologous fat injection into the nasolabial groove,<sup>28</sup> intralesional steroid injection for eyelid capillary hemangioma,<sup>29</sup> and spinal surgery.<sup>30</sup> The pathogenesis of perioperative visual loss is not fully understood and is probably multifactorial. Postulated mechanisms include direct pressure on the eye and orbital structures during surgery owing to incorrect positioning of a firm headrest<sup>31</sup>—both hypovolemia and hypotension have also been hypothesized to be contributing factors in this scenario.<sup>32</sup> Vinerovsky *et al.* reported two cases of CRAO resulting from peribulbar anesthesia, and they proposed that these were caused by the vasospastic effect of epinephrine on the retinal and optic nerve circulation.<sup>33</sup>

#### CURRENT ACUTE MANAGEMENT

The rationale behind current acute treatments of CRAO is removal of the CRA blockage. There is no consensus regarding the precise strategy for acute management of CRAO, partly because there are many variables involved, including the degree of

vascular obstruction, the presence of a cilioretinal artery, and the underlying pathogenesis.

Opinions differ regarding the length of time it takes for permanent visual loss to occur after CRA occlusion.<sup>34–36</sup> Early primate experiments suggested that the retina had an ischemic tolerance time of a mere 97–100 min.<sup>35</sup> By contrast, experiments in primate models with an increased burden of atherosclerosis showed that recovery of retinal function could occur at up to 240 min after occlusion, which is similar to the therapeutic window of the ischemic penumbra in cerebral stroke.<sup>34</sup> Clinical improvement with intervention 24–48 h after the onset of CRAO has also been reported.<sup>37</sup>

The discussion that follows concentrates mainly on nonarteritic CRAOs of presumed thromboembolic origin, which represent the majority of CRAO cases. It is important to note that arteritic CRAOs, resulting from GCA or other vasculitides, carry the risk of bilateral visual loss and are associated with markedly increased mortality and morbidity.<sup>38</sup> Patients in whom arteritic CRAOs are suspected should be treated immediately, and efforts should be made to establish the underlying diagnosis. For example, if GCA is considered to be a likely diagnosis, erythrocyte sedimentation rate and C-reactive protein assays should be conducted, and the patient should then be treated immediately with high-dose intravenous corticosteroids, followed by confirmation of the diagnosis with a unilateral or bilateral temporal artery biopsy.

Current acute management strategies for nonarteritic CRAO can be divided into two categories: noninvasive standard therapy, and invasive local intra-arterial fibrinolysis (LIF). Noninvasive therapy can be grouped into four main areas, as described in the sections that follow.

### Noninvasive therapy

#### Observation

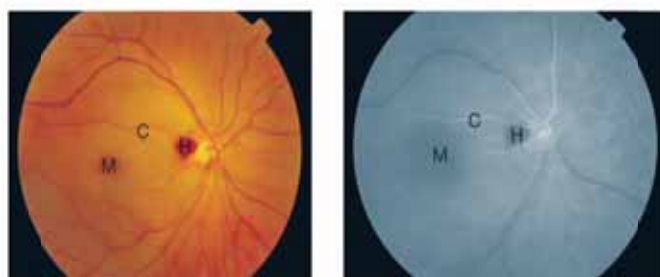
If spontaneous recanalization of the occluded CRA occurs at all, it usually happens within 48–72 h of the occlusion. Retinal blood flow is often only partially restored after spontaneous recanalization,<sup>10</sup> and current estimates of the spontaneous visual improvement rate in nonarteritic CRAO vary from 1% to 10%.<sup>6,39,40</sup>

Debate exists among various groups as to what constitutes a significant improvement in visual acuity. Some authors have suggested that a two to three lines or greater visual improvement on a Snellen acuity chart is significant, as it is considered to be a doubling of visual angle,<sup>41</sup> but this level of improvement occurs in fewer than 10% of individuals in whom reperfusion occurs spontaneously.<sup>20</sup> The attainment of a visual acuity of 20/200 or better could also be used as an arbitrary cut-off to represent a significant improvement in visual function, given that the majority of individuals with CRAO have a visual acuity of 20/200 or less. In addition, 20/200 vision is the definition for legal blindness in the US and also represents the level of visual acuity below which independent living is considered to be difficult, if not impossible.

#### Dilation of retinal arteries and increasing blood oxygen content

Noninvasive interventions such as administration of sublingual isosorbide dinitrate or systemic pentoxifylline, inhalation of carbogen (a mixture of 95% oxygen and 5% carbon dioxide), or rebreathing of expired carbon dioxide have been tried in patients with CRAO.<sup>20,42–44</sup> These treatments are thought to vasodilate the CRA, thereby increasing retinal blood flow. Retinal Doppler ultrasonography has revealed increases in retinal blood flow when these approaches are used, but there has been no documentation of an association between clinical improvement, in terms of visual acuity or visual field changes, and increases in retinal blood flow.<sup>45</sup>

Hyperbaric oxygen has also been tried in an attempt to increase diffusible oxygen content to the ischemic retina, but the results have been equivocal.<sup>46</sup>



**Figure 3** Central retinal artery occlusion with cilioretinal artery sparing. (A) Color fundus photograph. (B) Fundus fluorescein angiography. The cilioretinal artery (C) perfuses the superior part of the macula (M). The patient had vision of 20/80 at presentation. There is a peripupillary hemorrhage (H) temporal to the optic disc.

#### Attempts to dislodge emboli

Measures to dislodge emboli with ocular massage, either directly or through a contact lens to permit observation of the retinal circulation, have been described.<sup>10</sup> Rumelt *et al.* assessed the success of using ocular massage with a three-mirror contact lens.<sup>42</sup> The end point was improved retinal arterial blood flow, which was defined as the re-establishment of continuous laminar flow, an increase in the width of the blood column, and the disappearance of fragmented flow. All patients also received sublingual isosorbide dinitrate, intravenous acetazolamide, intravenous mannitol, and oral glycerol. Only one out of eight patients had improved retinal blood flow with this regimen, suggesting that ocular massage—alone or with measures to dilate the retinal arteries and reduce intraocular pressure—has a limited success rate.

#### Increasing retinal artery perfusion pressure by reducing intraocular pressure

On the basis of the fact that mean ocular perfusion pressure is the difference between mean arterial pressure and intraocular pressure, attempts have been made to reduce the intraocular pressure and thereby increase ocular perfusion. Measures that have been employed include the use of intravenous acetazolamide or mannitol to acutely reduce intraocular pressure, and anterior chamber paracentesis followed by the withdrawal of a small amount of aqueous fluid from the eye.<sup>19,20,42,47</sup>

Most patients receive a combination of the above therapies. Atebara *et al.* compared the efficacy of anterior chamber paracentesis and carbogen inhalation with that of no acute treatment, and

they found no statistically significant differences in outcomes between the treated and untreated groups.<sup>20</sup> Rumelt *et al.* and Landa *et al.* both evaluated the effect of a systematic stepwise approach starting with ocular massage, globe compression, sublingual isosorbide dinitrate and intravenous acetazolamide, followed by intravenous mannitol, methylprednisolone, and, finally, intravenous streptokinase and retrobulbar tolazoline.<sup>42,48</sup> The effect of the stepwise approach was compared with the response in controls, whose treatments were administered in an arbitrary nonsystematic manner. Both studies were limited by small patient numbers, but the studies showed a greater visual improvement in those who received the systematic stepwise approach than in the controls. Nevertheless, Landa *et al.* found that despite stepwise systematic implementation of standard therapies, their patients all had some residual deficits in visual function, supporting the argument that these 'standard therapies' are not truly effective.<sup>48</sup> These findings highlight the need for investigations into alternative treatments for CRAO.

#### **Invasive therapy: thrombolysis**

##### *Rationale for thrombolytic therapy*

By far the most exciting recent development in the treatment of CRAO is the use of thrombolytic therapy. Systemic and intra-arterial thrombolysis have been successful at restoring perfusion to ischemic tissue through fibrin-platelet clot lysis in cases of ischemic stroke and myocardial infarction.<sup>49–51</sup> The use of thrombolysis in CRAO relies on two assumptions: first, that the CRAO is of nonarteritic etiology, and second, that the material occluding the CRA is a fibrin-platelet thrombus or embolus that can be lysed.

In several open-label studies, LIF was efficacious in the treatment of CRAO, with up to 60–70% of treated individuals experiencing an improvement in visual acuity.<sup>39,40,52,53</sup> By contrast, individuals treated with standard therapy had a poor visual outcome, comparable to that obtained in previous studies of the natural course of CRAO.<sup>7,8</sup>

##### *Administration of thrombolytic agents*

The administration of streptokinase or tissue plasminogen activator (tPA), either intravenously or intra-arterially, has been attempted in patients with CRAO. Kattah *et al.* administered tPA intravenously and reported that 10 out of 12 patients with CRAO achieved some degree of improvement

in visual acuity, with no thrombolysis-related systemic or neurological complications.<sup>54</sup> Four of these patients, however, subsequently developed neovascular glaucoma.

Intra-arterial administration of thrombolytic agents delivered directly to the ophthalmic artery, and thence to the CRA, usually involves a continuous infusion of tPA, with a dose in the range 40–80 mg, or of urokinase, in a dose ranging from 300,000 to 1 million units.<sup>52,53,55</sup> In several open-label studies, LIF was shown to be effective in CRAO, with up to 60–70% of treated subjects experiencing an improvement in visual acuity.<sup>40,52,53,56</sup> Reported adverse effects included ischemic cerebrovascular accidents and both intracerebral and systemic bleeding.<sup>39,52,55</sup> The US Nationwide Inpatient Survey of 2001–2003 found that intra-arterial thrombolysis was given to 1.9% of patients who presented with CRAO during those years, and the treatment was offered only in selected urban hospitals.<sup>57</sup> There was no in-hospital mortality or intracranial hemorrhaging reported among patients with CRAO who were treated with thrombolysis.

Several criticisms have been leveled at these early reports. The first is that a number of these studies deployed LIF beyond the 97–240 min that primate experiments showed was the maximum retinal ischemic tolerance time. The second is the assumption that CRAO is caused by lysable fibrin-platelet thrombi or emboli. One early report demonstrated that 50% of visible emboli consist of cholesterol, and such emboli would not respond to thrombolysis.<sup>58</sup> It is important to stress, however, that the majority of emboli in CRAO occur at the level of the lamina cribrosa and are consequently not visible on funduscopy. It cannot be assumed, therefore, that a study of visible emboli accurately represents the frequency distribution of retinal embolus types in CRAO.

The main controversy is whether the use of LIF results in an improvement in visual function above and beyond that found if the disease is allowed to take its natural course.<sup>1</sup> The studies listed to date have used various measures of outcome, one being an improvement in visual acuity of one line or more on a Snellen chart, and the studies have not necessarily included physiological secondary end points, such as the objective documentation of retinal blood flow shown by fundus fluorescein angiography.<sup>59</sup> The lack of consistency in even the primary

end point used, such as the number of lines of improvement of visual acuity, makes comparison between interventional and natural course studies difficult. In addition, the question still remains as to whether continuous infusion of a fibrinolytic agent is the best method of delivery with the lowest complication rate.

To address these issues, Eric Aldrich and colleagues at Johns Hopkins Hospital, Baltimore, MD, USA performed a nonrandomized study of super-selective catheterization of the ophthalmic artery followed by LIF by use of tPA given in aliquots until patency of the CRA was established clinically.<sup>60</sup> With thrombolytic therapy, the risk of hemorrhagic complications is related to the total dose of thrombolytic agent, and the risk of ischemic stroke is thought to be related to the total time during which an arterial catheter remains within the carotid artery. Consequently, it was hypothesized that the delivery of LIF in aliquots would result in a relatively small dose of thrombolytic agent being delivered within a short time period, thereby minimizing the risk of such complications.

From 1999 to 2006, 42 consecutive patients with CRAO that was diagnosed clinically by an ophthalmologist were recruited into the study. On the basis of the treating clinician's personal preference, the patients were assigned to receive either standard therapy plus LIF with tPA delivered in 3 mg aliquots, or standard therapy alone. Standard therapy could consist of any one or a combination of the following: observation; ocular paracentesis; inhalation of carbogen; and administration of agents such as acetazolamide to reduce intraocular pressure. The primary end point was an improvement in visual acuity by one line or more on a Snellen chart, as well as an improvement in visual acuity of three lines or more at final follow-up, 15 months after enrollment. All adverse events were recorded.

In this study, 76% of patients who received LIF compared with 33% of the standard therapy group had a visual acuity improvement of one line or more on a Snellen chart at final follow-up ( $P=0.018$ ). The remaining patients in the LIF group showed no improvement in visual acuity. A third of the LIF group attained an improvement of three lines or more on a Snellen chart, compared with 4.8% of the standard therapy group ( $P=0.018$ ). Multivariate regression analysis adjusted for age, sex, history of hypertension or hypercholesterolemia, and history of transient ischemic attacks or cerebrovascular events

showed that the use of LIF was the principal determinant for achieving a good visual outcome, and individuals who received LIF were 13 times more likely to achieve an improvement in visual acuity of three lines or more on a Snellen chart than were those who did not (odds ratio 13, 95% CI 1.2–145.0;  $P=0.03$ ).

Although this study was nonrandomized, the point estimates of the improvement in visual acuity for the standard therapy group mirror those of the spontaneous improvement of visual acuity found in studies of the natural course of CRAO. In addition, the LIF group showed an improvement in visual acuity consistent with that seen in previous studies employing thrombolytic therapy, and this improvement exceeded that found in studies of standard therapy. Owing to the nonrandomized nature of this and previous studies, however, LIF cannot yet be considered to be standard therapy, and it should be used only within the confines of an approved clinical trial. Nevertheless, these studies provide sufficient equipoise for a multicenter randomized controlled study of LIF to be conducted that, in the event of a positive outcome, would represent a major step forward in the treatment of CRAO.<sup>60</sup>

## CONCLUSIONS

In summary, all current acute management strategies for CRAO have limited efficacy, the evidence for which is based on data from nonrandomized studies. Of all the treatments to date, thrombolysis, especially LIF,<sup>18</sup> shows the most promise. A randomized controlled trial is required, however, before this approach can be recommended for use in daily clinical practice.

## KEY POINTS

- Central retinal artery occlusion (CRAO) is considered to be an acute stroke of the eye that involves hypoperfusion to the retina and optic nerve head and leads to a reduction in visual function
- CRAO has a poor spontaneous recovery rate
- Current standard therapies for CRAO have not conclusively been shown to change the natural course of the disease
- Local intra-arterial fibrinolysis shows promise in nonrandomized studies for the treatment of CRAO, but a randomized controlled trial will be required to demonstrate efficacy before this treatment can be considered for use in standard clinical practice

## References

- 1 Hayreh SS and Zimmerman MB (2005) Central retinal artery occlusion: visual outcome. *Am J Ophthalmol* **140**: 376–391
- 2 Hayreh SS (1995) The 1994 Von Sallman Lecture: the optic nerve head circulation in health and disease. *Exp Eye Res* **61**: 259–272
- 3 Chia EM et al. (2003) Unilateral visual impairment and health related quality of life: the Blue Mountains Eye Study. *Br J Ophthalmol* **87**: 392–395
- 4 Vu HTV et al. (2005) Impact of unilateral and bilateral vision loss on quality of life. *Br J Ophthalmol* **89**: 360–363
- 5 Recchia FM and Brown GC (2003) Systemic disorders associated with retinal vascular occlusion. *Curr Opin Ophthalmol* **11**: 462–467
- 6 Duker JS (2004) Retinal artery obstruction. In *Ophthalmology*, edn 2, 854–858 (Eds Yanoff M et al.) St Louis: Mosby
- 7 Mangat HS (1995) Central retina artery occlusion. *Surv Ophthalmol* **40**: 145–156
- 8 Babikian V et al. (2001) Retinal ischemia and embolism, etiologies and outcomes based on a prospective study. *Cerebrovasc Dis* **12**: 108–113
- 9 Lorentzen SE (1970) Incidence of cilioretinal arteries. *Acta Ophthalmol (Copenh)* **48**: 518–524
- 10 Rumelt S and Brown GC (2003) Update on treatment of retinal arterial occlusions. *Curr Opin Ophthalmol* **14**: 139–141
- 11 Savino PJ et al. (1977) Retinal stroke: is the patient at risk? *Arch Ophthalmol* **95**: 1185–1189
- 12 Wong TY and Klein R (2002) Retinal arteriolar emboli: epidemiology and stroke risk. *Curr Opin Ophthalmol* **13**: 142–146
- 13 Bioussé V (2005) Cerebrovascular disease. In *Walsh and Hoyt's Clinical Neuro-Ophthalmology*, 1967–2168 (Eds Miller NR et al.) Philadelphia: Lippincott, Williams & Wilkins
- 14 Schmidt D et al. (2005) Retinal arterial occlusion due to embolism of suspected cardiac tumors—report on two patients and review of the topic. *Eur J Med Res* **10**: 296–304
- 15 Sharma S et al. (1997) Transthoracic echocardiography in young patients with acute retinal arterial obstruction. RECO Study Group. Retinal Emboli of Cardiac Origin Group. *Can J Ophthalmol* **32**: 38–41
- 16 Mokhtari F et al. (2000) Central retinal artery occlusion associated with head or neck pain revealing spontaneous internal carotid artery dissection. *Am J Ophthalmol* **129**: 108–109
- 17 Schmidt D et al. (2007) Systemic diseases in non-inflammatory branch and central retinal artery occlusion: an overview of 416 patients. *Eur J Med Res* **12**: 595–603
- 18 Fraser S and Sirlwardena D. Interventions for acute non-arteritic central retinal artery occlusion. *Cochrane Database of Systematic Reviews* 2002, Issue 1. Art. No.: CD001989. doi:10.1002/14651858.CD001989
- 19 Flytche TJ (1974) A rationalization of treatment of central retinal artery occlusion. *Trans Ophthalmol Soc UK* **94**: 468–479
- 20 Atebara NH et al. (1995) Efficacy of anterior chamber paracentesis and carbogen in treating acute nonarteritic central retinal artery occlusion. *Ophthalmology* **102**: 2029–2035
- 21 Wenzler EM et al. (1993) Hyperhomocysteinemia in retinal artery and retinal vein occlusion. *Am J Ophthalmol* **115**: 162–167
- 22 Betram B et al. (1995) Protein C, protein S, and antithrombin III in acute ocular occlusive diseases. *Ger J Ophthalmol* **4**: 332–335
- 23 Rumelt S and Rehany U (1999) Central retinal artery occlusion associated with primary antiphospholipid syndrome. *Eye* **13**: 699–700
- 24 Liem RI et al. (2008) Sudden-onset blindness in sickle cell disease due to retinal artery occlusion. *Pediatr Blood Cancer* **50**: 624–627
- 25 Cohen RJ et al. (1995) Central retinal artery occlusion in a child with T-cell lymphoma. *Am J Ophthalmol* **120**: 118–120
- 26 Chawluk JB et al. (1988) Atherosclerotic carotid artery disease in patients with retinal ischemic syndromes. *Neurology* **38**: 858–863
- 27 Costello F et al. (2005) Bilateral simultaneous central retinal artery occlusions in Wegener granulomatosis. *J Neuroophthalmol* **25**: 29–32
- 28 Lee DH et al. (1996) Sudden unilateral visual loss and brain infarction after autologous fat injection into the nasolabial groove. *Br J Ophthalmol* **80**: 1026–1027
- 29 Egbert JE et al. (1996) Diagnosis and treatment of an ophthalmic artery occlusion during intralésional injection of corticosteroid into an eyelid capillary hemangioma. *Am J Ophthalmol* **121**: 638–642
- 30 Grossman W and Ward WT (1993) Central retinal artery occlusion after scoliosis surgery with a horseshoe headrest: case report and literature review. *Spine* **18**: 1226–1228
- 31 Bekar A et al. (1996) Unilateral blindness due to patient positioning during cervical syringomyelia surgery: unilateral blindness after prone positioning. *J Neurosurg Anesthesiol* **8**: 227–229
- 32 American Society of Anesthesiologists Task Force on Perioperative Blindness (2006) Practice advisory for perioperative visual loss associated with spine surgery: a report by the American Society of Anesthesiologists Task Force on Perioperative Blindness. *Anesthesiology* **104**: 1319–1328
- 33 Vinerovsky A et al. (2004) Central retinal artery occlusion after peribulbar anesthesia. *J Cataract Refract Surg* **30**: 913–915
- 34 Hayreh SS et al. (2004) Central retinal artery occlusion: retinal survival time. *Exp Eye Res* **78**: 723–736
- 35 Hayreh SS et al. (1980) Central retinal artery occlusion and retinal tolerance time. *Ophthalmology* **87**: 75–78
- 36 Hayreh SS (2005) Prevalent misconceptions about acute retinal vascular occlusive disorders. *Prog Retin Eye Res* **24**: 493–519
- 37 Augsburger JJ and Magargal LE (1980) Visual prognosis following treatment of acute central retinal artery occlusion. *Br J Ophthalmol* **64**: 913–917
- 38 Connolly BP et al. (2000) Characteristics of patients presenting with central retinal artery occlusion with and without giant cell arteritis. *Can J Ophthalmol* **35**: 379–384
- 39 Schmidt DP et al. (2002) Prognosis of central retinal artery occlusion: local intraarterial fibrinolysis versus conservative treatment. *AJNR Am J Neuroradiol* **23**: 1301–1307
- 40 Beatty S and Au-Eong KG (2000) Local intra-arterial fibrinolysis for acute occlusion of the central retinal artery: a meta-analysis of the published data. *Br J Ophthalmol* **84**: 914–916
- 41 Rosser DA et al. (2003) How sensitive to clinical change are ETDRS logMAR visual acuity measurements? *Invest Ophthalmol Vis Sci* **44**: 3278–3281
- 42 Rumelt S et al. (1999) Aggressive systematic treatment for central retinal artery occlusion. *Am J Ophthalmol* **128**: 733–738
- 43 Harino S et al. (1995) Rebreathing into a bag increases human retinal macular blood velocity. *Br J Ophthalmol* **79**: 380–383
- 44 Deutsch TA et al. (1983) Effects of oxygen and carbon dioxide on the retinal vasculature in humans. *Arch Ophthalmol* **101**: 1278–1280

- 45 Incandela L *et al.* (2002) Treatment of vascular retinal disease with pentoxifylline: a controlled, randomized trial. *Angiology* **53** (Suppl 1): S31–S34
- 46 Beiran I *et al.* (2001) Early hyperbaric oxygen therapy for retinal artery occlusion. *Eur J Ophthalmol* **11**: 345–350
- 47 Rassam SM *et al.* (1993) The effect of acetazolamide on the retinal circulation. *Eye* **7**: 697–702
- 48 Landa E *et al.* (2004) Visual functions following recovery from non-arteritic central retinal artery occlusion. *Ophthalmic Surg Lasers Imaging* **35**: 103–108
- 49 The National Institute of Neurological Disorders and Stroke rt-PA Stroke Study Group (1995) Tissue plasminogen activator for acute ischemic stroke. *N Engl J Med* **333**: 1581–1588
- 50 Furlan A *et al.* (1999) Intra-arterial prourokinase for acute ischemic stroke: the PROACT II study: a randomized controlled trial: prolyse in acute cerebral thromboembolism. *JAMA* **282**: 2003–2011
- 51 Waters RE Jr *et al.* (2003) Current perspectives on reperfusion therapy for acute ST-segment elevation myocardial infarction: integrating pharmacologic and mechanical reperfusion strategies. *Am Heart J* **146**: 958–968
- 52 Arnold M *et al.* (2005) Comparison of intra arterial thrombolysis with conventional treatment in patients with acute central retinal artery occlusion. *J Neurol Neurosurg Psychiatry* **76**: 196–199
- 53 Schumacher M *et al.* (1993) Intra-arterial fibrinolytic therapy in central retinal artery occlusion. *Neuroradiology* **35**: 600–605
- 54 Kattah JC *et al.* (2002) Intravenous recombinant tissue-type plasminogen activator thrombolysis in treatment of central retinal artery occlusion. *Arch Ophthalmol* **120**: 1234–1236
- 55 Butz B *et al.* (2003) Selective intraarterial fibrinolysis of acute central retinal artery occlusion. *Acta Radiol* **44**: 680–684
- 56 Richard G *et al.* (1999) Treatment of retinal arterial occlusion with local fibrinolysis using recombinant tissue plasminogen activator. *Ophthalmology* **106**: 768–773
- 57 Suri MF *et al.* (2007) Intra-arterial thrombolysis for central retinal artery occlusion in United States: Nationwide In-patient Survey 2001–2003. *J Neuroimaging* **17**: 339–343
- 58 Aruga J and Sanders MD (1982) Ophthalmic findings in 70 patients with evidence of retinal embolism. *Ophthalmology* **89**: 1336–1337
- 59 Bioussé V *et al.* (2007) Thrombolysis for central retinal artery occlusion. *J Neuroophthalmol* **21**: 215–230
- 60 Aldrich E *et al.* (2008) Local intraarterial fibrinolysis administered in aliquots for the treatment of central retinal artery occlusion: the Johns Hopkins Hospital experience. *Stroke* [doi:10.1161/STROKEAHA.107.505404]

**Acknowledgments**

The authors would like to thank Drs Neil Miller, Eric Aldrich, Kieran Murphy, Phillip Gailloud and Rebecca Gottesman for contributing information about the study on superselective intra-arterial thrombolysis at the Johns Hopkins Hospital, Baltimore, MD, USA. Dr Chen was supported by the American Australian Association Education Fellowship Program and the Donegan Fund for AION Research at the Wilmer Eye Institute during her fellowship at Johns Hopkins Hospital.

**Competing interests**

The authors declared no competing interests.



**APPENDIX 2** : Publication “Rudkin AK, Lee AW, Aldrich E, Miller NR, Chen CS. Clinical characteristics and outcome of current standard management of central retinal artery occlusion. *Clin Experiment Ophthalmol.* 2010;38:496-501.

## Original Article

# Clinical characteristics and outcome of current standard management of central retinal artery occlusion

Adam K Rudkin BMBS,<sup>1</sup> Andrew W Lee FRACP,<sup>2</sup> Eric Aldrich PhD,<sup>3</sup> Neil R Miller MD<sup>4</sup> and Celia S Chen FRANZCO<sup>1</sup>

<sup>1</sup>Departments of Ophthalmology, NH & MRC Centre of Clinical Eye Research and <sup>2</sup>Flinders University Comprehensive Stroke Centre, Flinders Drive, Bedford Park, South Australia, Australia; and <sup>3</sup>Department of Neurology, <sup>4</sup>Neuro-Ophthalmology Unit, Wilmer Eye Institute, The Johns Hopkins Hospital, Baltimore, Maryland, USA

### ABSTRACT

**Background:** To investigate the visual outcomes in acute central retinal artery occlusion (CRAO) with current standard therapy at two university teaching hospitals.

**Methods:** Retrospective analysis of two cohorts of CRAO patients from John Hopkins Hospital (JHH; USA), and Flinders Medical Centre (FMC; Australia), treated with current standard therapy. The outcome measures were visual acuity, and subsequent ocular and systemic ischaemic events.

**Results:** The mean follow-up period was  $11.2 \pm 13.1$  months in the JHH cohort and  $35.4 \pm 34.9$  months in the FMC cohort. The frequency distribution of vascular risk factors and the incidence of subsequent ischaemic events were similar for the patients from both institutions. All patients from JHH were treated as inpatients, whereas 79% of patients from FMC were treated as outpatients. More patients in the JHH cohort underwent paracentesis, ocular massage or were treated with intraocular hypotensive agents (76%) than in the FMC cohort (26%); however, there was no significant difference in visual outcome between the two cohorts ( $P = 0.114$ ).

**Conclusion:** Despite differences in management of CRAO between two institutions in different countries, visual outcomes were similar. This suggests a

lack of efficacy of current standard treatment in acute CRAO.

**Key words:** complication, inpatient, management, outpatient, retinal artery occlusion, visual acuity.

### INTRODUCTION

Central retinal artery occlusion (CRAO) is an ocular emergency, as it is a stroke of the eye caused by obstruction of the central retinal artery, usually by a thrombus or embolus<sup>1,2</sup> that results in painless, disabling vision loss. Treatment of CRAO is problematic as both acute and secondary preventive therapies are based on observational studies rather than randomized controlled trials. Part of the problem is the low incidence of CRAO of 1 in 10 000 ophthalmic outpatient visits.<sup>3</sup> Therefore, any randomized controlled trial would require participation by multiple centres to achieve a sufficient number of subjects needed to demonstrate efficacy of any proposed therapy. Such a trial might best be performed via an international collaboration to ensure generalizability of this therapy to a global population at risk.

As a prelude to such a trial, it would be useful to determine baseline characteristics, outcomes and current treatments for CRAO at different centres in different countries. Current acute management for CRAO varies depending on physician preference and treatment centre protocol. For instance, in some hospitals, all CRAO patients are admitted to the stroke ward for secondary vascular prevention

■ **Correspondence:** Dr Celia Chen, Department of Ophthalmology, Flinders Medical Centre and Flinders University, Flinders Drive, Bedford Park, SA 5042, Australia. Email: celia.chen@health.sa.gov.au

Received 15 September 2010; accepted 12 January 2010.

© 2010 The Authors  
Journal compilation © 2010 Royal Australian and New Zealand College of Ophthalmologists

evaluation, whereas other hospitals routinely treat CRAO as outpatients. Current treatment of acute CRAO in most hospitals and eye centres around the world includes measures such as ocular massage, paracentesis, inhalation of a mixture of 95% oxygen and 5% carbon dioxide (carbogen) and other methods aimed at reducing intraocular pressure and improving blood flow to the eye.<sup>2,4</sup> Although preliminary studies of thrombolytic agents appear promising in acute CRAO, a randomized controlled trial is needed to establish its safety, efficacy and optimal mode of administration prior to its use in standard clinical practice.<sup>5</sup>

Determining the similarities and differences in the visual outcome and treatment of CRAO across national borders would add useful information in planning such a trial. To provide these data, we investigated the current standard management used and visual outcomes in two cohorts of CRAO patients, one from Australia and one from the USA.

## METHODS

We performed a retrospective review of two cohorts of patients with acute CRAO treated in two study centres, John Hopkins Hospital (JHH) in the USA and Flinders Medical Centre (FMC) in Australia, between 1996 and 2006. The cohort of previously published CRAO patients treated with local intra-arterial thrombolytic at JHH were excluded from this analysis.<sup>6</sup> None of the FMC cohort received thrombolytic therapy.

In both groups, the diagnosis of CRAO was based on the initial ophthalmologist's clinical diagnosis of a documented visual disturbance due to a CRAO, characterized by a cherry red spot in the macula and attenuation of blood vessels on fundoscopic examination. Arteritic CRAO was excluded on clinical grounds as well as by the absence of elevated inflammatory markers, a temporal artery biopsy showing no evidence of vasculitis or a combination of these factors. Only non-arteritic/thromboembolic CRAOs were included in the analysis. Arteritic, transient and cilioretinal CRAOs were excluded in this study.

The acute management of each cohort consisted of either observation or current recommended interventions, including paracentesis, ocular massage, administration of an ocular hypotensive agent or a combination of these procedures.

Data collected included demographic details, prior medical history with a particular emphasis on the patient's current or previous vascular risk factors such as hypertension, diabetes mellitus, hypercholesterolaemia, and atrial fibrillation as well as any treatment the patient had received both before and immediately after the sentinel CRAO event. Investigation findings were documented, including

echocardiography and imaging of the carotid arteries. During the follow-up period, both ocular and systemic vascular events were documented using active ascertainment.

## Data analysed

The primary visual outcome was the best-corrected visual acuity (BCVA) at final follow-up. Visual acuity was assessed using a Snellen chart. For the purpose of analysis, these results were converted to logarithm of the minimal angle of resolution (logMAR) units. This was calculated by obtaining the logarithm of the reciprocal of the Snellen visual acuity for vision better than or equal to 5/200. If the vision was worse than 5/200, the following conversion was used: counting fingers = 1.6; hand movements = 2.0; light perception = 2.5; and no light perception = 3.0 logMAR units.<sup>7</sup> Separate outcome measures were the frequency distribution of major vascular risk factors at presentation and following the diagnosis of CRAO in the two cohorts, and the incidence of a subsequent ocular or systemic ischaemic event, such as stroke, acute coronary ischaemia or an acute peripheral vascular event.

## Statistical analysis

The BCVA in LogMAR score were expressed as continuous variables (mean  $\pm$  standard deviation), whereas dichotomous variables were expressed as a proportion or percentage. The Student's *t*-test was used, and a *P*-value less than 0.05 was considered significant. For the purpose of analysis of vascular risk factors, descriptive statistics were used.

The study was approved by the Flinders Clinical Research Ethics Committee.

## RESULTS

### Patient characteristics

There were 21 patients from the JHH cohort and 19 from the FMC group. The JHH cohort composed of 14 males and seven females. The mean age was  $56.6 \pm 16.3$  years (range: 23–90 years; median age: 65 years). The FMC cohort consisted of nine males and 10 females, with a mean age  $75.9 \pm 8.7$  years (range: 57–88 years; median: 71 years). The mean follow-up period was  $11.2 \pm 13.1$  (range: 2–56) months in the JHH cohort and  $35.4 \pm 34.9$  (range: 4–132) months in the FMC cohort. The mean time to presentation in the JHH cohort was  $25.8 \pm 20$  h compared with  $31 \pm 65$  h in the FMC cohort.

### Acute management of CRAO

Seventy-six per cent of patients in the JHH cohort received acute intervention for CRAO in the form of

**Table 1.** Acute therapy for CRAO

	JHH Group (n = 21)	FMC Group (n = 19)
No treatment	5 (24%)	14 (74%)
Paracentesis	14 (67%)	4 (21%)
Ocular hypotensive agent	10 (48%)	3 (16%)
Ocular massage	9 (43%)	3 (16%)
Average number of non-thrombolytic interventions tried	1.57 ± 1.20	0.53 ± 1.02

CRAO, central retinal artery occlusion; FMC, Flinders Medical Centre; JHH, John Hopkins Hospital.

paracentesis, ocular massage, agents to lower the intraocular pressure, or a combination of these procedures compared with 26% of FMC patients ( $P = 0.008$ ). The percentage of patients receiving each acute management of CRAO is indicated in Table 1. In the JHH cohort, six patients received all three treatments, six received two of the treatments and three received one treatment. In the FMC cohort, two patients received all three treatments, one received two treatments and two received one treatment.


### Visual outcome

The mean change in BCVA in the JHH cohort before and after treatment was 0.07 (range from  $2.04 \pm 0.57$  to  $1.97 \pm 0.77$ ;  $P = 0.724$ ). Six patients had an improvement in BCVA, nine had no change and six worsened. The mean change in BCVA before and after intervention in the FMC cohort was  $-0.19$  (range from  $1.97 \pm 0.44$  to  $2.16 \pm 0.59$ ;  $P = 0.268$ ). Two patients in this cohort had an improvement in BCVA, 11 had no change and six had a further decline. There was no statistically significant difference in the final BCVA between the two cohorts ( $P = 0.114$ ; Fig. 1).

### Vascular risk profile

There were no statistically significant differences between the two cohorts in the major vascular risk factors identified at presentation (Table 2) or diagnosed after the retinal occlusive event (Table 3). Hypertension was the most common vascular risk factor in both cohorts at the time of diagnosis.

In addition to the risk factors summarized in Table 2, a number of miscellaneous risk factors for CRAO were present in each cohort at presentation. The JHH cohort included two patients with a history of intravenous cocaine use, one patient with a history of alcohol abuse and two patients with chronic renal failure. The FMC cohort included two patients with connective tissue disorders and systemic vasculitis (scleroderma and Sjögren syndrome, respectively).



**Figure 1.** Scatter plot showing change in visual acuities in John Hopkins Hospital (JHH) and Flinders Medical Centre (FMC) groups. The change in visual acuities in the two groups approximate the line showing no change between the final to the initial best-corrected visual acuity (BCVA). There were no statistically significant difference in the final BCVA between the two cohorts.

**Table 2.** Vascular risk factors and comorbidities of patients presenting with CRAO

	JHH Cohort (n)	FMC Cohort (n)	P-value
Hypertension	62	57	0.80
Hyperlipidaemia	33	33	0.90
Diabetes mellitus	24	26	0.86
Atrial fibrillation	5	10	0.50
Cardiomyopathy or cardiac valvular disease	10	5	0.50
Personal history of vascular disease <sup>1</sup>	43	42	0.96
Family history of vascular disease	29	22	0.66
Tobacco use	38	21	0.25

<sup>1</sup>Includes a history of peripheral vascular disease, coronary artery event, ischaemic heart disease, transient ischaemic attack or stroke. CRAO, central retinal artery occlusion; FMC, Flinders Medical Centre; JHH, John Hopkins Hospital.

Sixty-three per cent of the FMC cohort and 57% of the JHH cohort had at least one new vascular risk factor found after the CRAO event. Hyperlipidaemia was the most common new vascular risk factor diagnosed after the sentinel CRAO event. Many patients required new medications or upward titration of medication for better control of their vascular risk factors (55% of FMC and 48% of JHH patients). All patients received anti-platelet therapy and in some cases anticoagulants depending on the vascular risk factors such as atrial fibrillation. In those with significant ipsilateral carotid stenosis >70%, recanalization procedures with carotid endarterectomy or stenting were performed. In addition to the risk factors diagnosed after presentation, summarized in

**Table 3.** New vascular risk factors and comorbidities of patients presenting with CRAO (diagnosed after investigation)

	JHH Cohort (%)	FMC Cohort (%)	P-value <sup>†</sup>
Hypertension <sup>‡</sup>	10	26	0.17
Hyperlipidaemia	30	42	0.38
Diabetes mellitus	5	11	0.50
Cardiomyopathy or cardiac valvular disease	19	5	0.20
Atrial fibrillation	0	0	–
Ipsilateral carotid artery stenosis			
50–69%	18	12	0.68
70–100%	12	15	0.98
Hyperhomocysteinaemia	10	5	0.53

<sup>†</sup>Student's *t*-test, two-tailed, unpaired. <sup>‡</sup>Newly diagnosed hypertension or a blood pressure amenable to further reduction to achieve an optimum level. CRAO, central retina artery occlusion; FMC, Flinders Medical Centre; JHH, John Hopkins Hospital.

Table 3, one patient in the JHH cohort had a low serum concentration of Protein C, and another had Protein S deficiency.

### Inpatient versus outpatient management

All 21 patients in the JHH cohort were evaluated and treated as inpatients on the Neurology Stroke Service. In the FMC cohort, four patients (21%) were evaluated and treated as inpatients; the remaining 15 patients (79%) were managed as outpatients. The reasons for inpatient management in the FMC cohort were as follows: two patients had already been admitted to a general medical unit for other medical conditions before an ophthalmologist was asked to assess the patient; and two patients were admitted to a general medical service after the diagnosis of CRAO for occupational therapy and social work input because of concerns that they would require additional support for safe functioning at home.

### Secondary ischaemic events

In the JHH cohort, one patient developed a stroke 3 months post-CRAO. In the FMC group, one patient developed a stroke 5 years post-CRAO on the contralateral side and one developed angina 8 months post-CRAO. The difference in outcomes was not significant ( $P = 0.944$ ). All three patients had significant vascular comorbidities including hypertension, hyperlipidaemia, tobacco use and carotid artery disease. The patient from the JHH cohort had a total internal carotid artery occlusion that was not amenable to recanalization.

### DISCUSSION

In this study, there were notable differences in the initial management of patients with CRAO between

the two institutions. JHH managed all CRAO patients as inpatients, whereas 79% of patients in the FMC cohort were managed as outpatients. Recommended treatment strategies including paracentesis, ocular massage and administration of ocular hypotensive agents were frequently used in the JHH cohort, whereas the FMC cohort tended to be observed. Despite these differences, including the significantly younger mean age of the JHH cohort, there was no significant difference in the final visual outcome between the two cohorts. Furthermore, the final visual outcome in both populations was similar to that in a large retrospective series of CRAO patients reported by Hayreh and Zimmerman.<sup>3</sup>

The most likely explanation for the lack of significant difference in the final visual acuity between our two cohorts is that the causes of the CRAO were similar in both sets of patients and that there is no benefit of the use of currently recommended interventions compared with observation in this condition. This finding is consistent with other studies that have shown that the use of paracentesis, ocular massage and acetazolamide does not alter the natural history of disease.<sup>4,5,9</sup> Furthermore, the average number of standard non-thrombolytic interventions in this study (1.57 in JHH and 0.53 and FMC) was lower compared with the average number of  $2.5 \pm 1.4$  interventions described in the literature,<sup>10</sup> but the visual outcomes were comparable, suggesting that current standard management options, whether single or in combination, do not significantly affect the visual outcome. The use of current standard treatment thus remains at the discretion of the treating ophthalmologist.

Secondary systemic ischaemic events occurred in three patients (7.5%). This rate is low compared with previous reports of stroke rates as high as 40% in CRAO patients with known extracranial internal carotid disease who were not treated with endarterectomy.<sup>11</sup> We acknowledge that a limitation of the study is its retrospective design and as such; we are unable to control for all confounders such as the relatively short follow-up period. Indeed, the mean follow-up period for the JHH cohort was 11 months. However, an alternative explanation for the low incidence of secondary systemic vascular events in the two cohorts is that all patients in both cohorts were evaluated for carotid artery disease, and all had management of their disease according to established guidelines,<sup>12</sup> including appropriate intervention for vascular risk factors as well as universal treatment with anti-platelet agents.<sup>13,14</sup>

Defining effective treatments for CRAO has been problematic as current 'standard' therapies are based on non-randomized interventional studies, often comparing outcomes with historical controls that

are non-contemporary. In addition, because of the relatively low incidence of CRAO, single-centre studies investigating the natural history and baseline characteristics have had to recruit subjects over decades. The two largest series recruited patients spanning three decades.<sup>3,15</sup> One of the criticisms of such an approach is that one must assume that both the disease phenotype and the treatment strategy remain static over a long period of time. The alternative is to analyse the same data over a shorter time interval, but in order to achieve sufficient cases in an uncommon disease such as CRAO, a multi-centre registry would have to be used. The current study, as well as providing comparative data between two institutions in two different countries, is also a first in terms of demonstrating the feasibility of an international collaboration required for a registry of cases of CRAO.

Fibrinolysis using intra-arterial or intravenous tissue plasminogen activator (tPA) is a promising new therapy in the acute management of CRAO.<sup>4,16</sup> There is robust evidence to support fibrinolysis in myocardial or cerebral ischaemia;<sup>17,18</sup> however, it has not yet been proven in a well-designed randomized controlled trial for CRAO. The potential time window for thrombolysis in CRAO is debated and thought to be longer than for treatment of ischaemic stroke where tPA is approved by the Federal Drug Administration within 3 h of stroke onset.<sup>14</sup> In primate models of CRAO,<sup>17</sup> reversing central retinal artery ischaemia within 97 min achieves complete recovery of the visual evoked potential. However, in ischaemia up to 240 min, reversal of central retinal artery ischaemia still results in partial visual evoked potential recovery. In most retrospective interventional case series, clinical improvement with tPA occurs in up to 12 h.<sup>4,6</sup> Recently, Aldrich *et al.*<sup>6</sup> reported a prospective non-randomized interventional study of tPA use in CRAO up to 15 h from the onset of CRAO. However, it is generally believed that 'time is tissue' in thrombolysis and some studies have reported efficacy with vision recovery in CRAO in those who received interventions within 6.5 h.<sup>19</sup> The time to presentation of CRAO patients in both cohorts was generally more than 24 h (25.8 ± 20 h and 31 ± 65 h, respectively), and this may have limited the potential for recovery. If a viable treatment option is available, efforts need to be made to promote patient and physician awareness of the condition and its potential treatment so that patients present within a few hours rather than a day or more after visual loss.

In conclusion, notable differences were demonstrated in the initial management of patients with CRAO in two institutions in different countries; however, despite the use of paracentesis, ocular massage and ocular hypotensive agents, visual out-

comes were similar. This suggests a lack of efficacy of current standard treatment in acute CRAO.

## REFERENCES

1. Rumelt S, Dorenboim Y, Rehany U. Aggressive systematic treatment for central retinal artery occlusion. *Am J Ophthalmol* 1999; **128**: 733–8.
2. Chen CS, Lee AW. Management of acute central retinal artery occlusion. *Nat Clin Pract Neurol* 2008; **4**: 376–83.
3. Schmidt D, Schumacher M, Felgen N. Circadian incidence of non-inflammatory retinal artery occlusions. *Graefes Arch Clin Exp Ophthalmol* 2009; **247**: 491–4.
4. Fraser SG, Adams W. Interventions for acute non-arteritic central retinal artery occlusion. *Cochrane Database Syst Rev* 2009; **1**: CD001989.
5. Felgen N, Neubauer A, Jurklics B *et al.* EAGLE-Study Group. Multicenter study of the European Assessment Group for Lysis in the Eye (EAGLE) for the treatment of central retinal artery occlusion: design issues and implications. EAGLE Study report No. 1. *Graefes Arch Clin Exp Ophthalmol* 2006; **244**: 950–6.
6. Aldrich EM, Lee AW, Chen CS *et al.* Local intraarterial fibrinolysis administered in aliquots for the treatment of central retinal artery occlusion: the Johns Hopkins Hospital experience. *Stroke* 2008; **39**: 1746–50.
7. Arroyo JG, Postel EA, Stone T, McCuen BW, Egan KM. A matched study of primary scleral buckle placement during repair of posterior segment open globe injuries. *Br J Ophthalmol* 2003; **87**: 75–8.
8. Atebara NH, Carter GC, Cater J. Efficacy of anterior chamber paracentesis and carbogen in treating acute nonarteritic central retinal artery occlusion. *Ophthalmology* 1995; **102**: 2029–35.
9. Karjalainen K. Occlusion of the central retinal artery and retinal branch arterioles. *Acta Ophthalmol* 1971; **109** (Suppl.): 1–96.
10. Mueller AJ, Meubauer AS, Schaller U, Kampik A. Evaluation of minimally invasive therapies and rationale for a prospective randomized trial to evaluate selective lysis for clinically complete central retinal artery occlusion. *Arch Ophthalmol* 2003; **121**: 1377–81.
11. Douglas DJ, Schuler JJ, Buchbinder D, Dillon BC, Flanigan DP. The association of central retinal artery occlusion and extracranial carotid artery disease. *Ann Surg* 2008; **208**: 85–90.
12. Sacco RL, Adams R, Albers G *et al.* American Heart Association/American Stroke Association Council on Stroke; Council on Cardiovascular Radiology and Intervention; American Academy of Neurology. Guidelines for prevention of stroke in patients with ischemic stroke or transient ischemic attack: a statement for healthcare professionals from the American Heart Association/American Stroke Association Council on Stroke: co-sponsored by the Council on Cardiovascular Radiology and Intervention: the American Academy of Neurology affirms the value of this guideline. *Circulation* 2006; **113**: 409–49.
13. Alberts MJ, Obviagele B. Current strategies for ischemic stroke prevention: role of multimodal combination therapies. *J Neurol* 2007; **254**: 1414–26.

14. Donnan GA, Fisher M, Macleod M, Davis SM. Stroke. *Lancet* 2008; **371**: 1612–23.
15. Schmidt D, Hetzel A, Geibel-Zehender A, Schulte-Monting J. Systemic diseases in non-inflammatory branch and central retinal artery occlusion-an overview of 416 patients. *Eur J Med Res* 2007; **12**: 595–603.
16. Noble J, Weizblit N, Baerlocher MO, Eng KT. Intra-arterial thrombolysis for central retinal artery occlusion: a systematic review. *Br J Ophthalmol* 2008; **92**: 588–93.
17. National Institute of Neurological Disease and Stroke (NINDS). Tissue plasminogen activator for acute ischemic stroke. *N Engl J Med* 1995; **333**: 1581–8.
18. Waters RE II, Mahaffey KW, Granger CB, Roe MT. Current perspectives on reperfusion therapy for acute ST-segment elevation myocardial infarction: integrating pharmacologic and mechanical reperfusion strategies. *Am Heart J* 2003; **146**: 958–68.
19. Hattenbach LO, Kuhl-Hattenbach C, Scharrer I, Baatz H. Intravenous thrombolysis with low-dose recombinant tissue plasminogen activator in central retinal artery occlusion. *Am J Ophthalmol* 2008; **146**: 700–6.

**APPENDIX 3** : Publication “Rudkin AK, Lee AW, Chen CS. Ocular neovascularization following central retinal artery occlusion: prevalence and timing of onset. *Eur J Ophthalmol.* 2010; 20(6):1042-6.”

*Eur J Ophthalmol* 2010; 20 (6): 1042-1046

---

**ORIGINAL ARTICLE**

---

## Ocular neovascularization following central retinal artery occlusion: prevalence and timing of onset

Adam K. Rudkin<sup>1</sup>, Andrew W. Lee<sup>2</sup>, Celia S. Chen<sup>1</sup>

<sup>1</sup> Department of Ophthalmology, NH&MRC Centre of Clinical Eye Research, Flinders Medical Centre and Flinders University, Adelaide, South Australia - Australia

<sup>2</sup> Flinders Comprehensive Stroke Centre, Flinders University, Adelaide - Australia

---

**PURPOSE.** Debate exists in the literature on the prevalence and etiology of neovascularization following central retinal artery occlusion (CRAO). The reported prevalence varies from 2.5% to 31.6%. We conducted a retrospective study to determine the prevalence of ocular neovascularization following acute CRAO in our institution.

**METHODS.** A retrospective audit of consecutive patients with nonarteritic/thromboembolic CRAO presenting between 1997 and 2009 in a single tertiary teaching hospital.

**RESULTS.** Thirty-three patients were identified as having nonarteritic CRAO, and of this cohort 6 patients (18.2%) developed ocular neovascularization. Neovascular glaucoma was present in 5 cases (15.2%); 2 of these presented through an emergency department with painful eyes, both at 16 weeks post CRAO. The other cases of neovascularization were detected on scheduled follow-ups. Mean time from retinal occlusive event to observed neovascularization was 8.5 weeks (range 2–16 weeks). One case of neovascularization was associated with hemodynamically significant ipsilateral carotid stenosis; no patient had proliferative diabetic retinopathy or other causes of neovascularization.

**CONCLUSIONS.** The prevalence of neovascularization following acute CRAO in our population was 18.2% at an average of 8.5 weeks post CRAO. There was a temporal relationship between the 2 events and no other causes of neovascularization demonstrable in our cohort of patients. There is no consensus on the follow-up regimen post CRAO to detect ocular neovascularization complications. Our study suggests that neovascularization can occur early and regular follow-up especially in the first 4 months is important post CRAO.

**KEY WORDS.** Neovascular glaucoma, Neovascularization of the disc, Neovascularization of the iris, Retinal artery occlusion

Accepted: April 15, 2010

### INTRODUCTION

Ocular neovascularization is a process of unregulated and misguided growth of new vessels in the eye. It is thought to occur as a result of chronic retinal ischaemia, and multiple mediators have been implicated in this process, of which the most important is vascular endothelial growth factor.

New vessels can grow into nearly all mature ocular tissue and affect cornea, iris, retina, and optic disc (1). Central retinal artery occlusion (CRAO) can result in ocular neovascularization; the most serious of these complications is the development of neovascular glaucoma (NVG). The growth of new vessels in the angle of the anterior chamber initially impairs aqueous outflow in the presence of an open angle;

however, the disease can progress and lead to formation of peripheral anterior synechiae and subsequent contraction and closure of the angle. This process can be severe and relentless, and may lead to intractable eye pain (2). Neovascular glaucoma is a commonly cited indication for enucleation or evisceration (3, 4).

The literature reports disparate rates of ocular neovascularization associated with CRAO. These range from as low as 2.5% to as high as 31.6% (5, 6). The causal association of CRAO and ocular neovascularization has therefore been challenged (7). Critics of this association argue that in CRVO there is chronic retinal hypoxia, whereas in CRAO there is acute, severe retinal ischemia. It is suggested that only chronic retinal hypoxia may liberate vasoproliferative growth factor, a process not present in CRAO (8). It is thus proposed that other factors, including diabetes mellitus and ocular ischemic syndrome, are responsible for the occurrence of neovascularization following CRAO (7).

We present a case series of patients with thromboembolic CRAO, and describe the prevalence of ocular neovascularization. We conducted a thorough analysis of the patient series in terms of timing of neovascularization post CRAO and comorbidities to determine whether another cause of neovascularization was likely to be present.

## METHODS

A retrospective review of a cohort of patients with CRAO admitted to the Flinders Medical Centre between January 1997 and January 2009 was conducted. The diagnosis of CRAO was based on the initial ophthalmologist's clinical diagnosis with documented visual disturbance due to retinal artery occlusion with evidence of a cherry red spot and attenuation of blood vessels on funduscopic examination. Arteritic CRAO was excluded either clinically based on the presence of symptoms and the presence of an elevated erythrocyte sedimentation rate or where possible on temporal artery biopsy. A single observer (A.K.R.) extracted data from the case notes. Data collected included basic demographic details, comorbidities, timing of the initial presentation with CRAO, and timing and type of ocular neovascularization. Results from Doppler ultrasonography records and computer tomographic angiography (CTA) for patients with neovascularization were recorded.

Informed consent was obtained and the authors followed all the guidelines for experimental investigations required

by the Southern Adelaide Health Ethics Committee with which all authors are affiliated.

## Definitions

We define the term neovascularization of the iris (NVI) as the abnormal formation of new blood vessels on the anterior surface of the iris, with no associated elevation in intraocular pressure (IOP).

Neovascularization of the disc (NVD) was defined as the presence of abnormal new blood vessels on the optic disc, associated with early leakage on fundus fluorescein angiography. Neovascular glaucoma (NVG) was used to refer to patients with NVI, proliferation of neovascular tissue over the angle, and an IOP greater than 28 mm Hg. We use the same threshold for an elevated IOP as another large case series (9).

A hemodynamically significant carotid artery stenosis was defined as a carotid artery stenosis of greater than 70% according to either ultrasound or angiographic criteria (10).

## RESULTS

Thirty-three patients, mean age  $73 \pm 9.7$  years, were identified as having thromboembolic CRAO. The vascular risk profile of this cohort has been previously reported (11).

The prevalence of ocular neovascularization was 18.2% (6/33). The mean age of this group was 76.7 years (range 57.1–85.1). Details are reported in Table I. Five of these cases had NVI and each had progressed to NVG. Thus the point prevalence of NVG is 15.2% (5/33). One case had NVD detected on routine follow-up at 2 weeks and confirmed on fundus fluorescein angiogram; neovascularization was not seen at the iris (NVI) or elsewhere (NVE).

The mean time to diagnosis of neovascularization in our cohort was 8.5 weeks (range 2–16 weeks). Cases 2 and 5 re-presented to an emergency ophthalmology clinic with ipsilateral eye pain (both at 16 weeks) and were diagnosed with NVG. In the remaining cases, diagnosis of neovascularization was made on a scheduled review. The mean time from onset of visual loss to ocular neovascularization was 8.5 weeks (range 2–16 weeks).

Atherosclerotic narrowing of the carotid vessels was evaluated in each case with Doppler ultrasound (Tab. I). An ipsilateral hemodynamically significant carotid stenosis was documented in a single patient (case 3), who subsequently



underwent an ipsilateral carotid endarterectomy. All cases were evaluated with a fundus fluorescein angiogram at the point neovascularization was noted. There were no choroidal filling defects to suggest involvement of the ophthalmic artery and the posterior ciliary artery. Four patients with NVG post CRAO had type II diabetes mellitus. In one case, this was diagnosed after present-

ing with CRAO; one case was diet-controlled; both cases were managed with oral hypoglycemic agents. No patient, however, had evidence of diabetic retinopathy in either the ipsilateral or contralateral eye.

All patients underwent panretinal photocoagulation (PRP) as treatment for ocular neovascularization. In case 2, persistently elevated pressures and chronic eye pain necessi-

**TABLE I - CASES OF OCULAR NEOVASCULARIZATION**

Case	NVI	NVG	Peak IOP, mm Hg	NVD	Time from onset of CRAO, wk	Ipsilateral carotid stenosis (Doppler US), %	Vascular risk factors	Management of NV
1	Not seen	Absent	16	Present	2	30-40	Hypertension, DMII, smoking	PRP
2	Present	Present	38	Absent	16	50	DMII	PRP + trabeculectomy
3	Present	Present	40	Present	6	70	Hypertension, hyperlipidemia, carotid stenosis (>70%)	PRP
4	Present	Present	35	Absent	6	20-40	Hypertension, hyperlipidemia, DMII	PRP
5	Present	Present	36	Present	16	<20	Hypertension, hyperlipidemia, DMII	PRP
6	Present	Present	70	Present	5	50	Hypertension, hyperlipidemia	PRP

CRAO = central retinal artery occlusion; DMII = type II diabetes mellitus; NVD = neovascularization of the disc; NVG = neovascular glaucoma; NVI = neovascularization of the iris; US = ultrasound.

**TABLE II - INCIDENCE OF NVI WITH/WITHOUT NVG FOLLOWING CRAO**

Study	No. of eyes	Prevalence of NVI ± NVG	Timing	Methodology
Hayreh and Podhajsky, 1982 (8)	64*	18.8% (n=12)	Range: on presentation-10 months	Retrospective case series (study period unstated)
Duker and Brown, 1988 (12)	168	16.7% (n=28)	Mean 4 weeks; range: 1-12 weeks	Retrospective case series (1977-1987)
Duker et al, 1991 (9)	33	16.6% (n=6)	Mean 5.5 weeks; range: 12 days-12 weeks	Prospective case series (18-month study)
Kattah et al, 2002 (6)	19	31.6% (n=6)†	All cases within 31 days	Prospective case series (primarily evaluating thrombolysis, 1998-2000)
Schäfer and Lang, 2005 (13)	27	18.5% (n=5)	Range: 2 months-2 years	Retrospective case series (2-year study)
Hayreh et al, 2009 (7)	232*	3.0% (n=7)‡	Not stated	Retrospective case series (1973-2000)
Sagong et al, 2009 (5)	36	19.4% (n=7)	Range: 2-5 weeks (of the 3 cases described in detail)	Retrospective case series (2004-2008)

\*The 2 studies with Hayreh as primary author examine an overlapping patient cohort.

†Four of 12 patients undergoing thrombolysis had NVI ± NVG; 2/7 patients who were not treated with thrombolysis had NVI ± NVG. Consideration must be given to the hypothesis that thrombolysis may have altered the natural history of the disease and led to higher rates of neovascularization.

‡Includes a single patient described as having NVG with ocular ischemia.

CRAO = central retinal artery occlusion; NVD = neovascularization of the disc; NVG = neovascular glaucoma; NVI = neovascularization of the iris.

tated a trabeculectomy. In the remaining cases, a satisfactory reduction in IOP was observed following PRP with no pain, and no further interventions were required.

## DISCUSSION

Our series shows an 18.2% prevalence of neovascularization post CRAO with a mean time of onset at 8.5 weeks. A search for articles published since 1980 on the rate of NVI or NVG following CRAO found 7 studies (Tab. II). There is a wide variation in the reported prevalence, from 3.0% to 28.2%. The median prevalence of these reported studies is 18.6%. This is consistent with the estimated point prevalence of neovascularization in our own patient cohort. The majority of the reported studies, including our own, were retrospective. Duker et al, however, conducted an 18-month prospective cohort study examining the prevalence of neovascularization and factors which may be attributable to its development and documented neovascularization in 16.6% of cases (9). This is similar to the prevalence reported in their larger retrospective cohort study of 168 eyes.

In our study, the mean time to neovascularization was 8.5 weeks, which is slightly longer than the 5.5 weeks found in a prospective study with fixed interval follow-up reviews following acute CRAO (12). Nevertheless, our study is in keeping with previous data that suggest that neovascularization tends to occur early following CRAO. The timing of neovascularization in other studies is detailed in Table II. The follow-up regimen post CRAO has not been well-defined and partly due to the unknown clinical course of the ocular complications. In contrast, NVG is a well-recognized complication in people with central retinal vein occlusion (CRVO), and is sometimes referred to as 100-day glaucoma (13). Current guidelines recommend close follow-up for patients with CRVO to measure IOP and investigate for neovascularization, especially in the first 6 months (14). Our series, in keeping with other reported series, suggests that neovascularization in CRAO occurs earlier and can be as early as 2 weeks (2, 9). This suggests the need for close follow-up especially in the initial stages post CRAO. Early intervention with panretinal photocoagulation when NVD and NVI are detected could prevent NVG.

One of the problems inherent in the current literature relating to neovascularization in CRAO is that the estimates of the point prevalence vary considerably. Some of this may

be due to the differing definitions of neovascularization; for instance, some authors report the point prevalence of NVI as opposed to NVG. Similarly, in the definition of NVG, the upper threshold of an "elevated" IOP is not stated by many investigators; NVG often occurs in a continuum from NVI to proliferation of the angle that then results in secondary reduction in aqueous drainage and hence elevated IOP.

The prevalence of NVD is not a commonly recorded complication of CRAO. Duker et al reported an incidence of 1.8% from a retrospective study of 168 patients with CRAO, and 3.0% in a prospective study of 33 patients (9, 15). The observation of NVD in 12.2% in our cohort is comparatively high. This may be a bias of small sample size, though it may represent underreporting in some studies secondary to follow-up methodology, or a variation secondary to the investigators' definition for NVD.

In our study, we observed a causal relationship between CRAO and ocular neovascularization based on the timing between the 2 events and the absence of other contributing factors to neovascularization. In our study, in each of the 6 cases of ocular neovascularization there were no concurrent clinical features of ocular ischemia. Only one of 6 patients had a hemodynamically significant stenosis of the internal carotid artery and we could not see any evidence of ophthalmic artery ischemia based on fundus fluorescein angiography at the time of neovascularization. There were 4 patients who had diabetes mellitus type II, but none had evidence of diabetic retinopathy in either eye.

## CONCLUSIONS

In our cohort, the overall rate of neovascularization was 18.2%. Consistent with the majority of other studies, we demonstrated a clear empirical correlation between thromboembolic CRAO and NVI. The majority (4 of 5) of cases of NVI progressed to NVG. In the majority of cases of neovascularization there were no clinical features of ocular ischemia, and no association with a hemodynamically significant stenosis of the carotid artery. Given the association between neovascularization and CRAO, prudent clinical practice would be to review all patients with acute CRAO at regular intervals as early as 2 weeks and up to 4 months post CRAO.

*The authors report no proprietary interest or financial support.*

Address for correspondence:  
Celia Chen, MD  
Department of Ophthalmology  
Flinders Medical Centre and Flinders University  
Flinders Drive  
Bedford Park  
Adelaide, South Australia  
5042, Australia  
Celia.Chen@health.sa.gov.au

---

## REFERENCES

1. Lee P, Wang CC, Adamis AP. Ocular neovascularization: an epidemiologic review. *Surv Ophthalmol* 1998; 43: 245-69.
2. Shazly TA, Latina MA. Neovascular glaucoma: etiology, diagnosis and prognosis. *Semin Ophthalmol* 2009; 24: 113-21.
3. de Gottrau P, Holbach LM, Naumann GO. Clinicopathological review of 1146 enucleations (1980-90). *Br J Ophthalmol* 1994; 78: 260-5.
4. Saeed MU, Chang BYP, Khandwala M, Shivane AG, Chakrabarty A. Twenty year review of histopathological findings in enucleated/eviscerated eyes. *J Clin Pathol* 2006; 59: 153-5.
5. Sagong M, Kim J, Chang W. Intravitreal bevacizumab for the treatment of neovascular glaucoma associated with central retinal artery occlusion. *Korean J Ophthalmol* 2009; 23: 215-8.
6. Kattah JC, Wang DZ, Reddy C. Intravenous recombinant tissue-type plasminogen activator thrombolysis in treatment of central retinal artery occlusion. *Arch Ophthalmol* 2002; 120: 1234-6.
7. Hayreh SS, Podhajsky PA, Zimmerman MB. Retinal artery occlusion: associated systemic and ophthalmic abnormalities. *Ophthalmology* 2009; 116: 1928-36.
8. Hayreh SS, Podhajsky P. Ocular neovascularization with retinal vascular occlusion: II: Occurrence in central and branch retinal artery occlusion. *Arch Ophthalmol* 1982; 100: 1585-96.
9. Duker JS, Sivalingam A, Brown GC, Reber R. A prospective study of acute central retinal artery obstruction: the incidence of secondary ocular neovascularization. *Arch Ophthalmol* 1991; 109: 339-42.
10. North American Symptomatic Carotid Endarterectomy Trial Collaborators. Beneficial effect of carotid endarterectomy in symptomatic patients with high-grade carotid stenosis. *N Engl J Med* 1991; 325: 445-53.
11. Rudkin AK, Lee AW, Chen CS. Vascular risk factors for central retinal artery occlusion. *Eye* 2010; 24: 678-81.
12. Duker JS, Brown GC. Iris neovascularization associated with obstruction of the central retinal artery. *Ophthalmology* 1998; 95: 1244-50.
13. Schäfer S, Lang GE. Iris neovascularization as a complication of central artery occlusion. *Klin Monatsbl Augenheilkd* 2005; 222: 343-5.
14. The Central Vein Occlusion Study Group. Natural history and clinical management of central retinal vein occlusion. *Arch Ophthalmol* 1997; 115: 486-91.
15. Duker JS, Brown GC. Neovascularization of the optic disc associated with obstruction of the central retinal artery. *Ophthalmology* 1989; 96: 87-91.



## Vascular risk factors for central retinal artery occlusion

AK Rudkin<sup>1</sup>, AW Lee<sup>2</sup> and CS Chen<sup>1</sup>

### Abstract

**Purpose** To determine the proportion of patients presenting with thromboembolic central retinal artery occlusion (CRAO) who had undiagnosed vascular risk factors amenable to modification.

**Methods** A retrospective audit of consecutive patients with non-arteritic/thromboembolic CRAO presenting between 1997 and 2008 in a single tertiary teaching hospital.

**Results** Thirty-three patients with non-arteritic CRAO were identified. Twenty-one patients (64%) had at least one new vascular risk factor found after the retinal occlusive event, with hyperlipidemia being the most common undiagnosed vascular risk factor at the time of the sentinel CRAO event (36%). Nine patients (27%) had newly diagnosed hypertension or previous diagnosis of hypertension but not optimally controlled. To better control their vascular risk factors 18 patients (54%) were given a new or altered medication. Nine patients had more than 50% of ipsilateral carotid stenosis; six of these proceeded with carotid endarterectomy or stenting. One patient had significant new echocardiogram finding. Systemic ischaemic event post CRAO occurred in two patients with stroke and acute coronary syndrome.

**Conclusions** Patients presenting with CRAO often have a previously undiagnosed vascular risk factor that may be amenable to medical or surgical treatment. As this population is at a high risk of secondary ischaemic events, risk factor modification is prudent.

*Eye* (2010) 24, 678–681; doi:10.1038/eye.2009.142; published online 12 June 2009

**Keywords:** (MeSH):retinal artery occlusion; risk factors; arteriosclerosis; carotid artery stenosis; endarterectomy; carotid

### Introduction

Central retinal artery occlusion (CRAO) is defined as an occlusion of the central retinal

artery usually by a fibrin-platelet thrombus or embolus with resultant reduced perfusion to the retina and painless visual loss that is frequently irreversible.<sup>1,2</sup>

CRAO by virtue of its pathogenesis shares important risk factors with other vascular diseases such as ischaemic heart disease and cerebrovascular disease.<sup>3</sup> It is known from the study of heart disease and stroke, that following the occurrence of a sentinel vascular event, the patient is more likely to develop subsequent vascular events.<sup>4,5</sup> Similarly, CRAO may also be the harbinger of a more serious vascular event.<sup>6,7</sup> The current management of CRAO is aimed at secondary prevention to prevent another ischemic event.

The aim of this paper is to quantify the pre-existing vascular risk factors in a cohort of patients with CRAO and determine the undiagnosed vascular risk factors amenable to modification following the CRAO event.

### Methods

An audit of a cohort of CRAO patients admitted to the Flinders Medical Centre between January 1997 and September 2008 was conducted. The diagnosis of CRAO was based on the initial ophthalmologist's clinical diagnosis with documented visual disturbance due to retinal artery occlusion with evidence of a cherry red spot and attenuation of blood vessels on funduscopic examination. Arteritic CRAO was excluded either clinically based on the presence of symptoms and the presence of an elevated ESR or where possible on temporal artery biopsy.

A single observer abstracted data from the case notes. Data that were collected included demographic details, the previous medical history with a particular emphasis on a subject's previous risk factors such as hypertension, diabetes, hypercholesterolemia, the presence of atrial fibrillation as well as treatment that the patient had received both before and after the

<sup>1</sup>Department of Ophthalmology, Flinders Medical Centre, Flinders Drive, South Australia, Australia

<sup>2</sup>Flinders Comprehensive Stroke Centre, Flinders Medical Centre and Flinders University, Flinders Drive, South Australia, Australia

Correspondence: CS Chen, Department of Ophthalmology, Flinders Medical Centre and Flinders University, Flinders Drive, Bedford Park, South Australia 5042, Australia  
Tel: +61 882 044 899;  
Fax: +61 882 770 899;  
E-mail: Celia.Chen@health.sa.gov.au

Received: 30 January 2009  
Accepted in revised form: 11 May 2009  
Published online: 12 June 2009

sentinel CRAO event. A haemodynamically significant carotid artery stenosis was defined as a carotid artery stenosis of more than 70% according to either ultrasound or angiographic criteria.<sup>8</sup> Information on revascularisation procedures was also recorded. In addition, passive ascertainment was used to determine patient outcomes in the years following the initial event with particular emphasis on subsequent vascular events of either the retinal arteries or other vascular beds.

For the purpose of analysis, descriptive statistics were used. Continuous variables are expressed as mean  $\pm$  SD whereas dichotomous variables are expressed as a proportion or percentage.

## Results

Thirty-three patients, mean age  $73 \pm 9.7$  years, with acute loss of vision due to CRAO were reviewed.

### Vascular risk factors and co-morbidities

Hypertension was the most common vascular risk factor in subjects with CRAO (Table 1) followed by hyperlipidemia. The diagnosis of these was based on documented past medical history recorded in case notes. On average, most patients had  $2.4 \pm 1.6$  number of known vascular risk factors at the time of CRAO diagnosis. Table 1 summarises the vascular risk factors present in our study population.

At the time of CRAO diagnosis, five patients (15%) had already had an episode of amaurosis fugax and one had a branch retinal artery occlusion in the same eye (3%) before the CRAO event. Five patients (15%) had a history of stroke or transient ischaemic attack on the ipsilateral side and 12 (36%) had ischaemic heart disease.

**Table 1** Vascular risk factors at the time of CRAO diagnosis

Vascular risk factors	At the time of CRAO diagnosis (%)
Hypertension	14 (42)
Hyperlipidemia	12 (36)
Tobacco use	12 (36)
Family history of vascular disease	8 (24)
Diabetes Mellitus	7 (21)
Atrial fibrillation <sup>a</sup>	3 (9)
Cardiomyopathy or valvular disease <sup>b</sup>	3 (9)

<sup>a</sup>Include one patient with known atrial fibrillation and on warfarin, but whose INR was subtherapeutic at the time of CRAO.

<sup>b</sup>Includes one instance of aortic stenosis, one of aortic insufficiency, one of congestive cardiac failure, one of moderate left atrial dilatation with atrial fibrillation.

### Previously undiagnosed vascular risk factors and treatment

Twenty-one patients (64%) had at least one new vascular risk factor found after the retinal occlusive event.

Hyperlipidemia was the most common undiagnosed vascular risk factor at the time of the sentinel CRAO event found in 12 patients (36%), followed by hypertension nine patients (27%), and diabetes mellitus in four patients (12%) (Table 2). Eighteen patients (55%) required either a new medication or upward titration of their dose.

In two instances, patients presenting with CRAO had more complex risk factors. The youngest patient, aged 50 years at presentation, had a history of hypertension, hyperlipidemia, and on further investigation was found to have elevated homocystein levels. One patient had uncontrolled accelerated hypertension from underlying renal artery stenosis that was diagnosed after the CRAO event and referral to an internal physician.

### Carotid artery disease and cardiac diseases

Duplex doppler examination of the carotid arteries was carried out on all patients. Five patients (15%) had significant carotid artery stenosis ( $\geq 70\%$ ) ipsilateral to the retinal occlusion; four proceeded with carotid endarterectomy, and one patient, because of perioperative risks, had carotid stenting (Table 3). Four patients (12%) had moderate carotid narrowing (51–69%); one of these individuals proceeded with carotid endarterectomy after consultation with a vascular surgeon and a stroke physician, given recurrent ipsilateral ischaemic symptoms. All the carotid recanalisation surgery was performed within 1 month of the sentinel CRAO event. One patient had an ipsilateral CEA before presentation with CRAO.

A transthoracic echocardiogram was performed in 29 of 33 patients (88%) to investigate for possible

**Table 2** Vascular risk factors found after the sentinel CRAO event

Vascular risk factors	After CRAO diagnosis (%)
Hyperlipidemia	12 (36)
Hypertension <sup>*</sup>	9 (27)
Diabetes Mellitus	4 (12)
Atrial fibrillation	1 (3)
Cardiomyopathy or valvular disease	1 (3)
Hyperhomocysteinemia	1 (3)
Renal artery stenosis (atherosclerotic)	1 (3)

<sup>\*</sup>Newly diagnosed hypertension or a blood pressure amenable to further reductions to achieve an ideal blood pressure.

**Table 3** Summary of carotid artery disease and treatment

<i>Ipsilateral carotid artery stenosis</i>	<i>Number (%)</i>	<i>Number treated for carotid recanalization</i>
70–100%	5 (15)	4 with carotid endarterectomy 1 with carotid stenting
50–69%	4 (12)	1
<50%	23 (70)	0
Previous carotid surgery	1 (3)	N/A

cardio-embolic causes of retinal occlusion.<sup>9</sup> In one case, echocardiogram revealed previously undiagnosed moderate left atrial enlargement associated with atrial fibrillation, resulting in oral anticoagulation.

#### *Systemic vascular events in follow-up period*

The average follow-up period in this study is  $35.4 \pm 34.9$  months (range 4–132). One patient (3%) experienced a stroke on the contralateral vascular territory 5 years later. One patient (3%) developed chest pain and shortness of breath 8 months after the CRAO presentation. Subsequent investigation showed she had an anterior myocardial infarction and she was treated with angioplasty.

#### **Discussion**

Like stroke and ischaemic heart disease, retinal ischaemia due to CRAO is caused by a platelet fibrin clot or in rare instances, pure cholesterol emboli.<sup>10</sup> The ultimate source of these thrombi or emboli is atherosclerotic disease and thus the same risk factors that predispose to atherosclerotic disease are prevalent in patients with CRAO.<sup>11</sup> In our own cohort, hypertension is the most prevalent risk factor at presentation, a similar finding to a recent large case series of CRAO.<sup>12</sup> However, a significant proportion of individuals also had carotid artery stenoses that were amenable to immediate carotid intervention, in addition to a proportion of individuals with 50–69% stenoses where carotid intervention is a potential option.<sup>13</sup>

In addition to known risk factors documented before presentation of CRAO, there are also a significant number of individuals with previously undiagnosed vascular risk factors. In some individuals escalation of existing antihypertensive medication or the addition of further vascular preventative medication was required. Although it is not known whether the use of antihypertensives, antiplatelets or cholesterol-lowering agents will reduce the risk of a subsequent CRAO based on definitive randomised controlled trials, such agents

are accepted as standard clinical practise for the secondary prevention of stroke or ischaemic heart disease.<sup>14,15</sup> In our study, one patient developed a cerebral stroke following the CRAO and one patient developed symptoms related to ischaemic heart disease. Therefore the presentation of a CRAO while being rare given its overall incidence, nevertheless has serious complications associated with the increased subsequent incidence of vascular disease involving important end organs such as the brain and heart.

CRAO as a disease process is considered an ocular emergency, however, treatment in the past has been limited by the lack of effective acute treatments supported by robust evidence.<sup>16</sup> This coupled with its low incidence has resulted in clinicians ignoring the potential for secondary prevention of further ocular ischaemic events as well as stroke and heart disease. This is reflected by the fact that although there is voluminous guideline level literature on the treatment of heart disease, stroke and peripheral vascular disease, equivalent literature is lacking for CRAO. Our audit of a prospective cohort of CRAO patients is important for two reasons. First, it supports the existing literature that shows the presence of a significant burden of pre-existing vascular risk factors that are present before CRAO headed by hypertension.<sup>1,3,9,17</sup> In addition, our study also shows that in a significant proportion of cases the control of such risk factors is inadequate as 55% (18 of 33 patients) required either the addition or escalation of existing macrovascular preventative medications in the follow-up period following CRAO. The second important aspect of this study is that it demonstrates that CRAO is not a benign disease, but is a marker for subsequent vascular disease, such as stroke and ischaemic heart disease with known attendant significant morbidity and mortality. The fact that 6% of CRAO patients in our cohort went on to have a cerebral stroke mirrors in magnitude the risk of transient ischaemic attacks (TIA) proceeding on to a completed stroke.<sup>4</sup> This calls for a need for aggressive pharmacotherapy for secondary prevention of an ischaemic event. Referral to a dedicated vascular physician whether it be a stroke neurologist, cardiologist or internal medicine specialist would facilitate such therapy in addition to ongoing ophthalmology input.

Not only is CRAO followed by ischaemia in other organs but it is often preceded by warning symptoms of retinal ischaemia. In our cohort, 18% of individuals (6 of 33 patients) had either preceding symptoms of transient monocular blindness or evidence of branch retinal artery occlusion. Over half of the patients (51%) also had previous end organ ischaemia, such as ischaemic heart disease or stroke. These sentinel events if recognised early afford the clinician not only the opportunity to

prevent a CRAO, but by starting antiplatelets, antihypertensive or cholesterol-lowering agents also reduce the burden of subsequent disease in other vascular beds, such as subsequent stroke or retinal artery occlusion.<sup>12,18,19</sup>

### Conclusion

A high proportion of patients presenting with CRAO often have an undiagnosed vascular risk factor. In this study, 64% of patients have at least one undiagnosed vascular risk factor and a significant proportion required either the addition or escalation of existing macrovascular preventative medications and 18% required surgical intervention for carotid recanalisation. As this population is at high risk of secondary ischaemic events, risk factor modification is prudent to prevent further ischaemic events.

### References

- Rumelt S, Dorenboim Y, Rehany U. Aggressive systematic treatment for central retinal artery occlusion. *Am J Ophthalmol* 1999; **128**: 733–738.
- Chen C, Lee A. Management of acute central retinal artery occlusion. *Nat Clin Pract Neurol* 2008; **4**: 376–383.
- Schmidt D, Schulte-Mönting J, Schumacher M. Prognosis of central retinal artery occlusion: local intraarterial fibrinolysis versus conservative treatment. *AJNR Am J Neuroradiol* 2002; **23**: 1301–1307.
- Giles MF, Rothwell PM. Risk of stroke early after transient ischaemic attack: a systematic review and meta-analysis. *Lancet Neurol* 2007; **6**: 1063–1072.
- Giannuzzi P, Temporelli PL, Marchioli R. Global secondary prevention strategies to limit event recurrence after myocardial infarction: results of the GOSPEL study, a multicenter, randomized controlled trial from the Italian Cardiac Rehabilitation Network. *Arch Intern Med* 2008; **168**: 2194–2204.
- Chawluk JB, Kushner MJ, Bank WJ, Silver FL, Jamieson DG, Bosley TM et al. Atherosclerotic carotid artery disease in patients with retinal ischemic syndromes. *Neurology* 1988; **38**: 858.
- Recchia FM, Brown GC. Systemic disorders associated with retinal vascular occlusion. *Curr Opin Ophthalmol* 2000; **11**: 462–467.
- North American Symptomatic Carotid Endarterectomy Trial (NASCET) Collaborators. Beneficial effect of carotid endarterectomy in symptomatic patients with high-grade carotid stenosis. *N Engl J Med* 1991; **325**: 445–453.
- Gaunt M, Davis P, Lee AG, Lee MS. Getting to the heart of the matter. *Surv Ophthalmol* 2008; **53**: 636–640.
- Babikian V, Wijman C, Koleini B. Retinal ischemia and embolism. Etiologies and outcomes based on a prospective study. *Cerebrovasc Dis* 2001; **12**: 108–113.
- Wong TY, Klein R. Retinal arteriolar emboli: epidemiology and stroke risk. *Curr Opin Ophthalmol* 2002; **13**: 142–146.
- Schmidt D, Hetzel A, Geibel-Zehender A, Schulte-Mönting J. Systemic diseases in non-inflammatory branch and central retinal artery occlusion—an overview of 416 patients. *Eur J Med Res* 2007; **12**: 595–603.
- Barnett H, Taylor D, Eliasziw M, Fox AJ, Ferguson GG, Haynes RB et al. Benefit of carotid endarterectomy in patients with symptomatic moderate or severe stenosis. North American Symptomatic Carotid Endarterectomy Trial Collaborators. *N Engl J Med* 1998; **339**: 1415–1425.
- Graham GD. Secondary stroke prevention: from guidelines to clinical practice. *J Natl Med Assoc* 2008; **100**: 1125–1137.
- Paciaroni M, Hennerici M, Agnelli G, Bogousslavsky J. Statins and stroke prevention. *Cerebrovasc Dis* 2007; **24**: 170–182.
- Fraser SG, Adams W. Interventions for acute non-arteritic central retinal artery occlusion. *Cochrane Database Syst Rev* 2009; (1): CD001989.
- Hayreh S, Zimmerman B, Kimuraa A, Sanon A. Central retinal artery occlusion. Retinal survival time. *Exp Eye Res* 2004; **78**: 723–736.
- Romano JG, Sacco RL. Progress in secondary stroke prevention. *Ann Neurol* 2008; **63**: 418–427.
- Campbell DJ. A review of Perindopril in the reduction of cardiovascular events. *Vasc Health Risk Manag* 2006; **2**: 117–124.

Appendix 5 : Publication “Aldrich EM, Lee AW, Chen CS, Gottesman RF, Bahouth MN, Gailloud P, Murphy K, Wityk R, Miller NR. Local Intraarterial Fibrinolysis Administered in Aliquots for the Treatment of Central Retinal Artery Occlusion. The Johns Hopkins Hospital Experience. *Stroke*. 2008; 39(6):1746-50.”

## Local Intraarterial Fibrinolysis Administered in Aliquots for the Treatment of Central Retinal Artery Occlusion The Johns Hopkins Hospital Experience

Eric M. Aldrich, MD, PhD; Andrew W. Lee, MBBS, FRACP;  
Celia S. Chen, MBBS, FRANZCO, MPH; Rebecca F. Gottesman, MD, PhD;  
Mona N. Bahouth, MSN, CRNP; Phillippe Gailloud, MD; Kieran Murphy, MD;  
Robert Wityk, MD; Neil R. Miller, MD, FACS

**Background and Purpose**—Central retinal artery occlusion results in acute visual loss with poor spontaneous recovery. Current standard therapies do not alter the natural history of disease. Several open-label clinical studies using continuous infusion of thrombolytic agents have suggested that local intraarterial fibrinolysis (LIF) is efficacious in the treatment of central retinal artery occlusion. The aim is to compare the visual outcome in patients with acute central retinal artery occlusion of presumed thromboembolic etiology treated with LIF administered in aliquots with that of patients treated with standard therapy.

**Methods**—We conducted a single-center, nonrandomized interventional study of consecutive patients with acute central retinal artery occlusion from July 1999 to July 2006.

**Results**—Twenty-one patients received LIF and 21 received standard therapy. Seventy-six percent of subjects in the LIF group had a visual acuity improvement of one line or more compared with 33% in the standard therapy group ( $P=0.012$ , Fisher exact). Multivariate logistic regression controlling for gender, history of prior stroke/transient ischemic attack, and history of hypercholesterolemia showed that patients who received tissue plasminogen activator were 36 times more likely to have improvement in visual acuity ( $P=0.0001$ ) after adjusting for these covariates. Post hoc analysis showed that patients who received tissue plasminogen activator were 13 times more likely to have improvement in visual acuity of 3 lines or more ( $P=0.03$ ) and 4.9 times more likely to have a final visual acuity of 20/200 or better ( $P=0.04$ ). Two groin hematomas were documented in the LIF group. No ischemic strokes, retinal or intracerebral hemorrhages were documented.

**Conclusions**—LIF administered in aliquots is associated with an improvement in visual acuity compared with standard therapy and has few side effects. (*Stroke*. 2008;39:1746-1750.)

**Key Words:** retinal artery occlusion ■ thrombolytic therapy ■ tissue plasminogen activator

Central retinal artery occlusion (CRAO), a cause of acute visual loss, occurs in one per 10 000 ophthalmology outpatient visits.<sup>1</sup> The visual prognosis of CRAO is poor with 61% of patients having a final visual acuity (VA) of 20/400 or worse.<sup>2</sup> This degree of severe unilateral visual impairment is associated with limitations in social functioning, poor mental health,<sup>3</sup> and is a risk factor for becoming dependent.<sup>4</sup> Most CRAOs are thought to be caused by thrombosis or embolism.<sup>5</sup> Standard therapies for acute CRAO include ocular massage, paracentesis, and other methods of reducing intraocular pressure as well as inhalation of a mixture of 95% oxygen and 5% carbon dioxide (carbogen). These treatments

have not been shown conclusively to improve visual acuity beyond the natural history of disease.<sup>6,7</sup>

Systemic and intraarterial thrombolysis have been successful in restoring perfusion to ischemic tissue by fibrin-platelet clot lysis in ischemic stroke and myocardial infarction.<sup>8–10</sup> In several open-label studies, local intraarterial fibrinolysis (LIF) was efficacious in the treatment of CRAO, with up to 60% to 70% of treated subjects experiencing an improvement in VA.<sup>11–15</sup>

Most studies of LIF therapy in CRAO have used a continuous infusion of the thrombolytic agent.<sup>12</sup> Despite the efficacy of LIF in restoring VA in CRAO, concerns remain

Received September 24, 2007; final revision received October 29, 2007; accepted November 5, 2007.

From the Department of Neurology (E.M.A., A.W.L., R.F.G., M.N.B., R.W.) and the Neuro-Ophthalmology Unit (C.S.C., N.R.M.), Wilmer Eye Institute, The Johns Hopkins Hospital, Baltimore, Md; and the Division of Interventional Neuroradiology, Department of Radiology (P.G., K.M.), The Johns Hopkins Hospital, Baltimore, Md.

E.M.A., A.W.L., and C.S.C. contributed equally to this study.

Correspondence to Eric M. Aldrich, MD, PhD, or Andrew W. Lee, MBBS, FRACP, Department of Neurology, Meyer 6-109, Johns Hopkins Hospital, 600 North Wolfe Street, Baltimore, MD 21287. E-mail ealdrich@jhmi.edu or awmlee1@gmail.com

© 2008 American Heart Association, Inc.

*Stroke* is available at <http://stroke.ahajournals.org>

DOI: 10.1161/STROKEAHA.107.505444



with its use in clinical practice. First, it is an invasive procedure that can cause embolic stroke and second, thrombolytic agents may result in either intracranial or systemic hemorrhages.<sup>14-16</sup>

An alternative to the continuous infusion of thrombolytic is its administration in small aliquots until patency of the central retinal artery is clinically established. There are 2 theoretical advantages of this approach. First, titration of the thrombolytic agent may result in a reduction in the total dose that is administered, thus potentially reducing the risk of hemorrhage. Second, the titration approach may reduce procedural time. Given that the duration of cerebral angiography is correlated with the risk of periprocedural stroke, reduced angiography time might be expected to reduce the incidence of complications.<sup>17-19</sup>

We hypothesize that the treatment of acute CRAO with LIF administered in aliquots may achieve a better visual outcome than standard therapy alone and with a lower complication rate.

### Methods

We performed a retrospective analysis of a consecutive cohort of 42 patients admitted to the Johns Hopkins Hospital with acute CRAO from July 1999 to July 2006. All patients gave informed consent for the off-label use of tissue plasminogen activator (tPA) by intraarterial administration.

#### Ophthalmic Examination

All patients were assessed by an ophthalmologist who confirmed the diagnosis of acute CRAO using standard clinical criteria of monocular vision loss associated with an ipsilateral relative afferent pupillary defect and diffuse, pale swelling of the retina with a macular "cherry-red" spot and attenuation of retinal vessels by ophthalmoscopy.

VA at presentation was measured by Snellen chart at 20 feet for all patients whose VA in the affected eye was 20/400 or better. Patients with VA less than 20/400 in the affected eye were assessed on an ordinal categorical scale progressing from counting fingers, to hand movement, to light perception and finally to no light perception. Fluorescein angiography was performed whenever possible. Demographic details and vascular risk factors on admission were recorded.

Two therapeutic procedures were compared in this study; standard therapy alone (control group) or LIF in addition to standard therapy (LIF group). The decision for a subject to undergo LIF was made by the treating ophthalmologist and neurologist if the patient was eligible.

The inclusion criteria for LIF were: (1) time to presentation of CRAO within 15 hours of symptom onset; (2) a presumed thromboembolic cause; (3) no evidence of vasculitis by clinical assessment or laboratory studies (eg, erythrocyte sedimentation rate); and (4) no evidence of hypoperfusion of the ipsilateral internal carotid artery as a cause of CRAO documented either angiographically or with duplex ultrasonography. Exclusion criteria included uncertain time of CRAO onset, a current or previous history of systemic hemorrhage within the last 3 months, brain imaging showing evidence of intracranial hemorrhage, clinical evidence of CRAO from giant cell arteritis, or inability to obtain subject consent.

Standard therapy of CRAO included ocular paracentesis, carbogen inhalation, topical intraocular pressure-lowering agents, or a combination of these. All patients eligible for LIF underwent CT or MRI with a fluid-attenuated inversion recovery sequence to exclude cerebral hemorrhage.

A diagnostic 4-vessel angiogram was performed under local sedation to assess the intracranial vasculature with an emphasis on the patency of the ipsilateral carotid and ophthalmic arteries. All angiograms and LIFs were performed by K.M. or P.G.. LIF was

performed by advancing a guide catheter using a fluoroscopic roadmap of the internal carotid artery ipsilateral to the affected eye, after which 3000 U of heparin was infused to prevent periprocedural thrombosis. A 1018 microcatheter (Boston Scientific, Natick, Mass) steamed to the shape conforming to the ophthalmic artery siphon was then advanced to the origin of the ophthalmic artery and aliquots of 3 mg tPA, in 3 cc normal saline increments, were infused over 5 minutes each. Aliquot infusion was stopped if there was a clinical VA improvement or a prespecified maximum dose of 20 mg of tPA was reached, at which time the guiding and microcatheters were removed. All patients were admitted to an intensive care unit and partial thromboplastin time was measured every 2 hours. Once the partial thromboplastin time value had dropped below 1.5 times the normal value, an infusion of intravenous heparin was begun, without a bolus, using a weight-based nomogram. Once the therapeutic range of a partial thromboplastin time value of 1.5 to 2.5 times normal was reached, the partial thromboplastin time was checked every 6 hours. The intravenous heparin infusion was stopped after 24 hours.<sup>20</sup> All adverse events were recorded.

In both standard and LIF groups, VA was assessed on day 1 postprocedure and then daily until discharge. The final VA for all patients was obtained from the patients' ophthalmologists for the most recent follow-up and the duration of follow-up recorded.

#### Outcome Measures

The primary outcome was defined as a one-line improvement in VA on the Snellen chart for patients with initial VA of 20/400 or better at 24 hours postadmission. For patients with initial VA worse than 20/400, an improvement was considered to have occurred if VA improved from no light perception to light perception, from light perception to hand movement, from hand movement to counting fingers, and from counting fingers to 20/400 or better at 24 hours after LIF.<sup>11</sup> Secondary outcomes included improvement in VA of 3 lines or more, signifying a doubling of visual angle<sup>21</sup> and achieving a VA of 20/200 or better, signifying the US definition for legal blindness.<sup>22</sup> Any adverse effects related to LIF were recorded.

#### Statistical Methods

Statistical analyses were performed with Stata statistical software, version 9.0 (StataCorp, College Station, Texas). Univariate comparisons between baseline categorical characteristics in the 2 groups were made using Fisher exact test. Comparisons between continuous characteristics were made using a Student *t* test with adjustment for unequal variances when appropriate. Simple logistic regression was used to compare the primary outcome in the 2 groups, and multivariate stepwise logistic regression was performed including other covariates thought to be potential confounders. These variables were selected for clinical reasons or because they were found to have univariate associations with either the outcome or the use of LIF.

Although the initial analyses were performed using an automated stepwise comparison, subsequent decisions were made based on clinical importance, variables with an adjusted probability value (by likelihood ratio testing) <0.10, those that moderately changed the point estimate for the primary variable of interest (LIF group), or those variables that were believed to be clinically significant despite nonsignificant probability values and were included in the final model. Goodness of fit was assessed using the Hosmer-Lemeshow statistic. Probability values for regression analyses are reported using likelihood ratio testing results. In addition, for analysis of the primary outcome, multinomial logistic regression was performed with a 3-level outcome (worsening/no change/improvement in VA) and appropriate adjustment for potential confounders. Unless otherwise specified, an alpha <0.05 was considered to be statistically significant.

### Results

#### Demographics and Vascular Risk Factors

Twenty-one subjects with a mean age of 65.1±13 years and 56.6±15 years were in the LIF and standard treatment

**Table 1. Demographic Parameters**

	LIF Group (n=21)	Control Group (n=21)	P Value
Age, mean±SD	65.1±13	56.6±15	0.07
Gender, % male	52.4%	33.3%	0.35
Race			0.31
White, %	80.9%	61.9%	
Black, %	19.1%	33.3%	
Asian, %	0	4.8%	
Vascular risk factors at admission, %			
Hypertension	71.4%	65%	0.74
Diabetes mellitus	28.6%	23.8%	1.00
Hypercholesterolemia	28.6%	33%	1.00
Current smoker	28.6%	38.1%	0.74
Prior cerebrovascular events (either transient ischemic attack or cerebrovascular accident)	28.6%	23.8%	1.00
Coronary artery disease	19.1%	19.1%	1.00
Peripheral vascular disease	4.8%	4.8%	1.00
Mean time to presentation, mean±SD hours	3.3±2.0	25.8±20	<0.001*

\*Statistically significant at an alpha=0.05.

groups, respectively. The demographic details were comparable between the 2 groups (Table 1). The most common vascular risk factor was systemic hypertension in 71.4% and 65% of the LIF and control groups, respectively. There were no significant differences in the proportion of individual risk factors between the 2 groups. Two patients, one in each group, had ipsilateral carotid stenosis greater than 70% and underwent carotid endarterectomies subsequently.

The mean time between the onset of CRAO to presentation to an ophthalmologist or emergency room was 3.4±2.0 hours in the LIF group compared with 25.8±20 hours in the control group (95% CI: 13.5 to 31.4 hours;  $P<0.001$ ). In 76% of control subjects, time of presentation after 15 hours was the main reason for not receiving LIF. Six patients presented within 15 hours but were not given tPA. Of these, 2 patients refused LIF treatment; 2 patients had significant medical comorbidities and were deemed unsuitable for LIF; one patient had an elevated erythrocyte sedimentation rate, raising

**Table 2. Visual Acuity at Admission\***

Initial Acuity	LIF Group (n=21)	Control Group (n=21)
No light perception	4.8%	9.5%
Light perception	9.5%	23.8%
Hand movement	47.6%	19.1%
Count fingers	28.6%	28.6%
20/800	0	9.5%
20/400	9.5%	9.5%

\*Percentage distribution of subjects in each visual acuity category for the LIF and control groups. There was no statistically significant difference between the groups using Fisher exact test ( $P=0.31$ ).

**Table 3. Visual Acuity Within 24 Hours After LIF or Standard Therapy and At Final Examination**

	LIF Group (n=21)	Control Group (n=21)	P Value
Immediate vision change at 24 hours postadmission			
Visual improvement by ≥1 line	71.4%	9.5%	<0.001*
No change in vision	28.6%	71.4%	
Visual worsening by ≥1 line	0%	19.1%	
Vision change at final follow-up			
Visual improvement by ≥1 line	76.2%	33.3%	0.018*
No change in vision	19.0%	38.1%	
Visual worsening by ≥1 line	4.8%	28.6%	
Follow-up time, months±SD	15.2±15.7	11.2±13.1	

\*Statistically significant.

the clinical suspicion of giant cell arteritis. The patient underwent a temporal artery biopsy that was negative and thus is included in our analysis. Finally, one patient had an ipsilateral internal carotid artery occlusion on angiography and the microcatheter could not be passed through the occlusion for LIF. These patients all received standard therapy.

The mean time from onset of visual loss to LIF was 9.3±2.9 hours. The mean time of the LIF procedure was 96.3±28.3 minutes. The mean dose of tPA was 11.25±3.5 mg.

### Visual Outcome

VA at presentation was 20/400 or worse in all patients. There was no statistically significant difference in the distribution of VA at presentation between the 2 groups (Table 2). In the LIF group, 71.4% experienced a one line or more of improvement in VA within 24 hours after completion of LIF compared with baseline versus 9.5% in the control group ( $P<0.001$ ). At final examination, 76.2% of subjects in the LIF group had an improvement in VA of one line or more (mean follow-up, 15 months) versus 33.3% in the control group (mean follow-up time, 11 months;  $P=0.018$ ; Table 3).

Univariate logistic regression for the primary outcome showed that patients who received LIF were 6.4 times more likely to have an improvement in VA compared with the control group (95% CI: 1.65 to 24.77;  $P=0.0045$ ). Adjusted analysis (including adjustment for gender, prior history of stroke/transient ischemic attack, and history of hypercholesterolemia) yielded an OR for an effect of LIF of 36.0 (95% CI: 3.09 to 417.6;  $P=0.0001$ ; Table 4). We assessed for

**Table 4. Multivariate Logistic Regression Analysis With Adjusted OR for Visual Acuity Improvement**

Variable	OR
LIF	36.0, $P=0.0001$ *
History of elevated cholesterol	0.10, $P=0.0195$
Prior transient ischemic attack or stroke	0.11, $P=0.054$
Female gender	0.08, $P=0.025$

\*Multivariate stepwise logistic regression adjusting for gender, history of stroke/transient ischemic attack, and history of hypercholesterolemia shows that LIF is the most statistically significant factor associated with VA improvement.

interaction between use of LIF and prior conservative measures as well as between LIF and baseline acuity. No significant interaction was found (OR: 1.97,  $P=0.57$  and OR: 4.5,  $P=0.19$ , respectively).

Secondary analyses were performed using a 3-level outcome measure. The reference group was no change in visual acuity. Using the same set of covariates described in the multivariate model, subjects were 22 times more likely to experience improvement in VA and 86% less likely to experience worsening of VA if they received LIF (adjusted;  $P=0.0003$ ). In addition, a history of hypercholesterolemia impacted negatively on visual outcome, although only in the adjusted models (adjusted OR: 0.10, 95% CI: 0.012 to 0.85;  $P=0.02$ ; Table 4).

A post hoc analysis was performed using a visual acuity improvement of 3 lines or more. One third of the group receiving LIF had an improvement of VA by 3 lines or more compared with 4.8% of the standard therapy group ( $P=0.018$ ). On multilogistic regression analysis, subjects undergoing LIF had a 13 times increased likelihood of achieving a VA improvement of 3 lines or more compared with those receiving standard therapy (OR: 13, 95% CI: 1.2 to 145;  $P=0.03$ ). In addition, subjects in the LIF group were 4.9 times more likely to have a final VA of 20/200 or better (OR: 4.9, 95% CI: 1.05 to 23.4;  $P=0.04$ ).

### Complications

Two patients in the LIF group had groin hematomas that resolved without long-term sequelae. No intracerebral, intraocular, or orbital hemorrhages occurred.

### Discussion

Patients with presumed thromboembolic CRAO have a poor visual outcome with 78% having no spontaneous visual recovery.<sup>2</sup> Current standard therapies do not alter the natural history of disease, whereby 0% to 30% may have spontaneous improvement.<sup>2,6,23</sup> In contrast, case series of patients with CRAO who undergo LIF report an improvement in final VA in 40% to 74% of subjects, and retrospective, nonrandomized studies of LIF treatment in CRAO document an improvement of VA in 20% to 70% of LIF subjects.<sup>11,12,24</sup>

In our study, 71% of subjects in the LIF group had an improvement of VA within the first 24 hours and 76% at final examination. In contrast, 9.5% and 33.3% of patients in the standard therapy cohort experienced improvement in VA at 24 hours and final examination, respectively. These point estimates are in keeping with previous studies and more importantly demonstrate a significant therapeutic advantage over the proportion of subjects who have a VA improvement either spontaneously or with standard therapy alone.<sup>2,6,23</sup> This is reflected in the regression analyses in which the use of tPA was associated with a 36-fold greater likelihood of recovery of VA versus standard therapy. In addition the benefit of tPA was also found using a more stringent outcome measure of an improvement in VA of 3 lines or more.

LIF is not without potential risk. Cerebral ischemia,<sup>11,14,15</sup> intracerebral hemorrhage,<sup>16</sup> and bleeding at the site of femoral catheterization have been documented.<sup>15</sup> The hemorrhage risk is related to the dose of thrombolytic, whereas the

ischemic stroke risk may be related to the procedure duration.<sup>17-19</sup> Our study was unique in that we used a dose titration of tPA in aliquots until clinical improvement of CRAO occurred. Using this approach, the mean tPA dose of  $11.3 \pm 2.5$  mg was smaller compared with a range of 30 to 70 mg of tPA used in previous studies.<sup>11,14-16</sup> The duration of LIF of  $96.3 \pm 28.3$  minutes was within the range of procedural times of 70 to 150 minutes previously cited.<sup>11,16</sup>

An important consideration in determining the risk-benefit ratio of LIF in CRAO in regular clinical practice is the severity of adverse events. In contrast to thrombolysis in cerebral ischemia in which the rate of hemorrhage varies from 3% to 20%,<sup>8,23,26</sup> there are no reports of intraocular hemorrhage to date. The thrombolytic-related intracranial hemorrhage risk, according to the myocardial infarction literature, is 1%.<sup>10,27</sup>

The rationale for thromboembolic CRAO fibrinolysis is the assumption of a fibrinoplatelet clot composition that may be thrombolytic-responsive. Criticism of this assumption revolves around the fact that in one study of CRAO due to emboli, 57% (40 of 70) were found to be of the cholesterol type.<sup>2,28,29</sup> It is commonly thought that the site of occlusion in CRAO is at the level of the lamina cribrosa and as such is not visible on funduscopic examination.<sup>7,30</sup> The study by Arruga et al<sup>28</sup> demonstrating the high proportion of patients with cholesterol emboli was a study of visible emboli and does not necessarily reflect the distribution of emboli types in CRAO and thus does not invalidate the use of thrombolysis.

In internal carotid occlusion primate models of ischemic stroke, relief of the occlusion results in recovery of cortical action potentials by salvaging cells in the ischemic penumbra.<sup>31</sup> Similarly, reperfusion after occlusion of blood flow in CRAO primate models also results in restoration of retinal and visual evoked potentials.<sup>32,33</sup> These findings, and the observation in permanent CRAO of the presence of a sluggish retinal circulation on fluorescein angiography, suggests the presence of collateral blood supply and a retinal penumbra.<sup>2,29</sup> Reperfusion of this retinal penumbra could explain the marked VA improvement after LIF.

A potential limitation of this study is its nonrandomized nature that is subject to selection bias. In our study, the time to presentation was much shorter in the LIF group as compared with the standard therapy group. The fact that subjects arriving earlier were selected for LIF reperfusion therapy, compared with those who arrived later and were treated with standard therapy, could skew the results in favor of thrombolysis. Nevertheless, the point estimate of the efficacy of thrombolysis corresponds with previous studies and is above that of the rate of spontaneous recovery in CRAO.

Another limitation is the lack of fluorescein angiography and visual field assessment in all patients, making it impossible to subclassify our subjects with the same degree of detail as previous studies.<sup>2</sup> Although it is possible that the apparent efficacy of LIF in our study reflects the spontaneous recovery rate described in transient CRAO, transient CRAO comprise approximately 16% of all CRAOs.<sup>2</sup> We believe that the probability that we enrolled consecutive transient CRAO subjects in our LIF group is low and our sample likely reflect

the majority of CRAO cases that are thromboembolic in origin.

### Conclusion

Our results support the hypothesis that the treatment of acute thromboembolic CRAOs with LIF administered in aliquots results in a better visual outcome than standard therapy alone and has few complications. It is a biologically plausible therapy modeled on the treatment of similar conditions such as stroke and myocardial infarction. Nevertheless, because of the nonrandomized nature of this and previous studies LIF use cannot be recommended as standard therapy in daily clinical practice pending the publication of randomized clinical trials.<sup>34</sup> Such a trial is already underway in Europe, and a further trial in North America may be warranted in light of these findings.

### Disclosures

None.

### References

- Rumelt S, Dorenboim Y, Rehany U. Aggressive systematic treatment for central retinal artery occlusion. *Am J Ophthalmol*. 1999;128:733-738.
- Hayreh SS, Zimmerman MB. Central retinal artery occlusion: visual outcome. *Am J Ophthalmol*. 2005;140:e371-e376.
- Chia EM, Mitchell P, Rohtachina E, Foran S, Wang JJ. Unilateral visual impairment and health related quality of life: the Blue Mountains Eye Study. *Br J Ophthalmol*. 2003;87:392-395.
- Vu HTV, Keeffe JE, McCarty CA, Taylor HR. Impact of unilateral and bilateral vision loss on quality of life. *Br J Ophthalmol*. 2005;89:360-363.
- Duker JS. Retinal artery obstruction. In: Yanoff M, Duker JS, Augsburger JJ, eds. *Ophthalmology*. St Louis: Mosby; 2004.
- Atebara NH, Carter GC, Carter J. Efficacy of anterior chamber paracentesis and carbogen in treating acute nonarteritic central retinal artery occlusion. *Ophthalmology*. 1995;102:2029-2035.
- Karjalainen K. Occlusion of the central retinal artery and retinal branch arterioles. *Acta Ophthalmol*. 1971;109(suppl):1-96.
- NINDS. Tissue plasminogen activator for acute ischemic stroke. *N Engl J Med*. 1995;333:1581-1588.
- Furlan A, Higashida R, Wechsler L, Gent M, Rowley H, Kase C, Pessin M, Ahuja A, Callahan F, Clark WM, Silver F, Rivera F. Intra-arterial prourokinase for acute ischemic stroke: the PROACT II study: a randomized controlled trial. *Prolyse in Acute Cerebral Thromboembolism*. *JAMA*. 1999;282:2003-2011.
- Waters HRE, Mahaffey KW, Granger CB, Roe MT. Current perspectives on reperfusion therapy for acute ST-segment elevation myocardial infarction: integrating pharmacologic and mechanical reperfusion strategies. *Am Heart J*. 2003;146:958-968.
- Schmidt DP, Schulte-Monting J, Schumacher M. Prognosis of central retinal artery occlusion: local intraarterial fibrinolysis versus conservative treatment. *AJNR Am J Neuroradiol*. 2002;23:1301-1307.
- Arnold M, Koerner U, Remonda L, Nedelchev K, Mattle HP, Schöth G, Sturzenegger M, Weber J, Koerner F. Comparison of intra-arterial thrombolysis with conventional treatment in patients with acute central retinal artery occlusion. *J Neurol Neurosurg Psychiatry*. 2005;76:196-199.
- Beatty S, Au-Eong KG. Local intra-arterial fibrinolysis for acute occlusion of the central retinal artery: a meta-analysis of the published data. *Br J Ophthalmol*. 2000;84:914-916.
- Richard G, Lerche RC, Knosp V, Zeumer H. Treatment of retinal arterial occlusion with local fibrinolysis using recombinant tissue plasminogen activator. *Ophthalmology*. 1999;106:768-773.
- Schumacher M, Schmidt D, Wakhloo AK. Intra-arterial fibrinolytic therapy in central retinal artery occlusion. *Neuroradiology*. 1999;35:600-605.
- Butz B, Strotzer M, Manke C, Roeder J, Link J, Lenhart M. Selective intraarterial fibrinolysis of acute central retinal artery occlusion. *Acta Radiol*. 2003;44:680-684.
- Willinsky RA, Taylor SM, terBrugge K, Farb RI, Tomlinson G, Montaner W. Neurologic complications of cerebral angiography: prospective analysis of 2,899 procedures and review of the literature. *Radioogy*. 2003;227:522-528.
- Leffers A, Wagner A. Neurologic complications of cerebral angiography: a retrospective study of complication rate and patient risk factors. *Acta Radiol*. 2000;41:204-210.
- Heiserman JE, Dean BL, Hodak JA, Flom RA, Bird CR, Drayer BP, fram EK. Neurologic complications of cerebral angiography. *AJNR Am J Neuroradiol*. 1994;15:1401-1407.
- del Zoppo GJ, Higashida RT, Furlan AJ, Pessin MS, Rowley HA, Gent M. PROACT: a phase II randomized trial of recombinant pro-urokinase by direct arterial delivery in acute middle cerebral artery stroke. *Stroke*. 1998;29:4-11.
- Rosser D, Cousens S, Murdoch I, Fitzke F, Laidlaw D. How sensitive to clinical changes are ETDRS logMAR visual acuity measurements? *Invest Ophthalmol Vis Sci*. 2003;44:3278-3281.
- The Eye-Diseases-Prevalence-Research-Group. Causes and prevalence of visual impairment among adults in the United States. *Arch Ophthalmol*. 2004;122:477-485.
- Mueller AJ, Neubauer AS, Schaller U, Kampik A. Evaluation of minimally invasive therapies and rationale for a prospective randomized trial to evaluate selective intra-arterial lysis for clinically complete central retinal artery occlusion. *Arch Ophthalmol*. 2003;121:1377-1381.
- Weber J, Remonda L, Mattle HP, Koerner U, Baumgartner RW, Sturzenegger M, Ozdoba C, Schroth G. Selective intra-arterial fibrinolysis of acute central retinal artery occlusion. *Stroke*. 1998;29:2076-2079.
- Kohrmann M, Jutler E, Fiebich JB, Huttner HB, Siebert S, Schwari C, Ringleb PA, Schellinger PD, Hacke W. MRI versus CT-based thrombolysis treatment within and beyond the 3 h time window after stroke onset: a cohort study. *Lancet Neurol*. 2006;5:661-667.
- Albers G, Thijis VN, Wechsler L, Kemp S, Schlaug G, Skalabría E, Bammer R, Kakuda W, Lansberg MG, Shuaib A, Coplin W, Hamilton S, Moseley M, Marks MP. Magnetic resonance imaging profiles predict clinical response to early reperfusion: the diffusion and perfusion imaging evaluation for understanding stroke (DEFUSE) study. *Ann Neurol*. 2006;60:508-517.
- GUSTO. An international randomized trial comparing four thrombolytic strategies for acute myocardial infarction. *N Engl J Med*. 1993;329:673-682.
- Arruga J, Sanders MD. Ophthalmic findings in 70 patients with evidence of retinal embolism. *Ophthalmology*. 1982;89:1336-1337.
- Hayreh SS. Prevalent misconceptions about acute retinal vascular occlusive disorders. *Prog Ret Eye Res*. 2005;24:493-419.
- Hayreh SS, Dass R. The central artery of the retina I. Origin and course. *Br J Ophthalmol*. 1960;44:193-212.
- Astrup J, Symon L, Branston NM, Lassen NA. Cortical evoked potential and extracellular K<sup>+</sup> and H<sup>+</sup> levels at critical levels of brain ischemia. *Stroke*. 1977;8:51-57.
- Hayreh SS, Kolder HE, Weingeist TA. Central retinal artery occlusion and retinal tolerance time. *Ophthalmology*. 1980;87:75-78.
- Hayreh SS, Zimmerman MB, Kimura A, Sanon A. Central retinal artery occlusion. Retinal survival time. *Exp Eye Res*. 2004;78:723-736.
- Feltgen N, Neubauer A, Jurklics B, Schmoor C, Schmidt D, Wanke J, Maier-Lenz H, Schumacher M. Multicenter study of the European Assessment Group for Lysis in the Eye (EAGLE) for the treatment of central retinal artery occlusion: design issues and implications. EAGLE study report no 1. *Graefes Arch Clin Exp Ophthalmol*. 2006;44:950-956.

## Central retinal artery occlusion: timing and mode of presentation

A. K Rudkin<sup>b</sup>, A. W. Lee<sup>a</sup> and C. S. Chen<sup>b</sup>

<sup>a</sup>Departments of Stroke Neurology, and <sup>b</sup>Department of Ophthalmology, NH&MRC Centre of Clinical Eye Research, Flinders Medical Centre and Flinders University, Bedford Park, SA, Australia

### Keywords:

central retinal artery occlusion, inclusion criteria, thrombolysis, timing

Received 21 November 2008

Accepted 18 February 2009

**Background and purpose:** Central retinal artery occlusion (CRAO) is a sudden, frequently irreversible, monocular vision loss, analogous to acute cerebral ischaemia. Thrombolysis may improve visual outcomes, but it is unclear what the acceptable timing of administration should be. We aim to ascertain, through audit, the timing and mode of presentation of individuals with potentially thrombolysable CRAOs.

**Methods:** A retrospective audit of patients with acute thromboembolic CRAO.

**Results:** Thirty-one patients were identified. Mean time from onset of vision loss to presentation was  $31 \pm 65$  h. Eighteen patients (58%) presented within 20 h of vision loss, and the majority presented first to a general practitioner. Fifteen patients (48%) were reviewed by an in-hospital ophthalmologist within 20 h of vision loss. The mean delay from the referring source to assessment by an in-hospital ophthalmologist was 5.2 h (median 3.3 h, range 50 min to 24 h). This delay was, on average, shorter for patients referred directly to an ophthalmology clinic.

**Conclusions:** Just under half (48%) of our cohort of CRAO patients were reviewed by an in-hospital ophthalmologist within the 20-h therapeutic time window for thrombolytic therapy and thus could qualify for inclusion in a randomized controlled trial according to EAGLE inclusion criteria. If thrombolysis is proven to be a feasible and safe treatment in CRAO then public awareness should be raised of the symptoms and an efficient direct referral pathway to an in-hospital ophthalmologist established to aid treatment delivery.

### Introduction

Central retinal artery occlusion (CRAO) is an acute occlusion of the central retinal artery (CRA) resulting in acute, painless monocular visual loss and is analogous to an ischaemic cerebral stroke. Spontaneous recovery rates are poor, with <10% of all patients reporting a significant recovery of visual acuity (VA) [1,2]. Like cerebral ischaemia, CRAO is caused by thrombi or emboli consisting of platelet fibrin material [3]. A number of recommended therapies for thromboembolic CRAO have been used in daily clinical practice, but a recent Cochrane meta-analysis found that they did not improve visual outcomes beyond the natural course of disease [4].

Thrombolysis using tissue plasminogen activator (tPA) has been licensed for the treatment of acute cerebral ischaemia in a number of countries based on two pivotal randomized controlled trials of efficacy

[5,6], supported by an ongoing prospective multi centre registry of effectiveness [7,8]. There is evidence that tPA could also be used in the treatment of CRAO [9]. The main barrier to implementation is the absence of a randomized controlled trial confirming efficacy and the fact that most publications have centered around the intra-arterial delivery of thrombolytics [9].

It is an accepted principle that the earlier reperfusion occurs in an ischaemic end organ the better the prognosis. In ischaemic stroke, the shorter the delay between symptom onset and the administration of thrombolytic, the better the prognosis and the less chance there is of developing a symptomatic intracranial hemorrhage. Whilst the time window for tPA use in ischaemic stroke is well defined, tPA for CRAO has been deployed up to 24 h of symptom onset. The European Assessment Group for Lysis in the Eye (EAGLE) study has a time window of 20 h for intra-arterial tPA use [10]. One of the limitations in conducting a randomized controlled trial of tPA in CRAO is its low incidence of one in 10 000 ophthalmic outpatient visits [11]. In planning such a study, it would be important to determine the proportion of individuals with CRAO who would present within an acceptable study time window to

Correspondence: Dr Celia Chen, Department of Ophthalmology, NH&MRC Centre of Clinical Eye Research, Flinders Medical Centre and Flinders University, Flinders Drive, Bedford Park, SA 5042, Australia (tel.: +61 8 82044899; fax: +61 8 82770899; e-mail: celia.chen@health.sa.gov.au).

receive tPA and also to characterize potential causes of delayed presentation.

In this paper, we present an audit on the presentation of individuals with potentially thrombolysable CRAOs to our hospital. Specifically, we describe the time to presentation, mode of presentation and aim to identify possible causes of delay.

## Methods

A retrospective audit of all patients diagnosed with acute CRAO referred to the ophthalmology department at the Flinders Medical Centre between January 1997 and July 2008.

All patients had CRAO confirmed clinically by an ophthalmologist. Patients with arteritic CRAO were excluded from the study using standard clinical criteria and investigations such as inflammatory markers and tissue pathology. Five patients in whom there was clinical and/or biochemical suspicion of giant cell arteritis underwent temporal artery biopsies, all of which were negative.

Data collected included age, gender, time of symptom onset, time to presentation, type of health provider at presentation (general practitioner, emergency department, optometrist or ophthalmologist) and the time interval between symptom onset and in-hospital ophthalmologist review. Continuous variables are presented as a mean  $\pm$  standard deviation (SD).

## Results

Thirty-one patients were identified with acute loss of vision from CRAO. Their mean age was  $73 \pm 9.5$  years. The mean time from loss of vision to initial presentation to a health care provider was  $31 \pm 65$  h (median 17, range 1.5–360 h). The timing and initial health care provider are detailed in Table 1.

Eighteen patients (58%) presented within 20 h of vision loss, of which the nine of the 18 (50%) were first assessed by a general practitioner (GP).

Three patients presented directly to an in-hospital ophthalmology clinic. Of the remaining 28 patients who were seen by a health care provider who is not an in-hospital ophthalmologist, the referral pattern showed that 23 of the 28 were referred urgently within 24 h (Table 2). Analysis of the five patients who were referred non-urgently showed that four were from an ophthalmologist in private practice outside a teaching hospital and one from a general practitioner in a non-metropolitan region. The four patients from the ophthalmologists in private practice presented three or more days after the onset of symptoms. The patient from the non-metropolitan area was seen by an in-hospital ophthalmologist 1 day after presentation due to transport reason.

Of the total study cohort, 15 (48%) reached an in-hospital ophthalmologist within 20 h of symptom onset. The mean delay for urgent referral on the same day ( $n = 23$ ) from presentation to a health care provider until review by an in-hospital ophthalmologist was  $5.2 \pm 2.8$  h (median 3.3 h, range 50 min to 24 h).

**Table 1** Timing and mode of presentation of patients with CRAO

Initial health care provider	Number of patients	Mean time from onset of vision loss to health provider consultation (hours $\pm$ SD)	Number presenting within 20 h of vision loss (%)
General practitioner	12	$13.4 \pm 10.7$	9 (75)
Emergency department	8	$13.1 \pm 11.9$	5 (63)
Ophthalmologist	10	$71.0 \pm 111.0$	4 (40)
Optometrist	1	24.0	0 (0)
Total	31	$31.2 \pm 65$	18 (58)

CRAO, central retinal artery occlusion; SD, standard deviation.

**Table 2** Analysis of referral pattern and referral detail to the in-hospital ophthalmologist from the initial health care provider

Initial Health Care Provider	Number of patients	Referred urgently within 24 h	Number referred urgently who were within 20 h of symptom onset	Number of patients seen within 20 h of symptom onset by an in-hospital ophthalmologist	Mean delay in those referred urgently from the initial provider to in-hospital ophthalmologist (hours $\pm$ SD)
General practitioner	12	11	9	6	$4.9 \pm 6.3$
Emergency department	8	8	5	5	$5.3 \pm 7.7$
In hospital ophthalmologist	3	N/A	2	2	N/A
Private practice ophthalmologists	7	3	2	2	$7.3 \pm 13.6$
Optometrist	1	1	0	0	$4.0 \pm 0$
Total	31	23	18	15	$5.2 \pm 2.8$

N/A, not applicable; SD, standard deviation.

Of the 11 patients seen by a general practitioner who were referred urgently on the same day, three cases were referred directly to the in-hospital ophthalmologist. The mean delay in this group was shorter at  $2.4 \pm 2.4$  h (median 1.3 h, range 1.0–6.0 h). The rest were sent to the emergency department where they were then directed to the ophthalmology department.

## Discussion

Just under half (15/31, 48%) of our cohort of CRAO patients were reviewed by a hospital ophthalmologist within 20 h of symptom onset and, therefore, could qualify for a thrombolysis trial based on time of symptom onset alone according to EAGLE inclusion criteria [10]. CRAO patients were on the whole either seen by a general practitioner or an ophthalmologist as their first health practitioner and a large proportion of these could qualify for thrombolysis based on a 20 h time window.

Time to intervention in CRAO is crucial. In animal models of complete occlusion of the retinal artery, complete recovery occurs if the occlusion is reversed within 97–100 min [12]. *In vivo* fluorescein angiography in humans suggest that occlusion of the central retinal artery is either subtotal with some residual delayed flow from the incompletely occluded central retinal artery assisted by choroidal collaterals [13]. The presence of residual retinal tissue perfusion may be the mechanism, whereby observational studies of thrombolysis suggest benefit even after 24 h of visual loss [13,14].

The John Hopkins Hospital study excluded CRAO patients who presented > 15 h after visual loss [15]. Seventy-six percent of patients receiving intra-arterial thrombolysis ( $n = 21$ ) compared with 33% of patients receiving standard therapy ( $n = 21$ ) had a VA improvement of one or more lines on a Snellen chart ( $P = 0.018$ ). A retrospective case series performed by Richard *et al.* [14] investigated 53 patients (46 with CRAO and seven patients with branch retinal artery occlusion) who were treated with intra-arterial thrombolysis. The mean time to treatment was  $14 \pm 1$  h. In 66% of patients, vision improved by at least one line on a Snellen chart. Schmidt *et al.* [13] did not have exclusion criteria in their retrospective cohort study; however, the mean time to treatment for patients receiving intra-arterial thrombolysis was  $10.8 \pm 9.5$  h and 58% of patients receiving thrombolysis demonstrated improvement in VA, compared with 29% in the control group ( $P = 0.002$ ). Subgroup analysis demonstrated that both the frequency and the extent of visual recovery was greater in patients that received thrombolysis within 6 h, but noted that visual improvement

was still observed in patients receiving treatment more than 14 h after visual loss.

A number of important aspects were observed in this audit. First, the majority of referrals came from GP. One possible reason for this is the relative ease of obtaining an appointment in a GP clinic compared with an appointment in an ophthalmology clinic. In this study, only three patients (9.6%) were seen by an in-hospital ophthalmologist. In comparison with the study by Schmidt *et al.* [16], 76.7% of retinal artery occlusions were seen within 24 h in a university teaching hospital ophthalmology eye department. This probably reflects a difference in the structure of the health care system between countries as well as the difference in the infra-structure that has occurred in education of the patients. If thrombolysis is proven to be a feasible and safe treatment in CRAO then public awareness should be raised of the symptoms and presentation to aid treatment delivery in the same way that public education for symptom recognition of heart attacks and acute stroke has increased the efficiency of reperfusion therapy delivery.

The second important aspect of this study is that patients were assessed more quickly when they were referred directly to the in-hospital ophthalmologist compared with those who were referred to the emergency department first and then re-directed to the ophthalmology department. This issue of the rapid transfer of care to the end-organ specialist responsible for reperfusion therapy has been emphasized repeatedly in stroke literature and often requires structural re-organization for rapid tPA delivery [17]. Such re-organization mandates the use of pre-hospital assessment tools for the rapid identification of stroke patients that would qualify for thrombolysis and couples this with the activation of a stroke-response team according to a set protocol [18]. For thrombolysis in CRAO to work be it in standard clinical practice or a study situation, a similar set of protocols needs to be designed, or incorporated on to the existing framework for thrombolysis in cerebral ischaemia.

## Conclusion

Central retinal artery occlusion is an ocular emergency with no known effective therapies at present. Thrombolytic therapy with tPA shows promise, but requires confirmation in a randomized control trial where a short-time interval between symptom onset and treatment is crucial. This current audit demonstrates that just under 50% of CRAO patients were reviewed by a hospital ophthalmologist within the 20-h time window for thrombolytic therapy and thus could qualify for inclusion in such a study. If thrombolysis is proven to be a feasible and safe treatment in CRAO then public

awareness should be raised of the symptoms and presentation to aid treatment delivery. An efficient way to prevent delays in therapy need to be established such as with direct referral to the ophthalmology department by the initial health care provider and for CRAO to be added on to existing stroke thrombolysis protocols; this emphasizes the importance of the collaboration between vascular neurology and ophthalmology for such a randomized controlled trial to occur.

## References

1. Atebara NH, Carter GC, Cater J. Efficacy of anterior chamber paracentesis and carbogen in treating acute nonarteritic central retinal artery occlusion. *Ophthalmology* 1995; **102**: 2029–2035.
2. Mueller AJ, Neubauer AS, Schaller U, Kampik A. Evaluation of minimally invasive therapies and rationale for a prospective randomized trial to evaluate selective intra-arterial lysis for clinically complete central retinal artery occlusion. *Arch Ophthalmol* 2003; **121**: 1377–1381.
3. Duker JS. Retinal artery obstruction. In: Yanoff M, Duker JS, Augsburger JJ eds. *Ophthalmology*. 2nd edn. St Louis, MO: Mosby, 2004; 854–861.
4. Fraser S, S D. Interventions for acute non-arteritic central retinal artery occlusion. *Cochrane Database Syst Rev*. 2002 **1**: CD001989.
5. NINDS. Tissue plasminogen activator for acute ischemic stroke. *N Engl J Med* 1995; **333**: 1581–1588.
6. Hacke W, Kaste M, Bluhmki E, et al. Thrombolysis with alteplase 3 to 4.5 hours after acute ischemic stroke. *N Engl J Med* 2008; **359**: 1317–1329.
7. Wahlgren N, Ahmed N, Davalos A, et al. Thrombolysis with alteplase for acute ischaemic stroke in the Safe Implementation of Thrombolysis in Stroke-Monitoring Study (SITS-MOST): an observational study. *The Lancet* 2007; **369**: 275–282.
8. Wahlgren N, Ahmed N, Davalos A, et al. Thrombolysis with alteplase 3–4.5 h after acute ischaemic stroke (SITS-ISTR): an observational study. *The Lancet* 2008; **372**: 1303–1309.
9. Biousse V, Calvetti O, Bruce BB, Newman NJ. Thrombolysis for central retinal artery occlusion. *J Neuroophthalmol* 2007; **27**: 215–230.
10. Feltgen N, Neubauer A, Jurklics B, et al. Multicenter study of the European Assessment Group for Lysis in the Eye (EAGLE) for the treatment of central retinal artery occlusion; design issues and implications. EAGLE study report no. 1. *Graefes Arch Clin Exp Ophthalmol* 2006; **244**: 950–956.
11. Rumelt S, Dorenboim Y, Rehany U. Aggressive systematic treatment for central retinal artery occlusion. *Am J Ophthalmol* 1999; **128**: 733–738.
12. Hayreh SS, Kolder HE, Weingeist TA. Central retinal artery occlusion and retinal tolerance time. *Ophthalmology* 1980; **87**: 75–78.
13. Schmidt DP, Schulte-Monting J, Schumacher M. Prognosis of central retinal artery occlusion: local intraarterial fibrinolysis versus conservative treatment. *AJNR Am J Neuroradiol* 2002; **23**: 1301–1307.
14. Richard G, Lerche RC, Knosp V, Zeumer H. Treatment of retinal arterial occlusion with local fibrinolysis using recombinant tissue plasminogen activator. *Ophthalmology* 1999; **106**: 768–773.
15. Aldrich EM, Lee AW, Chen CS, et al. Local intraarterial fibrinolysis administered in aliquots for the treatment of central retinal artery occlusion: the Johns Hopkins hospital experience. *Stroke* 2008; **39**: 1746–1750.
16. Schmidt D, Schumacher M, Feltgen N. Circadian incidence of non-inflammatory retinal artery occlusion. *Graefes Arch Clin Exp Ophthalmol*. 2008 Nov 7. 2009; **247**: 491–494.
17. Alberts MJ, Latchaw RE, Selman WR, et al. Recommendations for comprehensive stroke centers: a consensus statement from the brain attack coalition. *Stroke* 2005; **36**: 1597–1616.
18. Schwamm LH, Pancioli A, Acker JE III, et al. Recommendations for the establishment of stroke systems of care: recommendations from the American Stroke Association's Task Force on the Development of Stroke Systems. *Stroke* 2005; **36**: 690–703.



Appendix 7 : Publication “Chen CS, Lee AW, Campbell B, Lee T, Paine M, Fraser C, Grigg J, Markus R, Williams KA, Coster DJ. Study of the efficacy of intravenous tissue plasminogen activator in central retinal artery occlusion. International Journal of Stroke“ In press. Scheduled for publication February 2011.

## Protocols

### Study of the efficacy of intravenous tissue plasminogen activator in central retinal artery occlusion

Celia S. Chen<sup>1\*</sup>, Andrew W. Lee<sup>2</sup>, Bruce Campbell<sup>3</sup>, Mark Paine<sup>4</sup>, Tien Lee<sup>1</sup>, Clare Fraser<sup>5</sup>, John Grigg<sup>5</sup>, Romesh Markus<sup>6</sup>, Keryn Williams<sup>1</sup>, and Doug J. Coster<sup>1</sup>

**Rationale** Central retinal artery occlusion is a stroke of the eye caused by a blockage of its main blood supply by platelet-fibrin clot. Systemic thrombolysis has been successful in restoring perfusion to ischaemic tissue by fibrin-platelet clot lysis in ischaemic stroke and myocardial infarction. Several open-label studies have demonstrated efficacy of thrombolysis in the treatment of central retinal artery occlusion, with up to 60–70% of treated subjects experiencing an improvement in visual acuity. Most of these are given intraarterially, which is an invasive procedure and not widely applicable to all treatment centres. An alternative is the intravenous infusion of tissue plasminogen activator using existing stroke thrombolysis protocols. A systematic review of all observational studies of intravenous tissue plasminogen activator in acute central retinal artery occlusion showed that 48.5% of subjects had a four line or more visual acuity improvement with an acceptable rate of haemorrhagic complications, creating the equipoise necessary to conduct a randomised controlled trial.

**Aim** To determine the efficacy of intravenous tissue plasminogen activator in acute treatment of central retinal artery occlusion.

**Design** A phase II, placebo-controlled, double-blind, randomised controlled trial comparing intravenous tissue plasminogen activator at 0.9 mg/kg to placebo (normal saline) 100 ml in a 1 : 1 block randomisation.

**Study outcome** The primary outcome measure is an improvement of three lines or more on the Snellen visual acuity chart, which signifies a doubling of the visual angle.

**Key words:** central retinal artery occlusion, outcome, reperfusion, thrombolysis, visual acuity

#### Introduction

Central retinal artery occlusion (CRAO) is an acute stroke of the eye, most commonly caused by an embolus or thrombus occluding the central retinal artery. This results in acute visual loss, occurring at a rate of 1 per 10 000 ophthalmology outpatient visits (1). The visual prognosis of CRAO is poor with 61% of patients having a final visual acuity (VA) of 6/120 or worse (2).

In acute CRAO, standard therapies include ocular massage, paracentesis, inhalation of a mixture of 95% oxygen and 5% carbon dioxide (carbogen) and other methods of reducing intraocular pressure. These treatments have not been shown to improve VA beyond the natural history of disease (3–5).

Systemic thrombolysis has been successful in restoring perfusion to ischaemic tissue by fibrin-platelet clot lysis in ischaemic stroke and myocardial infarction (6–8). In several open-label studies, local intraarterial thrombolysis using catheter angiography was efficacious in the treatment of CRAO, with up to 60–70% of treated subjects experiencing an improvement in VA (9–13). From a clinical standpoint, the intraarterial administration of thrombolytic would limit its availability to subjects presenting to hospitals that have highly specialised interventional neuroradiology services. Furthermore, angiography is an invasive procedure that can occasionally cause embolic stroke. Therefore, a more accessible route of thrombolytic administration needs to be examined.

Kattah *et al.* (14) investigated the efficacy of intravenous administration in a single-arm interventional study of tissue plasminogen activator (tPA) in acute CRAO. They found a favourable visual improvement of at least two lines on the Snellen chart in 10/12 patients, four of these having an eight-line improvement. There were no systemic or neurological complications from thrombolysis in this small sample. A systematic review of all observational studies of intravenous tPA in acute CRAO showed that 48.5% of subjects had a four lines or more VA improvement with less complication rate compared with intraarterial administration, giving the equipoise to conduct a randomised controlled trial (RCT).

Intravenous administration of thrombolytics is more expeditious and less invasive. The most feared adverse effect is either systemic or intracerebral haemorrhage. The expected risk of

Correspondence: Dr Celia Chen\*, Department of Ophthalmology, Flinders Medical Centre and Flinders University, Flinders Drive, Bedford Park, SA 5042 Australia.

E-mail: celia.chen@health.sa.gov.au

<sup>1</sup>Department of Ophthalmology, Flinders Medical Centre and Flinders University, Bedford Park, SA, Australia

<sup>2</sup>Flinders Comprehensive Stroke Centre, Flinders Medical Centre and Flinders University, Bedford Park, SA, Australia

<sup>3</sup>Department of Neurology, Royal Melbourne Hospital, University of Melbourne, Parkville, Vic. Australia, Australia

<sup>4</sup>Royal Victorian Eye and Ear Hospital, St. Vincent's Hospital, Melbourne, Vic., Australia

<sup>5</sup>Sydney Eye Hospital, The University of Sydney, NSW, Australia

<sup>6</sup>Stroke Unit, St Vincent's Hospital, Darlinghurst, NSW, Australia

Conflicts of Interest: None declared.

DOI: 10.1111/j.1747-4949.2010.00545.x

© 2011 The Authors.

International Journal of Stroke © 2011 World Stroke Organization Vol ■■, February 2011, 1–3

haemorrhage should be similar to that encountered in coronary artery or peripheral vascular thrombolysis given that brain tissue is assumed to be normal as the simultaneous occurrence of CRAO and brain ischaemia is rarely reported. Thus, the risk of intracerebral haemorrhage is 0.3% (95% CI 0.2–0.4) based on the more than 6000 patients in the GISSI-2 trial who received systemic tPA in myocardial infarction (15, 16).

The potential time window for thrombolysis in CRAO is debated and thought to be longer than that for the treatment of ischaemic stroke where tPA is approved by the Federal Drug Administration for use within 3 h of symptom onset (6). In primate models of CRAO (17), reversing CRA ischaemia within 97 min achieved complete recovery of visual evoked potentials (VEP) and reversal of CRA ischaemia within 240 min resulted in partial recovery of VEP. In most retrospective interventional case series, clinical improvement with tPA has been observed up to 12 h after onset of retinal ischaemia (9–14). Recently, Aldrich *et al.* (18) reported a prospective nonrandomised case series of intraarterial tPA use in CRAO up to 15 h from the onset of CRAO and 75% of tPA patients had VA improvement. There were no cases of haemorrhage, locally or systemically among the 42 patients. Multivariate logistic regression analysis adjusting for time from symptom onset and vascular risk factor found that the use of tPA was the single largest variate associated with VA improvement (OR = 36, 95% CI 3.09–417.6;  $P = 0.0001$ ). The European Assessment Group for Lysis in the Eye study was designed in 2006 as a prospective randomised trial to assess the efficacy of intraarterial thrombolysis in Europe and was recruiting patients within 20 h of onset of acute CRAO (19); the study has terminated recruitment and the results of the study are not yet published. This time frame would increase the applicability of the use of thrombolysis in CRAO.

We hypothesise that intravenous tPA given within 24 h of onset of CRAO will improve visual recovery compared with placebo as assessed by VA and visual fields. We, therefore, have designed and registered an open label, RCT to study the efficacy of intravenous tPA in CRAO (<http://www.ANZCTR.org.au/ACTRN12608000441314.aspx>).

To our knowledge, this is the first RCT of intravenous tPA in CRAO and stands to contribute significantly to the knowledge of treatment of this important condition.

## Methods

### Design

An open label, phase II, proof-of-concept placebo-controlled, randomised trial of intravenous tPA in the treatment of CRAO.

### Patient population – inclusion and exclusion criteria

#### *Inclusion criteria:*

- Age  $\geq 18$
- Acute CRAO within 24 h of onset of symptoms (19) (i.e. within 24 h of last known time with normal vision)
- A presumed thromboembolic cause

- No evidence of temporal arteritis by clinical assessment or laboratory studies (e.g. erythrocyte sedimentation rate)
- Noncontrast CT brain demonstrating no acute intracranial haemorrhage, infarction or mass lesion, and
- CT angiography demonstrating no ipsilateral carotid artery occlusion

#### *Exclusion criteria:*

- A history of intracerebral haemorrhage at any stage
- A history of ischaemic stroke within the last 3-months
- A history of systemic haemorrhage within the last 3-months
- Inability to obtain informed consent
- Pregnancy, and
- Clinical, biochemical or imaging predictors of an increased risk of intracerebral haemorrhage including (20)(21):
  - Major surgery or trauma within 2-weeks
  - Gastrointestinal or urinary bleeding within 3-weeks
  - Arterial puncture or lumbar puncture within 7-days.
  - A platelet count of  $< 100$
  - Heparin administered within the last 48 h or vitamin K antagonist with an INR of  $> 1.6$
  - Systolic blood pressure of  $> 185$  and diastolic blood pressure of  $> 110$
  - Serum glucose  $> 22$  mmol/l

### Randomisation

Treatment will be randomised 1:1 in a block design via a website run by the coordinating centre at Flinders Medical Centre, Adelaide. A concealed printout of treatment allocation will be passed to the administering nurse instructing the dose of tPA or placebo to be prepared. This will allow the stroke team to ensure that the patient and assessing doctors remain blinded to treatment allocation to avoid bias.

### Treatment or intervention

Alteplase will be administered intravenously according to the standard stroke unit protocol of 0.9 mg/kg (max 90 mg) with 10% bolus given over 1–2 min, followed by 90% infusion over 1 h. No antiplatelet or anticoagulants will be given for 24 h after tPA. Blood pressure will be actively managed if it is elevated above 185/110 mmHg as per local stroke unit protocols.

Clinical data will be collected including age, gender, vascular risk factors, medication list, VA at presentation, ophthalmological and neurological findings, time from onset of symptoms to presentation, treatment received and visual outcomes. These data will be entered via a secure website and the deidentified data will be transferred to the study coordinator in Adelaide.

Patients will be admitted to a Stroke Unit and receive standard investigations and management to address vascular risk factors. Participants will be examined by an ophthalmologist blinded to treatment allocation on day one to document the VA and may receive a repeat visual field and fluorescein angiography before discharge from the Stroke Unit. All participants will be followed up clinically and with computerised visual field assessment at 1-month, 3-months and 6-

